

Available online at www.sciencedirect.com

ScienceDirect

journal homepage: www.elsevier.com/locate/radcr

Case Report

A rare case of myofibroblastoma in an older male [☆]

Anna E. Osment, BA, Charles Roethling, BA, Sheryl G. Jordan, MD, Cherie M. Kuzmiak, DO, FACR, FSBI^{*}

University of North Carolina School of Medicine, 321 South Columbia Street, Chapel Hill, NC 27599, USA

ARTICLE INFO

Article history:

Received 18 July 2022

Revised 19 August 2022

Accepted 23 August 2022

Keywords:

Myofibroblastoma

Male

Breast mass

Mesenchymal tumor

Mammography

ABSTRACT

Myofibroblastoma is a rare benign breast stromal tumor comprised of fibroblasts and myofibroblasts, most commonly presenting in postmenopausal women and older men. This report discusses the case of a 69-year-old male diagnosed with myofibroblastoma after mammography, targeted ultrasound, and core needle biopsy of a retroareolar mass. The features of myofibroblastoma are presented.

© 2022 The Authors. Published by Elsevier Inc. on behalf of University of Washington.

This is an open access article under the CC BY-NC-ND license (<http://creativecommons.org/licenses/by-nc-nd/4.0/>)

Introduction

Myofibroblastoma (MFB) is a rare benign tumor comprised of fibroblasts and myofibroblasts affecting postmenopausal women and older men, first named as a distinct entity in 1987 [1,2]. It is often first noticed as a painless, palpable retroareolar mass on self-exam [3]. A palpable, mobile, solid tumor is often described on clinical exam. Immunohistochemical and histological analysis show a well demarcated mass of bipolar spindle cells that arise from mesenchyme and display myofibroblastic differentiation [4]. Imaging findings can be nonspecific and further emphasis is placed on immunohistochemistry and histopathological examination for diagnosis and management [3]. This tumor may be mistaken for other benign lesions such as hamartomas and fibroadenomas, or malignant

lesions such as invasive lobular carcinoma [4–6]. Misdiagnosis presents the potential for harmful overtreatment beyond appropriate surgical removal [4,7]. Here, we report a case of a 69-year-old male with a diagnosis of myofibroblastoma of the right breast.

Case report

A 69-year-old male diagnosed with a tubulovillous adenoma with high grade dysplasia of the right colon and a villous adenoma of the rectum one month prior to evaluation of his breast mass. Staging CT demonstrated a right breast mass (Fig. 1) and he thereafter presented to the breast clinic with a palpable nontender right breast mass. He first noticed

[☆] Competing Interests: The authors have read and understood the journal's policy on declaration of interest and declare the following: None of the authors have conflicts to declare.

^{*} Corresponding author.

E-mail address: cherie_kuzmiak@med.unc.edu (C.M. Kuzmiak).

<https://doi.org/10.1016/j.radcr.2022.08.087>

1930-0433/© 2022 The Authors. Published by Elsevier Inc. on behalf of University of Washington. This is an open access article under the CC BY-NC-ND license (<http://creativecommons.org/licenses/by-nc-nd/4.0/>)

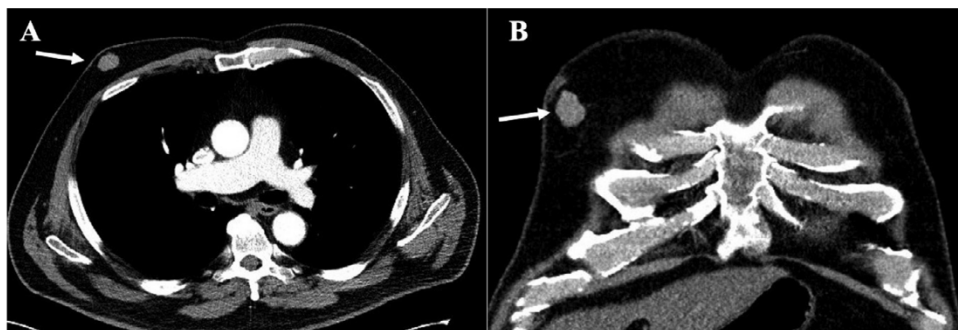


Fig. 1 – CT of the chest with contrast. Axial (A) and coronal (B) images demonstrate a right retroareolar breast mass (arrow) measuring approximately 2.3 cm size.

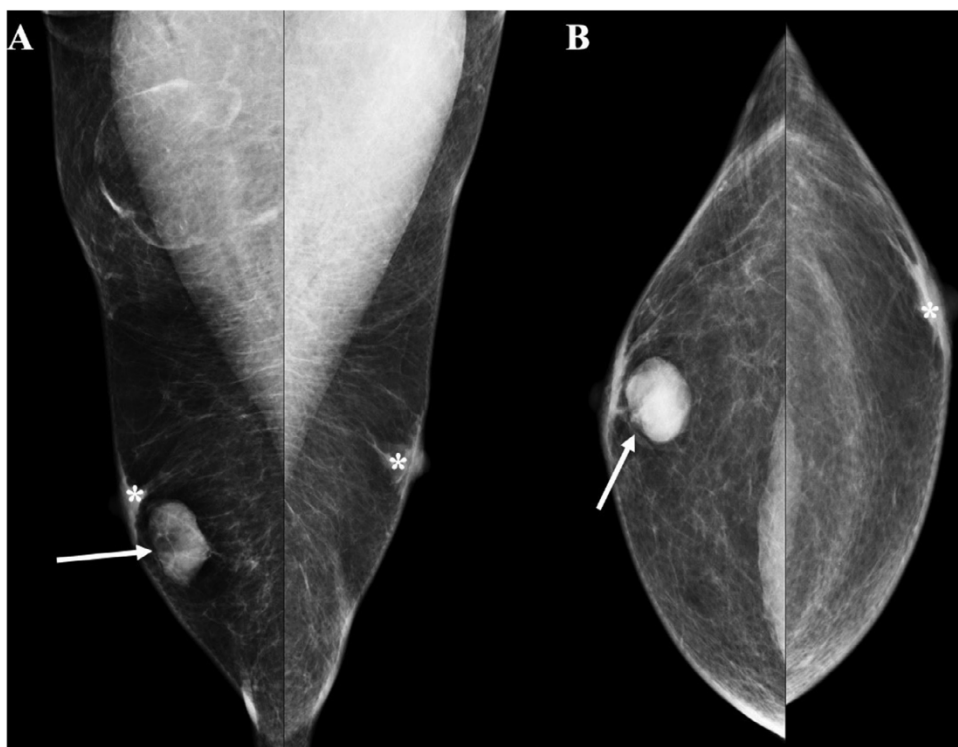


Fig. 2 – Bilateral diagnostic mammography. MLO (A) and CC (B) projections demonstrate a 2.9 cm oval, circumscribed, high-density mass (arrow) in the retroareolar region of the right breast at the palpable region of concern. Bilateral gynecomastia (*) also noted. Calcifications, architectural distortions, and skin/nipple retraction are absent.

the mass 3 months prior to presentation and denied any known breast trauma. He had no personal or family history of breast cancer; however, he had brothers with liver and lung cancers and sisters with lymphoma and endometrial cancers. A diagnostic mammogram demonstrated a 2.9 cm oval, circumscribed mass in the retroareolar region of the right breast. A right axillary lymph node was also noted, with a normal cortex and a prominent fatty hilum. Mammography also demonstrated minimal bilateral gynecomastia (Fig. 2). Targeted ultrasound of the right breast showed a 2.5 × 2.9 × 1.1 cm oval, parallel, not circumscribed, hypoechoic mass at the 6 o'clock retroareolar region (Fig. 3). No axillary adenopathy was seen on ultrasound. The patient's right

breast mass was categorized as BI-RADS 4 and biopsy was recommended.

Ultrasound-guided core needle biopsy of the right breast mass yielded a cellular spindle cell lesion consistent with MFB. The specimen stained positively for CD34 and desmin (Fig. 4). It was cytokeratin AE1/AE3 negative. The patient was referred to general surgery in the authors' institution's multidisciplinary cancer clinic to undergo surgical excision of the MFB. Although alternative management with procedures such as vacuum-assisted removal has shown significant promise, surgical excision remains the recommended treatment for MFB. It provides definitive treatment, as MFB does not have recurrence potential [6,7].

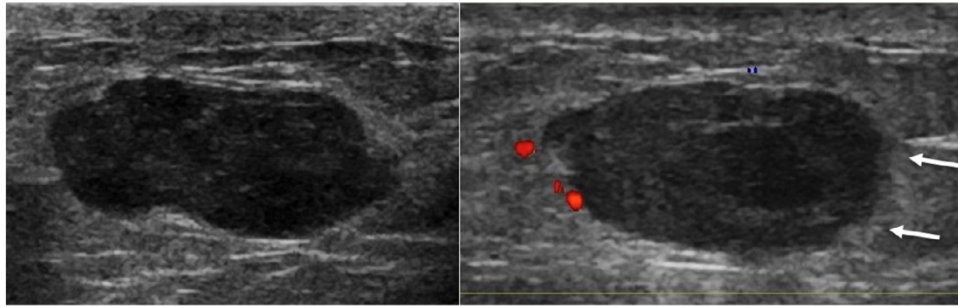


Fig. 3 – Transverse and longitudinal views with targeted ultrasound of the right breast mass demonstrate an oval, parallel, hypoechoic mass with not circumscribed (microlobulated) margins (arrows) measuring 2.5 × 2.9 × 1.1 cm in the 6 o'clock retroareolar region.

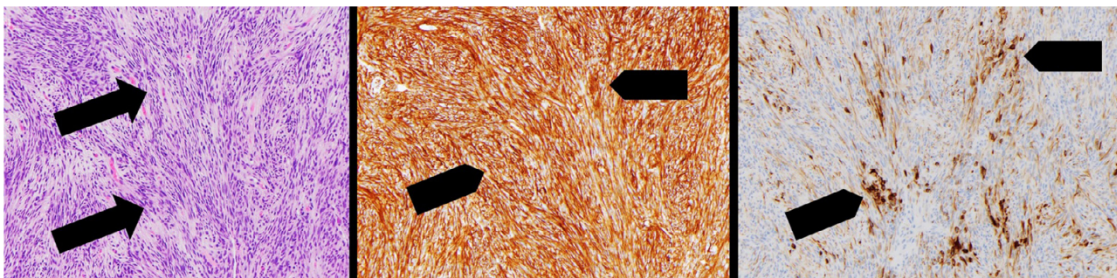


Fig. 4 – Histopathology. H&E stain ×10 (A) demonstrates bland spindle cells (arrows) with pale to eosinophilic cytoplasm. Haphazardly arranged cells and short intersecting fascicles are separated by bundles of hyalinized collagen. Mitoses are sparse. Immunohistochemistry stains for CD34 ×10 (B) and Desmin ×10 (C) are positive (arrowheads). H&E: Hematoxylin and Eosin.

In addition to his right hemicolon tubulovillous adenoma, following presentation to the breast clinic, this patient also underwent core needle biopsy of a right flank mass. Pathology of this mass confirmed a poorly differentiated malignancy, most likely melanocytic in origin.

Discussion

Myofibroblastoma is classified by the World Health Organization as a mesenchymal tumor and is a rare benign stromal tumor that most commonly presents in postmenopausal women and men between the ages of 60-70 years, as in this patient. It is typically a slow-growing, painless, non-tender, mobile breast mass [8].

The typical imaging findings of MFB are non-specific. Mammography often shows an oval, circumscribed mass without associated features such as calcifications, architectural distortion, or skin/nipple retraction [7]. On ultrasound, MFB typically appears as an oval or round circumscribed mass with heterogeneous or hypoechoic echogenicity [4,5]. Compared to other studies, on ultrasound this patient's mass was interpreted as having partial not circumscribed (microlobulated) margins. Otherwise, imaging findings for this patient were consistent with most MFB tumors.

On histopathology, MFB is a circumscribed mass consisting of bland spindle cells with pale to eosinophilic cytoplasm arranged haphazardly or in short intersecting fascicles inter-

persed with hyalinized collagen bundles. Mitoses are absent or rare (Fig 4) [8]. Commonly, MFB tumors express CD34 and desmin (Fig 4); they are cytokeratins, EMA, S100, STAT6, ALK, and B-catenin negative [5,8,9]. MFB shows variable expressivity of hormone receptors, particularly in cases where gynecomastia is present, suggesting hormones may play some role in the progression of this breast lesion [5-7]. Although several immunohistochemical characteristics are usually consistent, MFB may exhibit morphological variants. Masses may contain atypical cells, a myxoid presentation, or lipomatous features [3,7]. This variation can pose challenges in diagnosis.

In the case of morphological variants, MFB may be mischaracterized. Studies have reported the misdiagnosis of MFB as invasive lobular carcinoma in the setting of similar immunohistochemical characteristics [9]. MFB tumors have also been mistaken for more benign lesions, such as fibroadenomas and hamartomas, particularly when imaging alone is used [4]. Misdiagnosis can result in both undertreatment and overtreatment. Therefore, it is essential to use a thorough, multidisciplinary approach to the diagnosis of similar masses to ensure an accurate diagnosis is made using concordant clinical, imaging, and pathological findings [7].

There have been case reports discussing patient presentations in which MFB appears concurrently with separate neoplasms elsewhere, including genitourinary and pancreatic neoplasms [3,6]. Similarly, this patient was diagnosed with colon and rectal adenomas, as well as a likely metastatic poorly differentiated melanocytic lesion. This patient's MFB

appears to be a coincidental diagnosis. However, given the multiplicity of self and family member cancer diagnoses, an undiagnosed pathogenic variant is likely. Future genetic testing may be of benefit to this patient and his family.

Conclusion

Although benign, myofibroblastoma is a rare mesenchymal tumor of the breast presenting with non-specific clinical and imaging findings. It should be biopsied and excised for further evaluation, and to confirm concurrent pathology results are indicative of MFB. Surgical excision is the definitive treatment.

Patient consent

Written informed consent for publication of this case was obtained from the patient and is available upon request.

REFERENCES

- [1] Wargotz ES, Weiss SW, Norris HJ. Myofibroblastoma of the breast. Sixteen cases of a distinctive benign mesenchymal tumor. *Am J Surg Pathol* 1987;11(7):493–502. doi:[10.1097/00000478-198707000-00001](https://doi.org/10.1097/00000478-198707000-00001).
- [2] Magro G. Mammary myofibroblastoma: a tumor with a wide morphologic spectrum. *Arch Pathol Lab Med* 2008;132:1813–20. doi:[10.5858/132.11.1813](https://doi.org/10.5858/132.11.1813).
- [3] Venturelli M, Toss A, Cortesi L, Gambini A, Andreotti A, Cascinu S, et al. Male mammary myofibroblastoma: two case reports and brief review of literature. *Mol Clin Oncol* 2020;13(1):33–7. doi:[10.3892/mco.2020.2038](https://doi.org/10.3892/mco.2020.2038).
- [4] Mele M, Jensen V, Wronecki A, Lelkaitis G. Myofibroblastoma of the breast: case report and literature review. *Int J Surg Case Rep* 2011;2(6):93–6 DOI: [0.1016/j.ijscr.2011.02.006](https://doi.org/10.1016/j.ijscr.2011.02.006).
- [5] Khatib Y, Pandey V, Khade AL, Pandey R. Myofibroblastoma of the breast: a rare cause of breast lump in a postmenopausal woman. *J Midlife Health* 2018;9(1):47–9. doi:[10.4103/jmh.JMH_59_17](https://doi.org/10.4103/jmh.JMH_59_17).
- [6] Comer JD, Cui X, Eisen CS, Abbey G, Arleo EK. Myofibroblastoma of the male breast: a rare entity with radiologic-pathologic correlation. *Clin Imaging* 2017;42:109–12. doi:[10.1016/j.clinimag.2016.11.022](https://doi.org/10.1016/j.clinimag.2016.11.022).
- [7] Zamora KW, Talley R, Hermecz BN, Wei S. Myofibroblastoma of the breast: diagnosis, pathology and management. *J Breast Imaging* 2022;4(3):297–301. doi:[10.1093/jbi/wbac018](https://doi.org/10.1093/jbi/wbac018).
- [8] Magro G, Charville GW, Fletcher CDM, Liegl-Atzwanger B, van de Rijn M. Myofibroblastoma. *WHO Classification of Tumours Editorial Board. Breast tumours*. Lyon, France: International Agency for Research on Cancer; 2019.
- [9] Raut P, Lillemoe TJ, Carlson A. Myofibroblastoma of the breast. *Appl Radiol* 2017;46(3):42–4.

[1] Wargotz ES, Weiss SW, Norris HJ. Myofibroblastoma of the breast. Sixteen cases of a distinctive benign mesenchymal

