Point of Care Ultrasound in Crystal Arthropathy of the Cervical Spine

Ultrasound Scholarly Concentration
Case Conference #8
6/28/2022
Eric Cal, MS4

THE UNIVERSITY
of NORTH CAROLINA
at CHAPEL HILL

Case Series Outline

THE UNIVERSITY of NORTH CAROLINA at CHAPEL HILL

I. Case

II. Clinical Question

III. Literature Review

IV. Key Points

V. Indications and Challenges

This presentation contains video and audio clips. Please click on the underlined text to be directed to the appropriate media online if accessing the pdf file.

Case Presentation

- 69-year old female with PMHx of T2DM, CKD, chronic low-back pain, and HTN who presented with two day history of acute neck pain.
- Social History: Lives with husband. No sick contacts, tick exposure, or history of herpes. She reports taking all home meds as indicated. Previous smoking history of 45 pack-years.
- Review of systems: Patient reports extreme pain of the neck and left scapula pain. She reports decreased range of motion of neck and head due to pain. Denies headache, photophobia, chills, or recent infection.

Objective Data

- VS:
  - Temp = 37.8 °C
  - Heart rate = 101 BPM
  - BP = 189/86 mm Hg
  - RR=15 breaths/min
  - SpO_2=95% on room air
- LABS:
  - WBC 9.2, Hgb 10.3, Plt 263
  - Na 138, K 4.9, BUN 27, Cr 1.2
  - ESR: 54
  - CRP: 9.62
  - UA: Clean
  - CSF: WBC:190 RBC: 95
    Neutrophils: 77% Lymphocytes: 10%
    Monocytes:13% Glucose: 60 Protein: 273
- PE:
  - Constitutional: Uncomfortable-appearing female in distress
  - HENT: Sclera anicteric, EOMI, PERRLA
  - Cardiac: RRR. No murmur. Distal pulses equal bilaterally. No edema
  - Lung: CTAB, normal work of breathing on RA.
  - Abdominal: Soft, nontender, normoactive bowel sounds
  - Extremities: TTP along posterior neck and left scapula. No weakness
  - Neuro: No focal findings. Mental status alert and oriented.

Clinical Course

- Patient was started on acyclovir, ampicillin, ceftriaxone, vancomycin, and decadron on 5/1/22 due to concern for meningitis due to CSF findings.
- She had no clinical improvement at 2 days
- MR C-Spine was ordered with findings concerning for spinal epidural abscess.
- She was transferred to the SICU where a CT C-Spine was performed showing crystal arthropathy of the cervical spine.
- Literature review on the findings was performed and she was diagnosed with pseudogout of the cervical spine by CT images.
- She received appropriate treatment with improvement of symptoms in 3 days

Objective Data

THE UNIVERSITY of NORTH CAROLINA at CHAPEL HILL

- MR C-Spine (5/3/22):
  - Indeterminate finding of small T2 hypointensity along ligamentum falvum at C3-C4

Objective Data

- CT C-Spine w/o Contrast (5/3/22):
  - Thickening and ossification/calcification of ligamentum flavum at C3-4. Additional areas of less pronounced ossification/calcification of the ligamentum flavum at C4-5 and C6-7

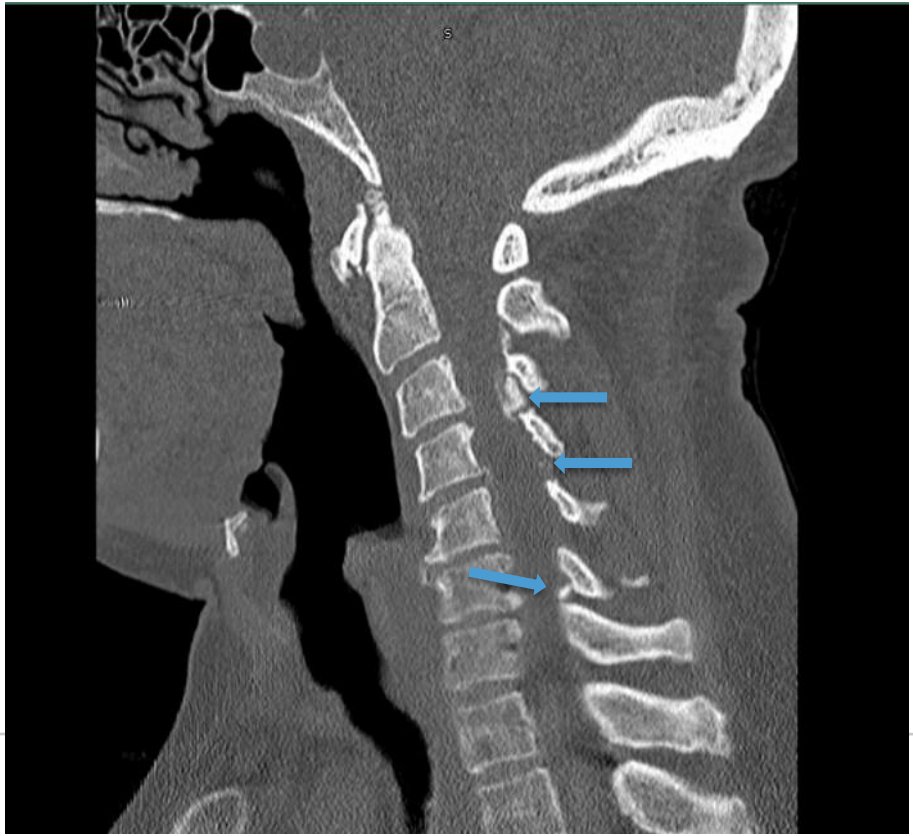

Case Imaging: Sagittal View of Cervical Spine- Anatomy and Technique

THE UNIVERSITY of NORTH CAROLINA at CHAPEL HILL

Technique

- Probe indicator faces cranially
- Place just medial to midline
- Start at C1 allowing for tracking of which joint space you are in.

*AP: Articular Process

Moreno B, Barbosa J (December 12, 2021) Ultrasound-Guided Procedures in the Cervical Spine. Cureus 13(12): e20361. DOI 10.7759/cureus.20361

Case Imaging US Sagittal View of Cervical Spine

THE UNIVERSITY of NORTH CAROLINA at CHAPEL HILL

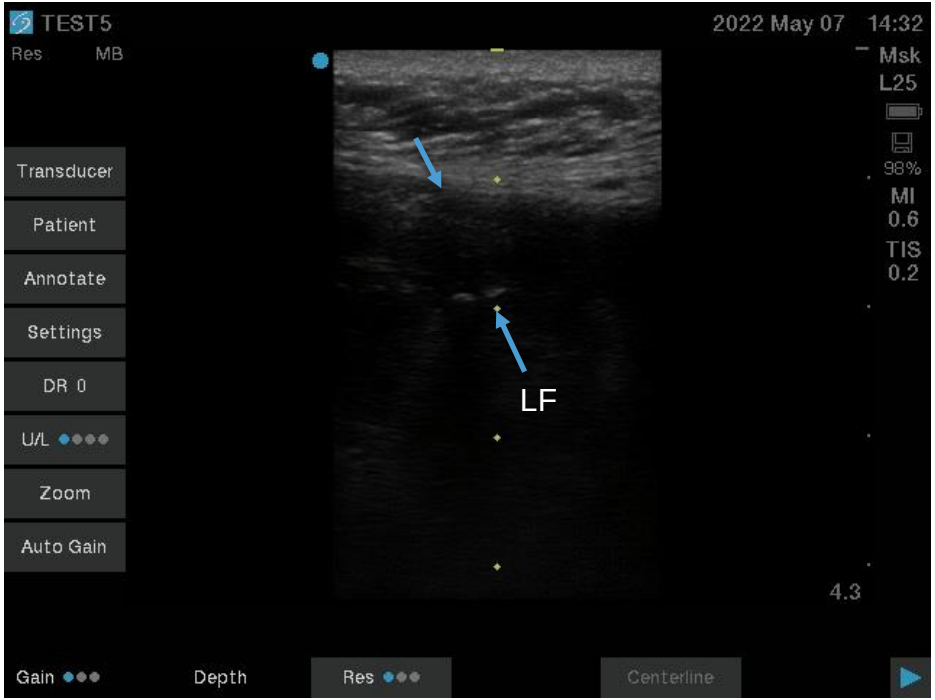

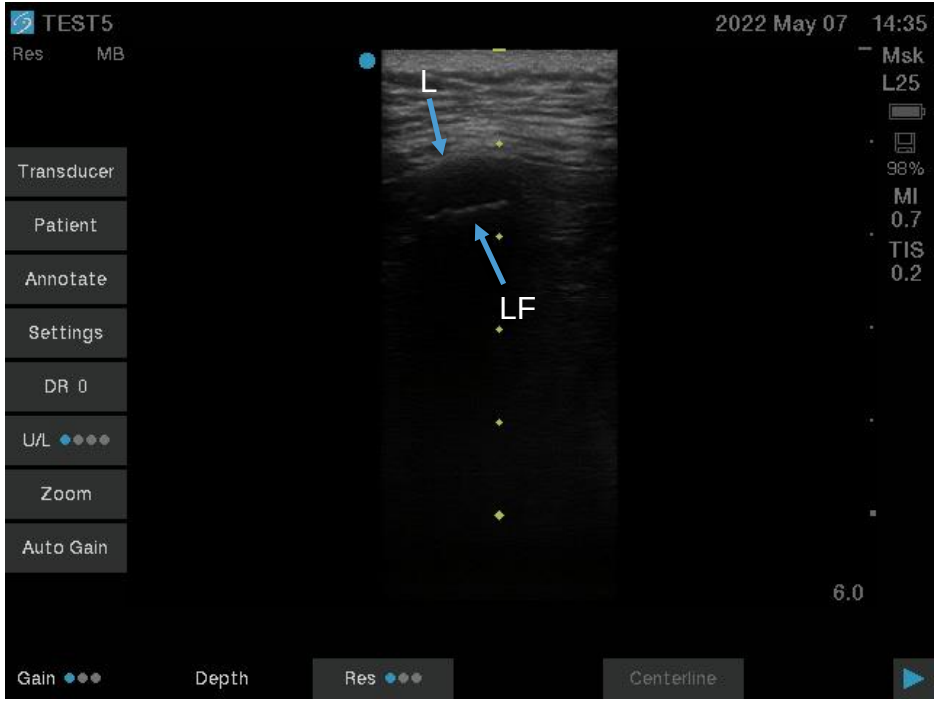

Key:

L: Lamina LF: Calcified Ligamentum Flavum

Case Imaging US Sagittal View of Cervical Spine

THE UNIVERSITY of NORTH CAROLINA at CHAPEL HILL

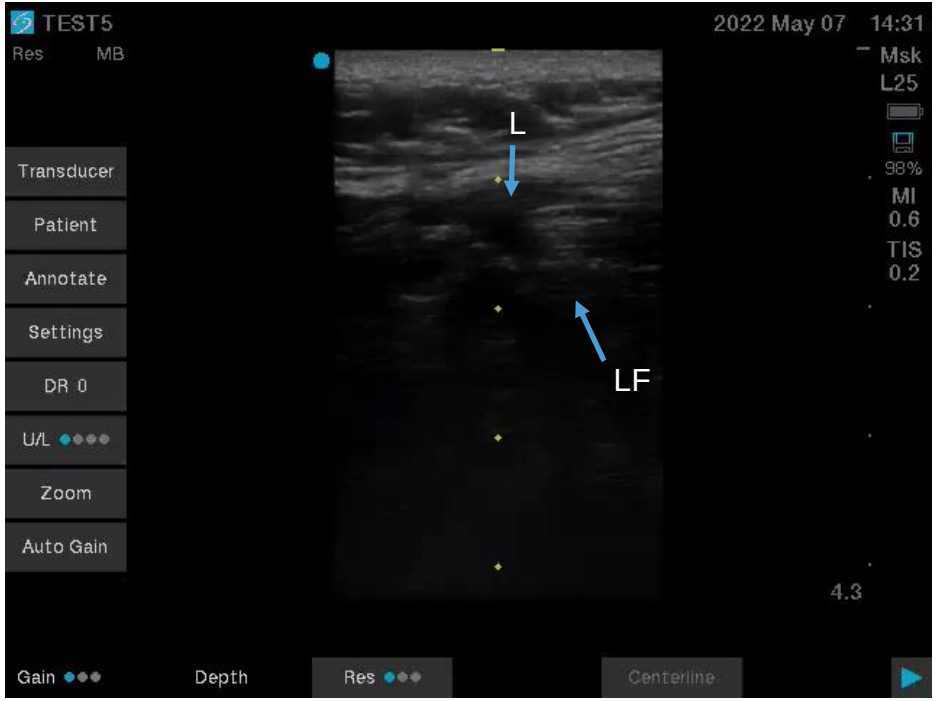

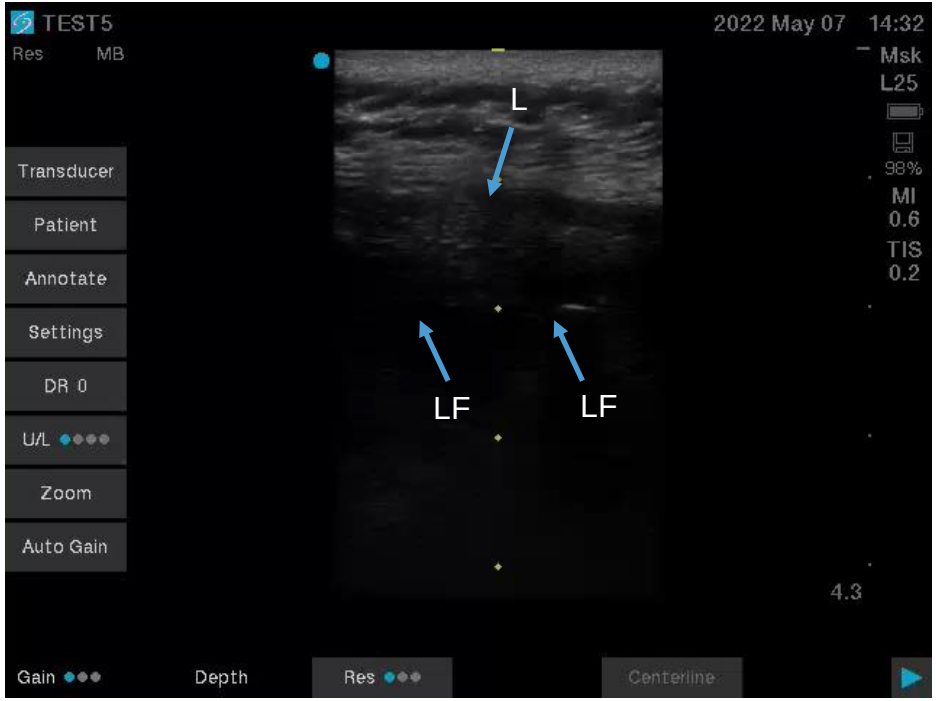

Key:

L: Lamina LF: Calcified Ligamentum Flavum

Case Imaging: Axial View of Cervical Spine- Anatomy and Technique

THE UNIVERSITY of NORTH CAROLINA at CHAPEL HILL

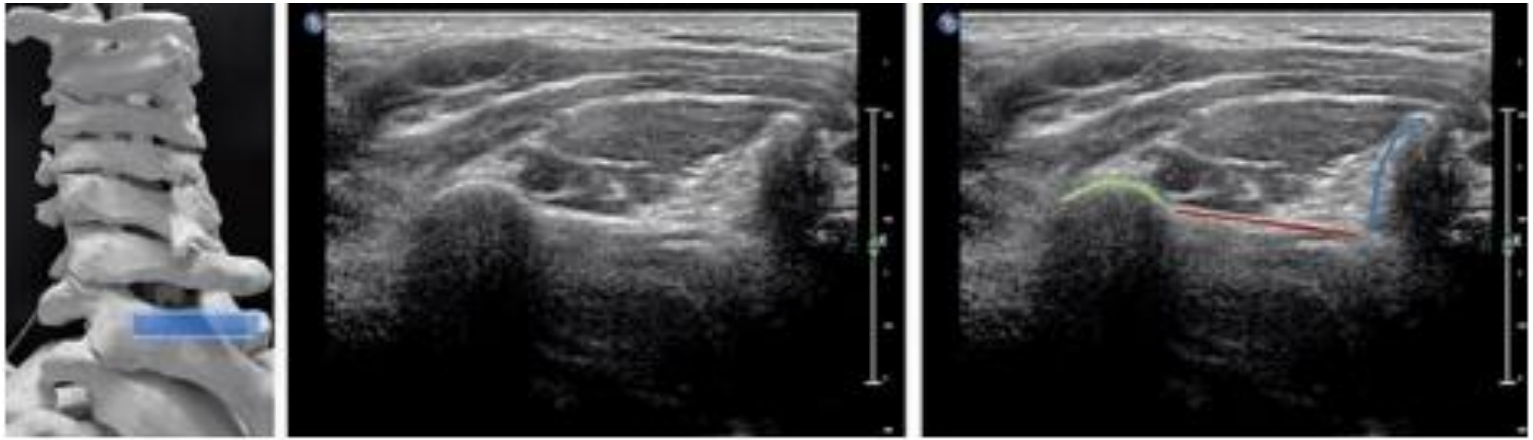

FIGURE 4: Posterior axial scan plane of the spinous process at C7 level.

Posterior axial scan plane of the spinous process (blue) at C7 level. Vertebral arch: red; articular process: light green.

Technique

- Probe indicator faces the patient's right.
- Palpate C2 to find landmark.
- Scan directly across midline

Loizides A, Obernauer J, Peer S, Bale R, Galiano K, Gruber H: Ultrasound-guided injections in the middle and lower cervical spine. Medical Ultrasonography. 2012, 14:235-8.http://www.medultrason.ro/ultrasound-guided-injections-in-the-middle-and-lower-cervical-spine/

Case Imaging US Axial View of Cervical Spine

THE UNIVERSITY of NORTH CAROLINA at CHAPEL HILL

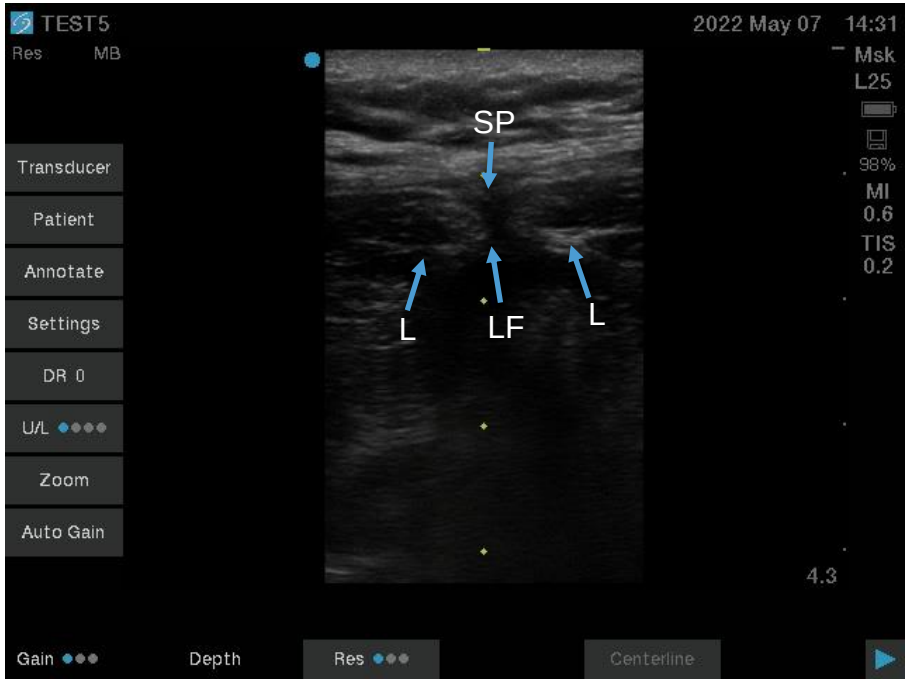

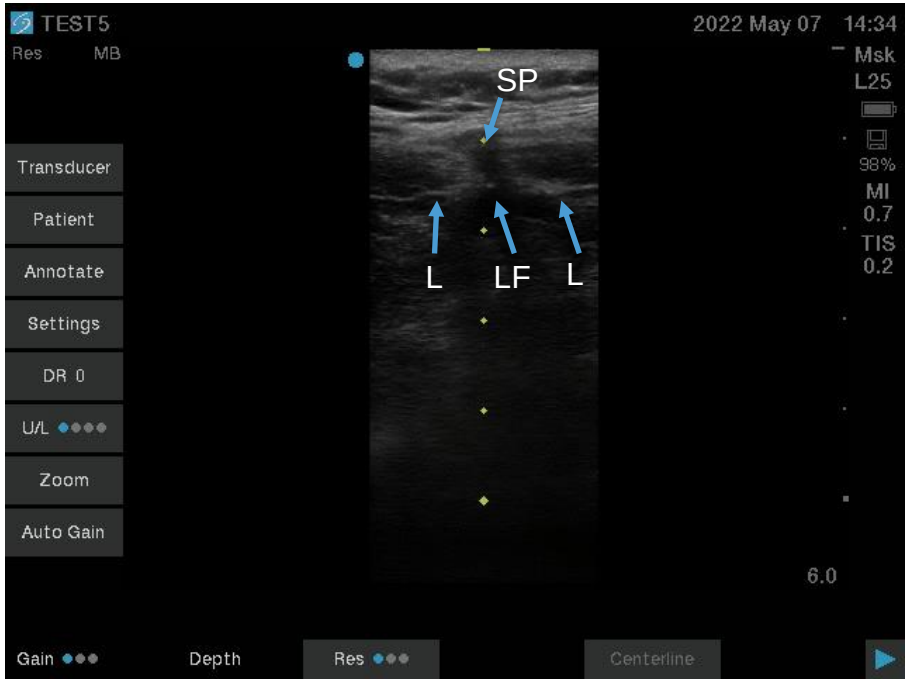

Key:

L: Lamina SP: Spinous Process LF: Calcified Ligamentum Flavum

Case Imaging US Axial View of Cervical Spine

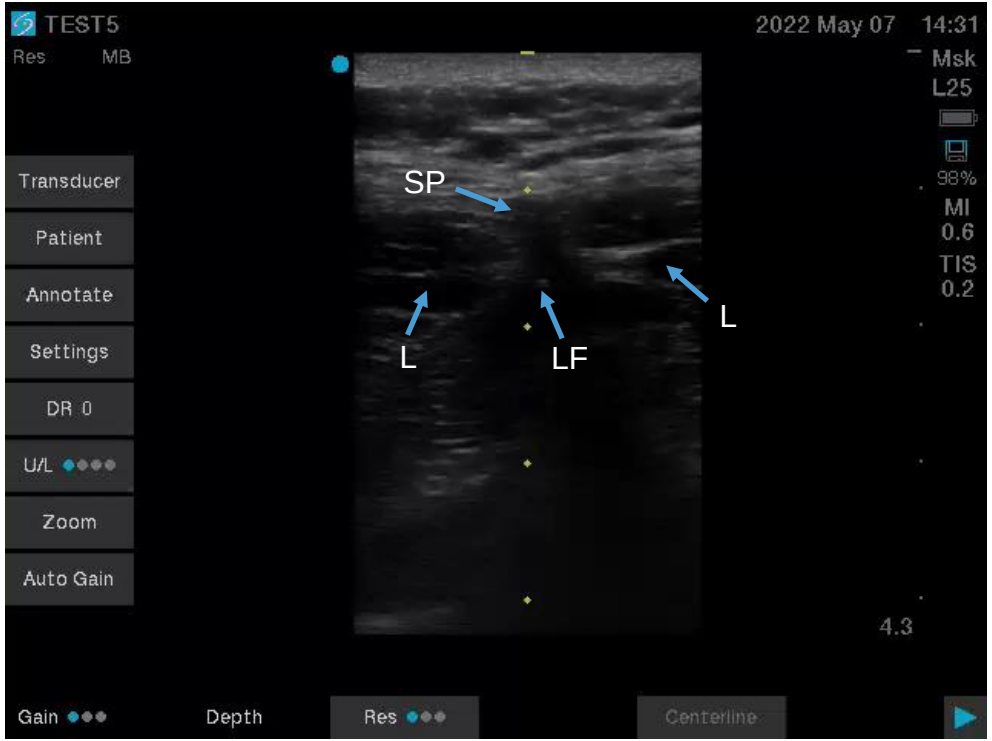

Key:

L: Lamina SP: Spinous Process LF: Calcified Ligamentum Flavum

Clinical Question

What is the utility of POCUS in identifying cervical spine crystal arthropathy as those found in cervical spine pseudogout?

Literature Review

THE UNIVERSITY of NORTH CAROLINA at CHAPEL HILL

Detection of Calcium Pyrophosphate Deposition (CPPD) Disease : Veteran Affairs

Table 1

Advantages and disadvantages of commonly used imaging techniques in CPPD

	Advantages	Disadvantages
Conventional radiology	• Widely available • Commonly used to image joints • Low cost Low radiation exposure	• Low sensitivity • May miss CC in small joints Provides a 2D image
CT scanning	• Widely available • Quick exam • Can detect CC in small joints • Provides a 3D image	• Not commonly used to image painful joints modality • Higher radiation exposure High cost
MRI	• Useful to diagnosis non-CPPD pathology • Commonly used to image joints • Provides a 3D image	• High cost • Poor sensitivity • Poor specificity Lengthy exam
Ultrasound	• Good sensitivity in experienced centers • Good specificity in experienced centers • Widely available in many clinics • Can be performed at the bedside Absence of radiation exposure	• Very operator dependent • "Double contour sign" of gout may confuse interpretation Some joints are not easily accessible to examination

Study Design: Systemic Review
Results: "Conventional radiography and CT scanning continue to provide important diagnostic information in this disease. In concert with ultrasound, these techniques highlight the polyarticular and systemic nature of CPPD, the high frequency of tendon and ligament calcification, and the inflammation and tissue destruction associated with CPP crystals."

Take Away: Miksanek and Rosenthal demonstrate that ultrasound is a useful modality for the detection of peripheral CPPD

Miksanek J, Rosenthal AK. Imaging of calcium pyrophosphate deposition disease. Curr Rheumatol Rep. 2015;17(3):20. doi:10.1007/s11926-015-0496-1

THE UNIVERSITY of NORTH CAROLINA at CHAPEL HILL

Diagnosis of Pseudogout of the Cervical Spine: Shinshu University

Table 1. Summary of patients with CPPD crystal deposition disease of the cervical spine

Patient No.	Age	Sex	Inflammation markers			Calcifications in the cervical spine		Suspected diagnosis before consultation
			CRP	ESR	WBC	Periodontoid str.	Lig. flava	
1	83	F	18.02	n. e.	9620	+	+ (C3 – 7)	Occipital neuralgia
2	82	M	13.70	n. e.	7920	+	+ (Th1)	Tension-type headache
3	78	M	11.67	n. e.	11500	+	+ (C4)	Subarachnoid hemorrhage
4	75	M	2.05	n. e.	9120	+	–	
5	92	F	12.31	97	9170	+	+ (C2 – 6)	Collagen disease
6	76	F	n. e.	n. e.	5600	+	–	
7	54	M	n. e.	n. e.	7300	+	–	
8	80	M	n. e.	n. e.	n. e	+	+ (Th1 – 2)	
9	78	F	15.96	87	8030	+	–	Polymyalgia rheumatica
10	71	M	11.00	n. e.	11000	+	–	Cervical spondylosis
11	85	F	3.60	n. e.	6800	+	+ (C5)	
12	79	F	13.17	n. e.	7960	+	–	Meningitis
13	78	M	6.20	57	7970	+	–	Bacterial spondylodiscitis
14	74	F	4.03	80	9160	+	–	Epidural abscess
Mean	77.5		10.16	80.3	8550			
SD	8.5		5.35	20.8	1623			

CRP, serum C-reactive protein; ESR, erythrocyte sedimentation rate; WBC, white blood-cell count; Periodontoid str., Periodontoid structure; Lig. Flava, Ligamentum flava; n.e., not examined

Study Design: Retrospective
Inclusion Criteria: Patients with diagnosed pseudogout attacks of cervical ligamentum flavum
Total Participants: 18 patients
Results: "There were no remarkable findings on roentgenograms or magnetic resonance imaging (MRI) of the cervical spine. Computed tomography of the cervical spine demonstrated linear calcific deposits in the transverse ligament of atlas (crowned dens syndrome) in all patients. Calcific deposits were also found in other periodontoid structures and the ligamenta flava in some patients."

Take Away: Psuedogout of the c-spine commonly follows a similar clinical presentation and is rarely identified prior to patients undergoing several invasive procedures. CT is the method of diagnosis of pseudogout of the c-spine. US has not been explored as a possibility of diagnosis.

Sekijima, Yoshiki et al. "CPPD crystal deposition disease of the cervical spine: a common cause of acute neck pain encountered in the neurology department." Journal of the neurological sciences vol. 296,1-2 (2010): 79-82. doi:10.1016/j.jns.2010.05.028

Key Points

- There has not been previously published ultrasound images of cervical spine pseudogout. Additional studies are needed for its viability as an imaging modality.
- CT is the verified imaging modality for cervical spine pseudogout
- POCUS may give the opportunity to visualize cervical spine pseudogout preventing unnecessary invasive procedures.
- Cervical spine pseudogout follows a common clinical presentation. Think of it as a possible explanation of acute neck pain with unclear etiology

Indications and Challenges

Indications

- Clinical presentation of focal neck pain that is not clearly meningitis
- Acute neck pain that does not respond appropriately to proper empiric treatment for meningitis and MSK trauma
- Acute neck pain in patients with HTN, D2M, and history of gout

Challenges

- Bony anatomy of cervical spine obscures majority of imaging with ultrasound
- Symptoms of severe neck pain and decreased neck flexion prevent patients from assisting in creating better windows to image between spinous processes
- Low levels of training in c-spine ultrasound by many providers