RADY 403 Anterior Shoulder Dislocations

Shawn Ahuja, 07/22/22

UNC SCHOOL OF MEDICINE Radiology

Focused patient history and workup

- 18 y/o M with no PMHx
- Initially dislocated their left shoulder while wrestling
  - Reduced by a “family friend” EM physician
- ~3 weeks later had another dislocation after forceful abduction when colliding with another player in a lacrosse game
  - Shoulder deformity noted, reduction by athletic trainer failed which prompted ED visit.
- No other injuries, grossly neurovascularly intact, reduced in the ER
- Restored ROM with mild pain on external rotation at 1 week clinic visit

List of imaging studies

- X-Ray of the left shoulder (AP and axillary views)

- MRI of the left shoulder with contrast (MR Arthrogram)

X-Ray (AP View)

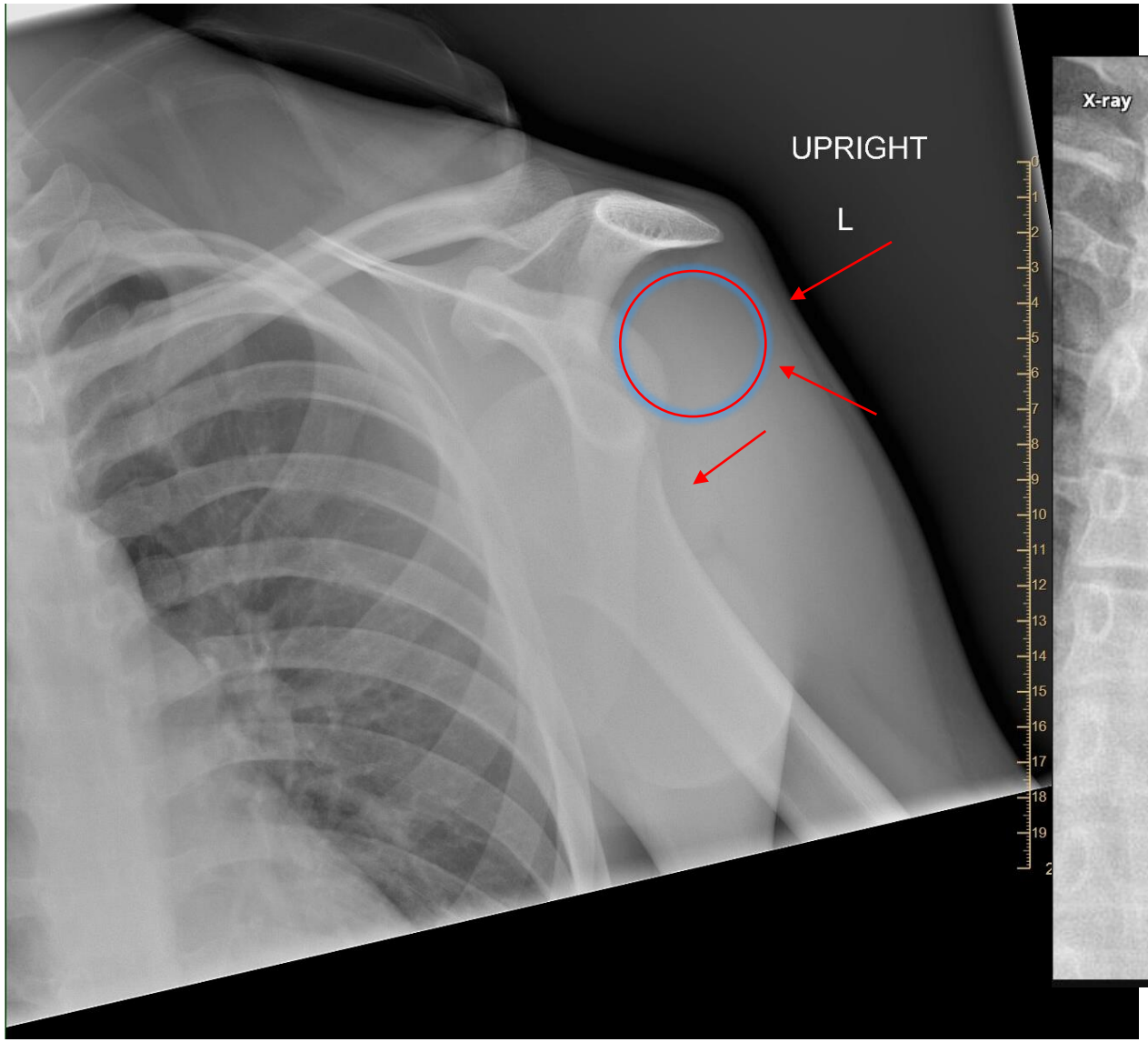

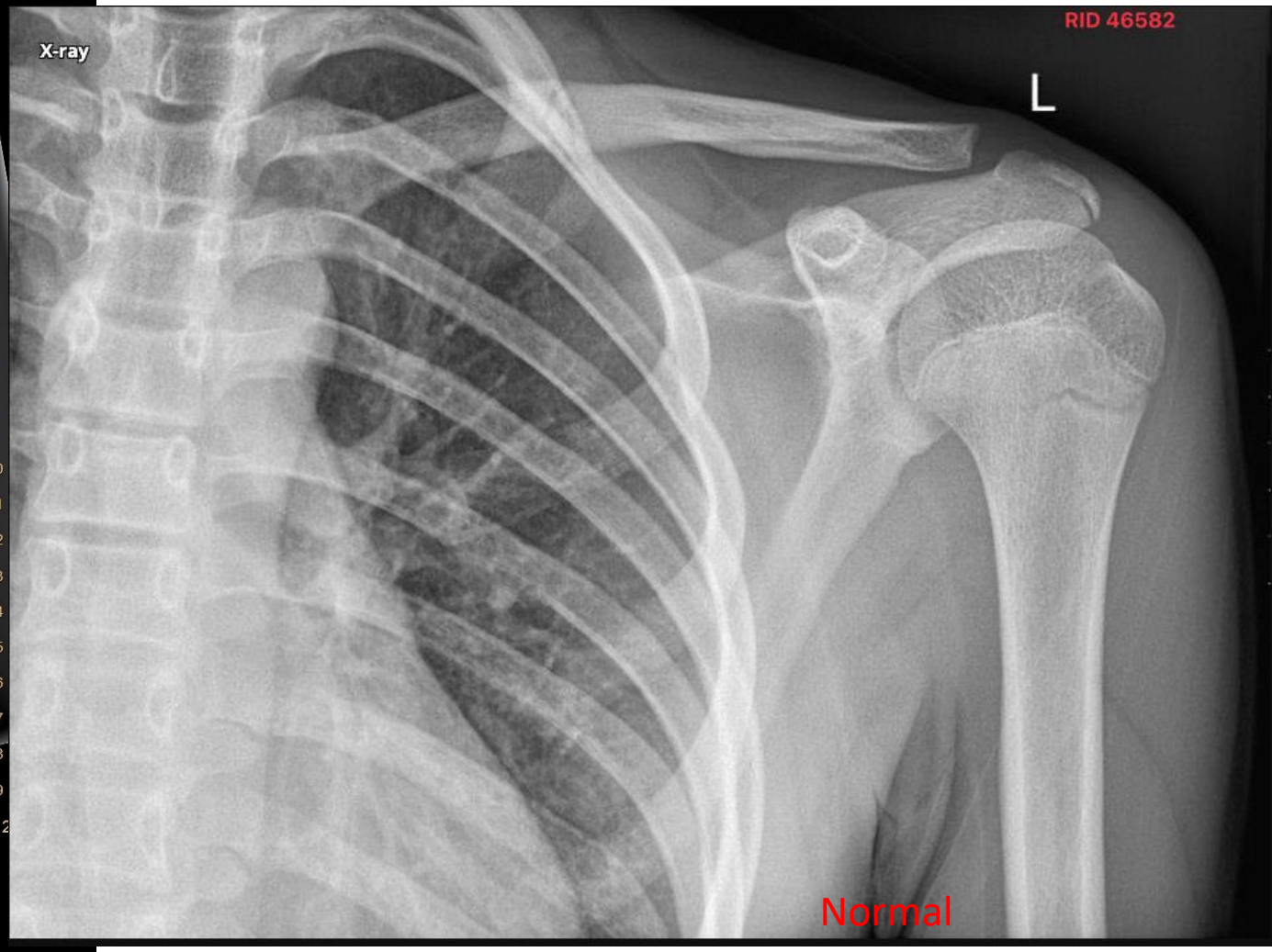

X-Ray (AP View)

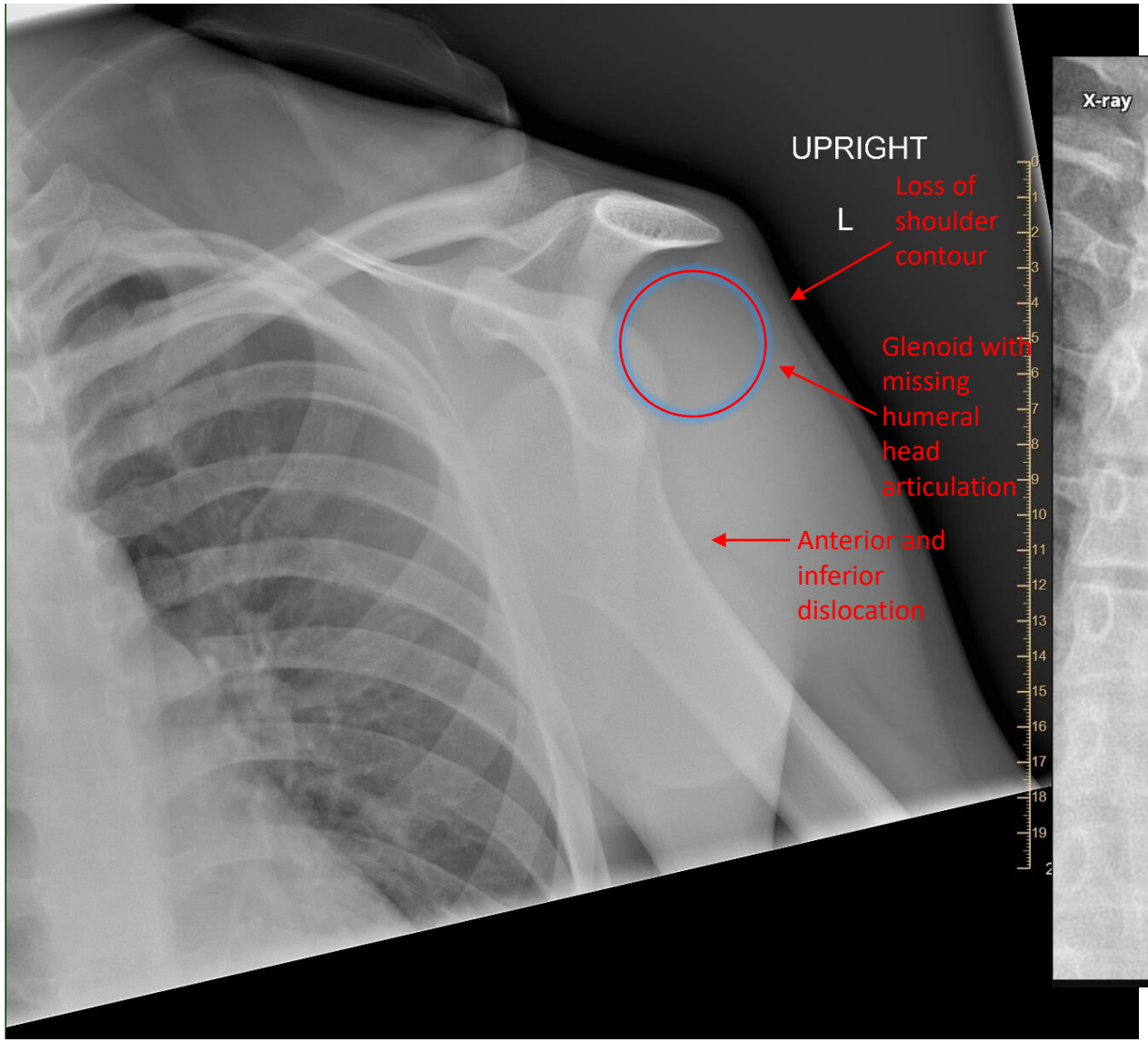
UPRIGHT
L
Loss of shoulder contour
Glenoid with missing humeral head articulation
Anterior and inferior dislocation

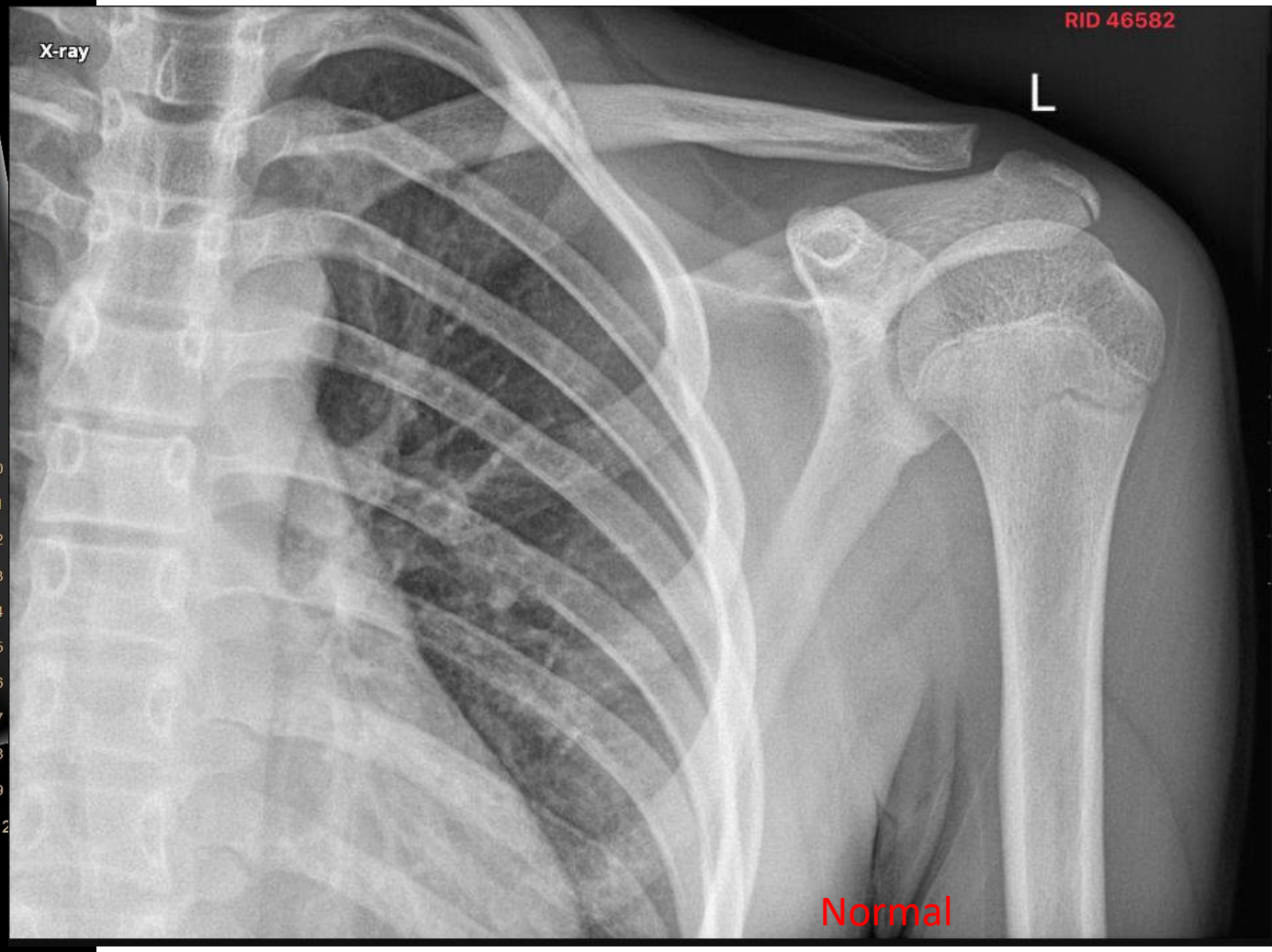
X-ray
RID 46582
L
Normal

X-Ray (Axillary view)

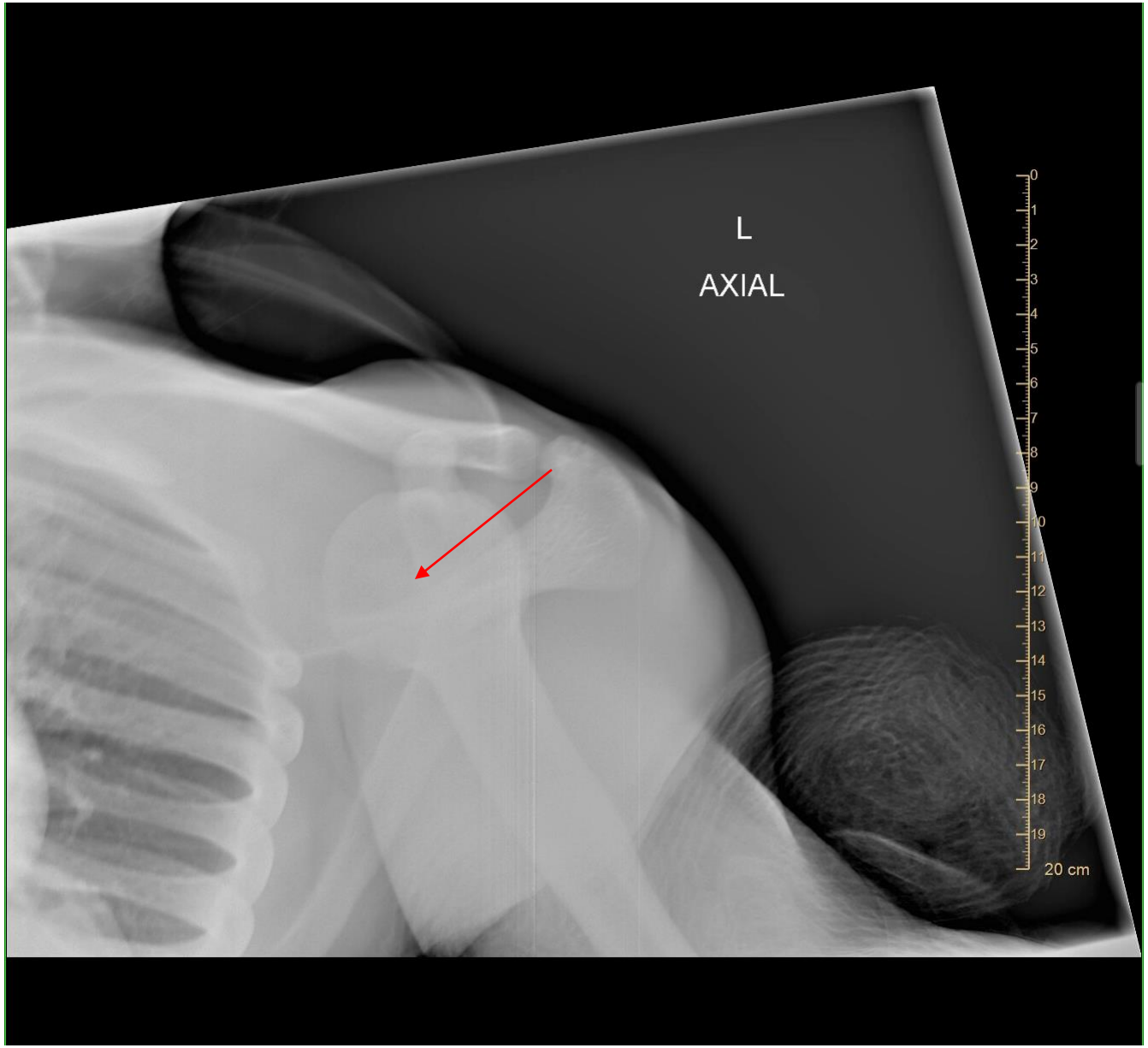

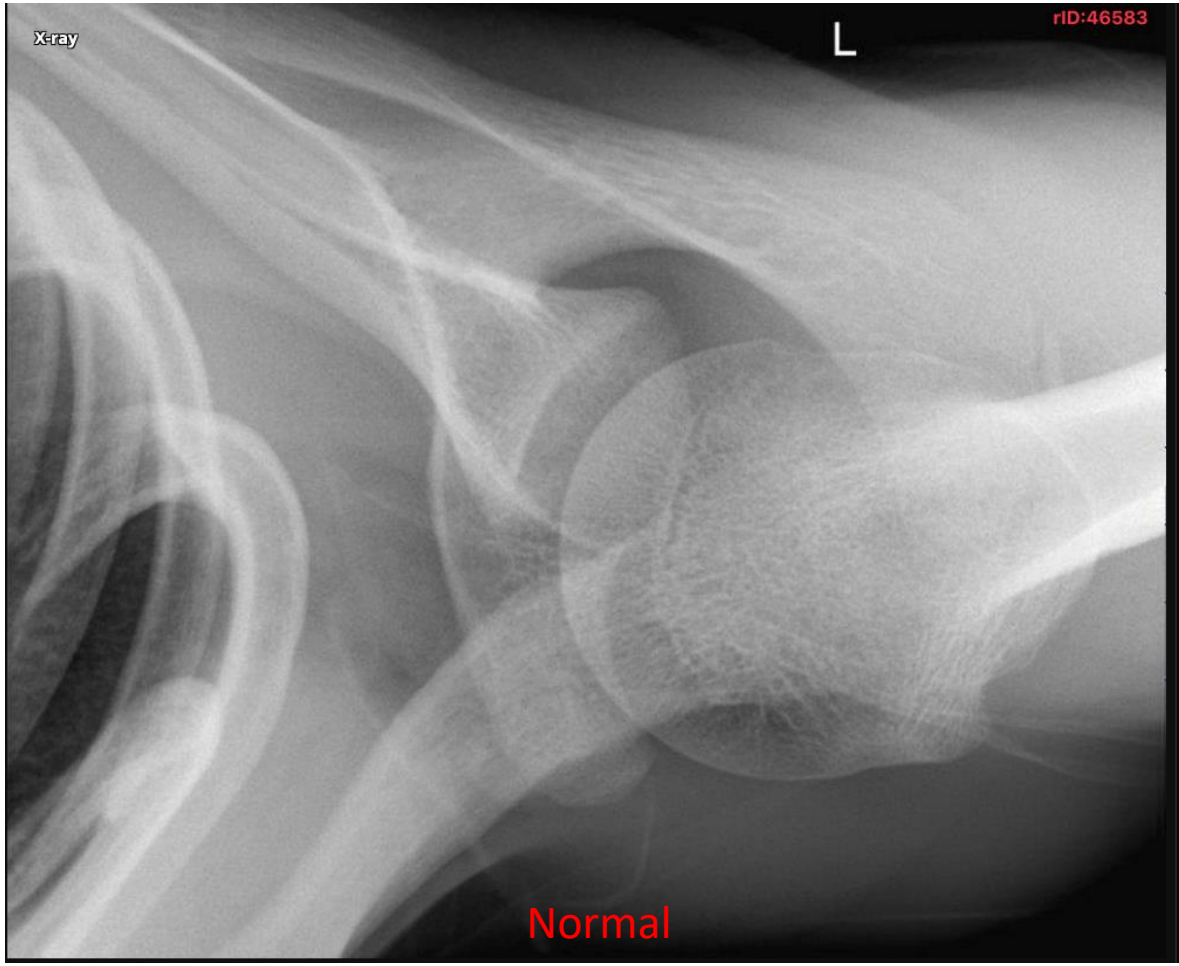

X-Ray (Axillary view)

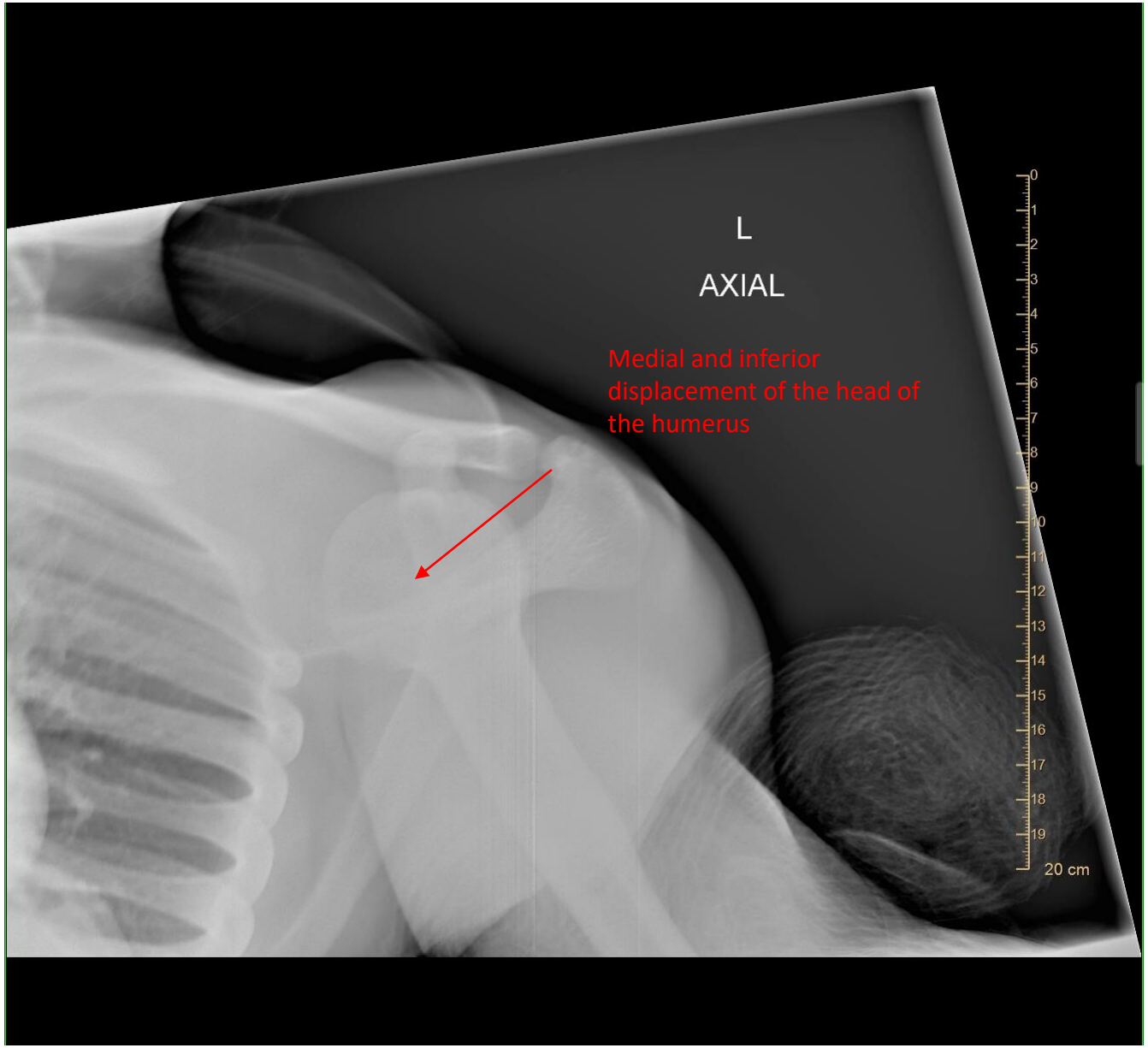

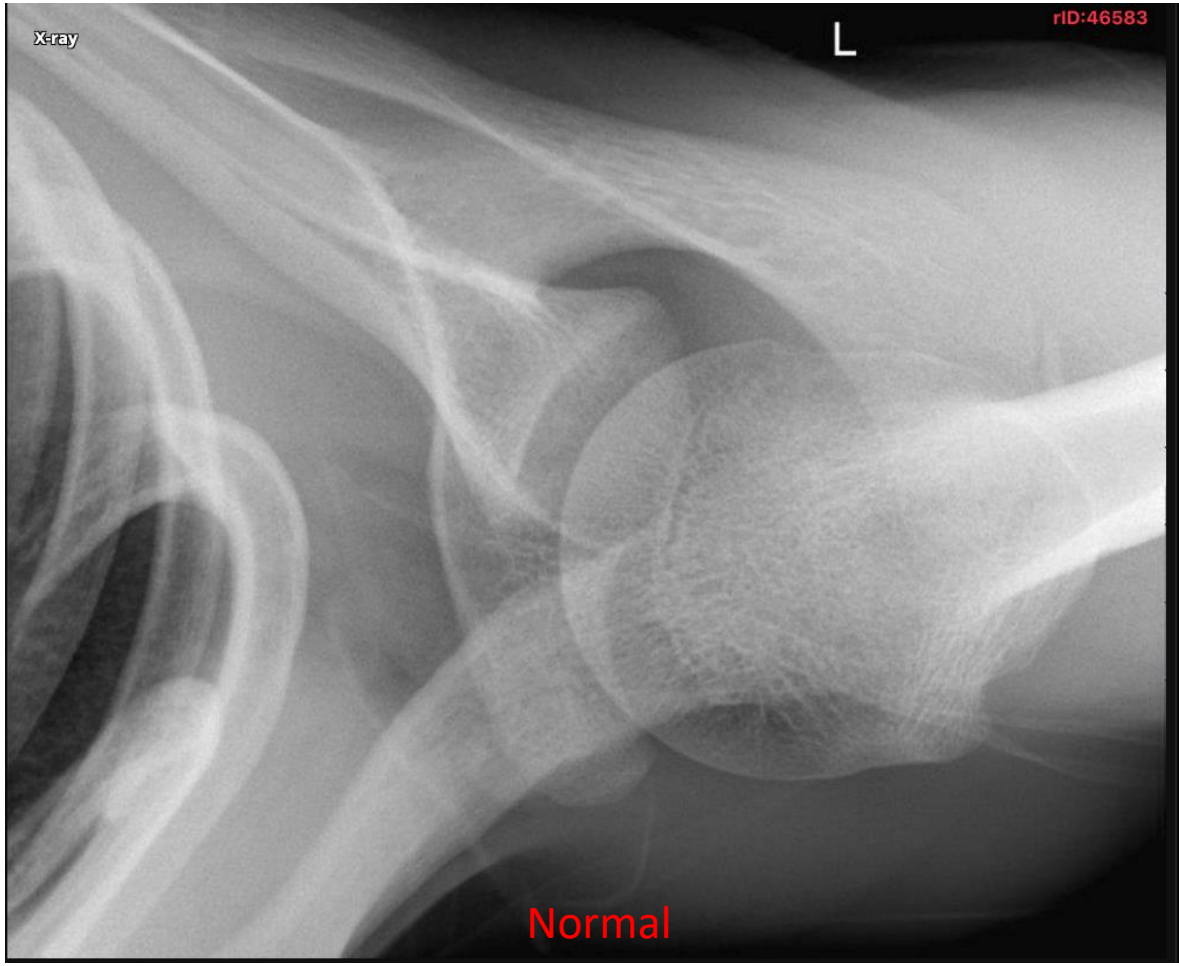

X-Ray(AP and Axial, post reduction)

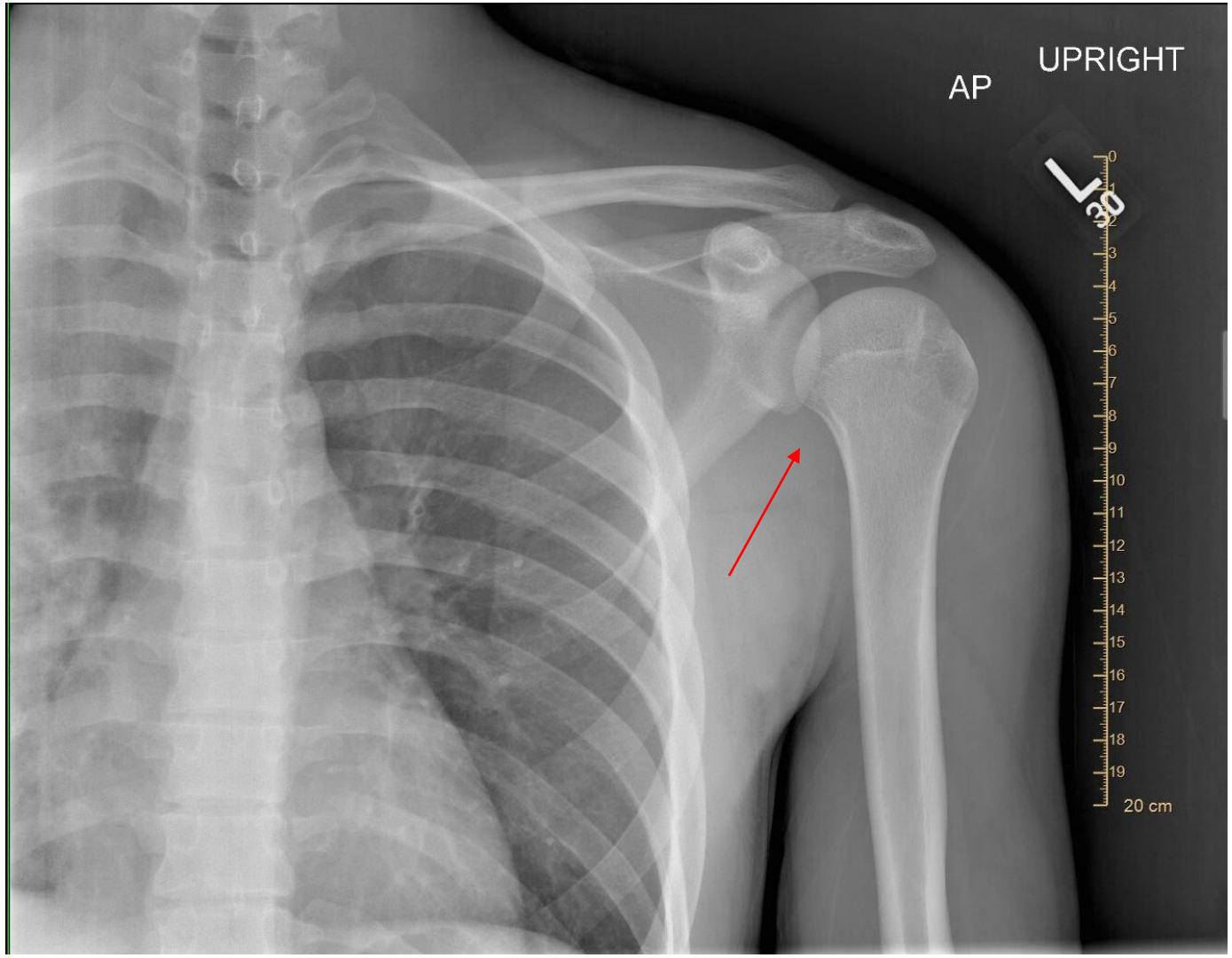

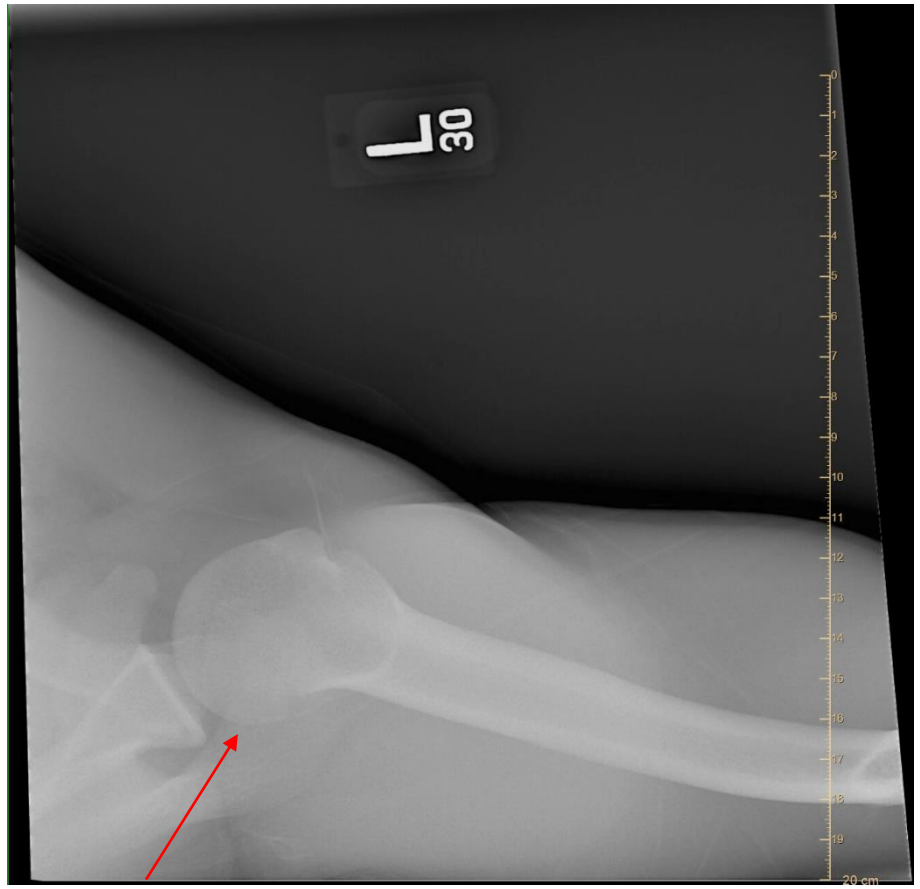

MRI (T1FS and T2FS, Axial)

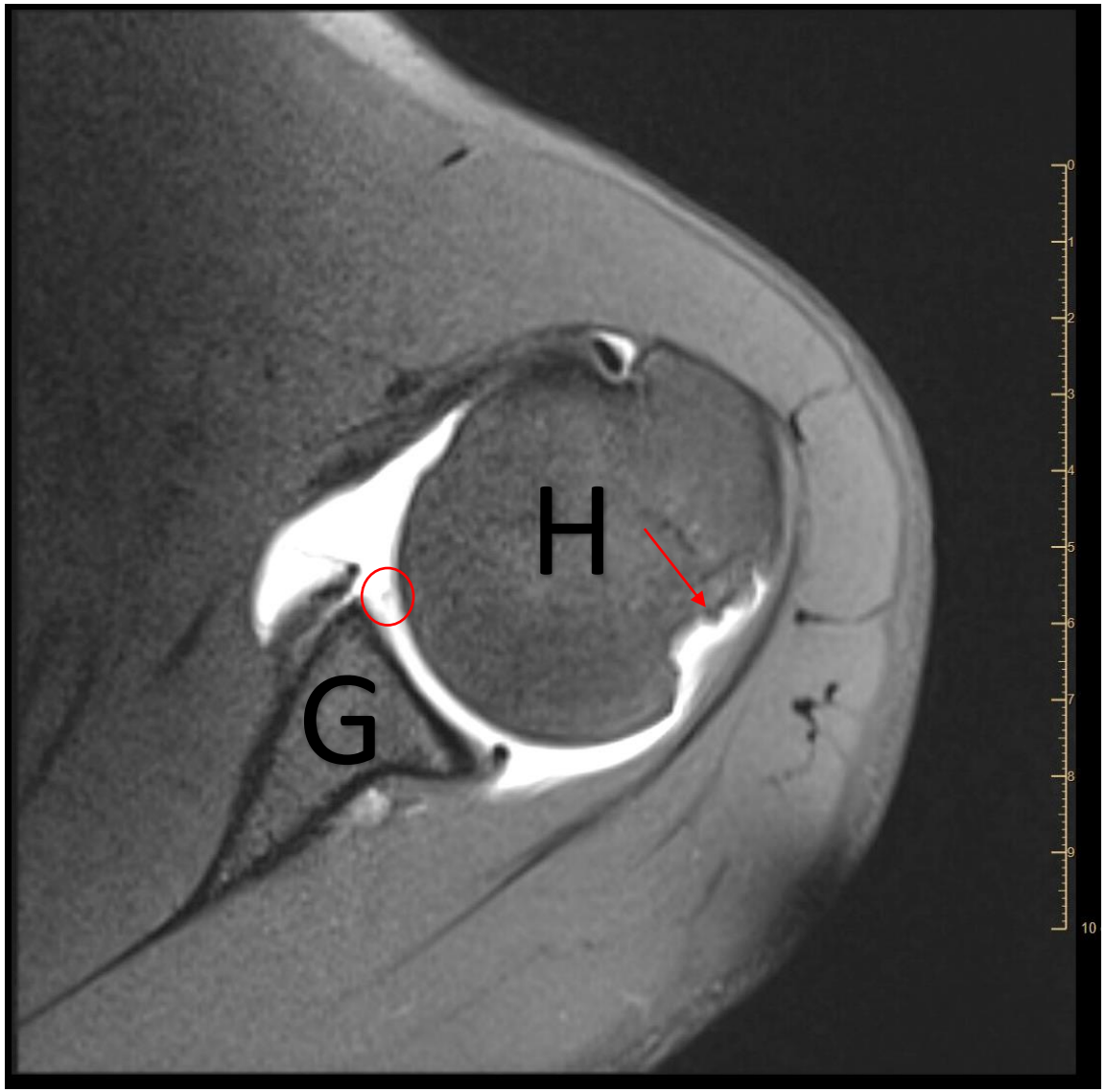

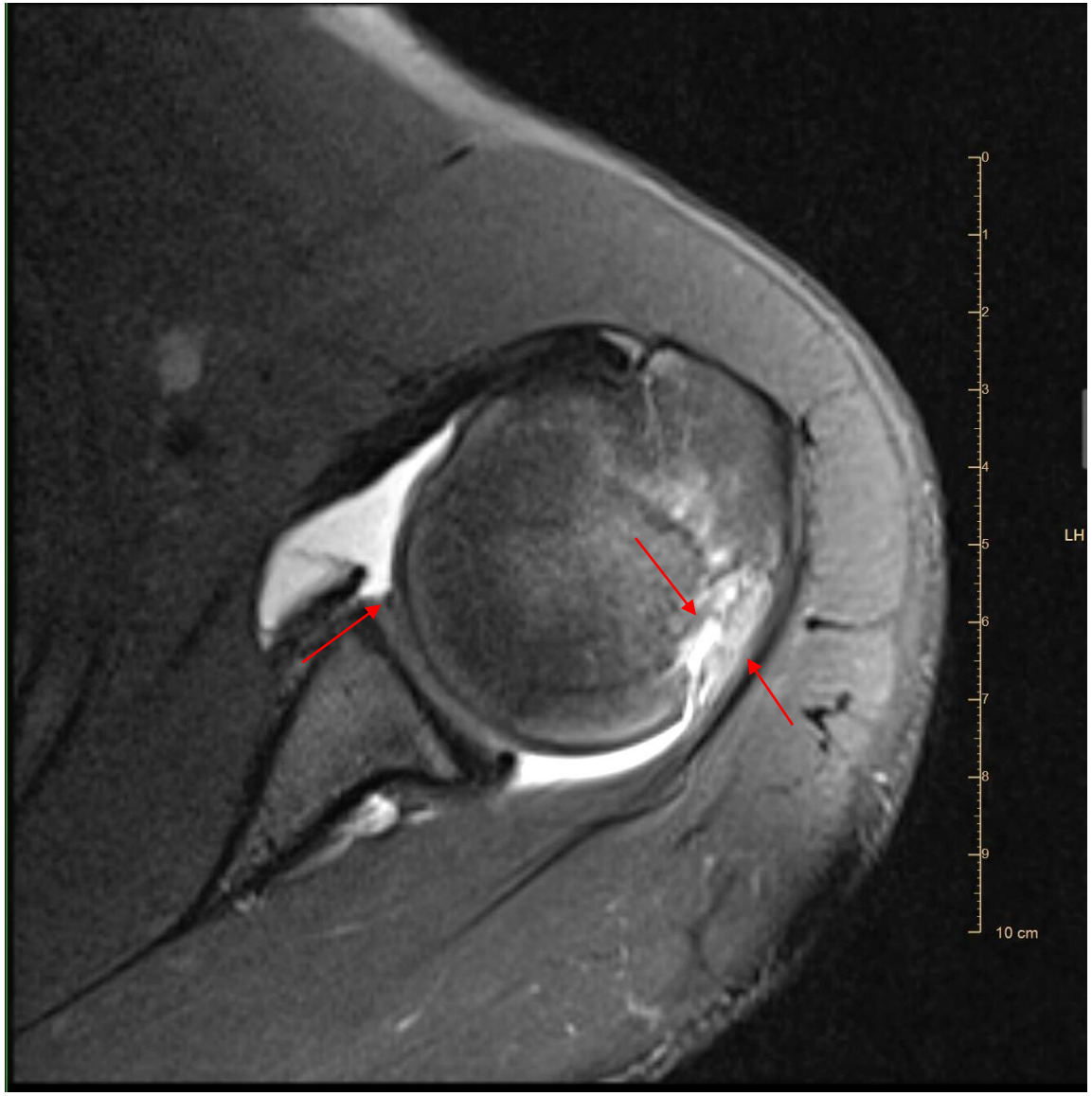

MRI (T1FS and T2FS, Axial)

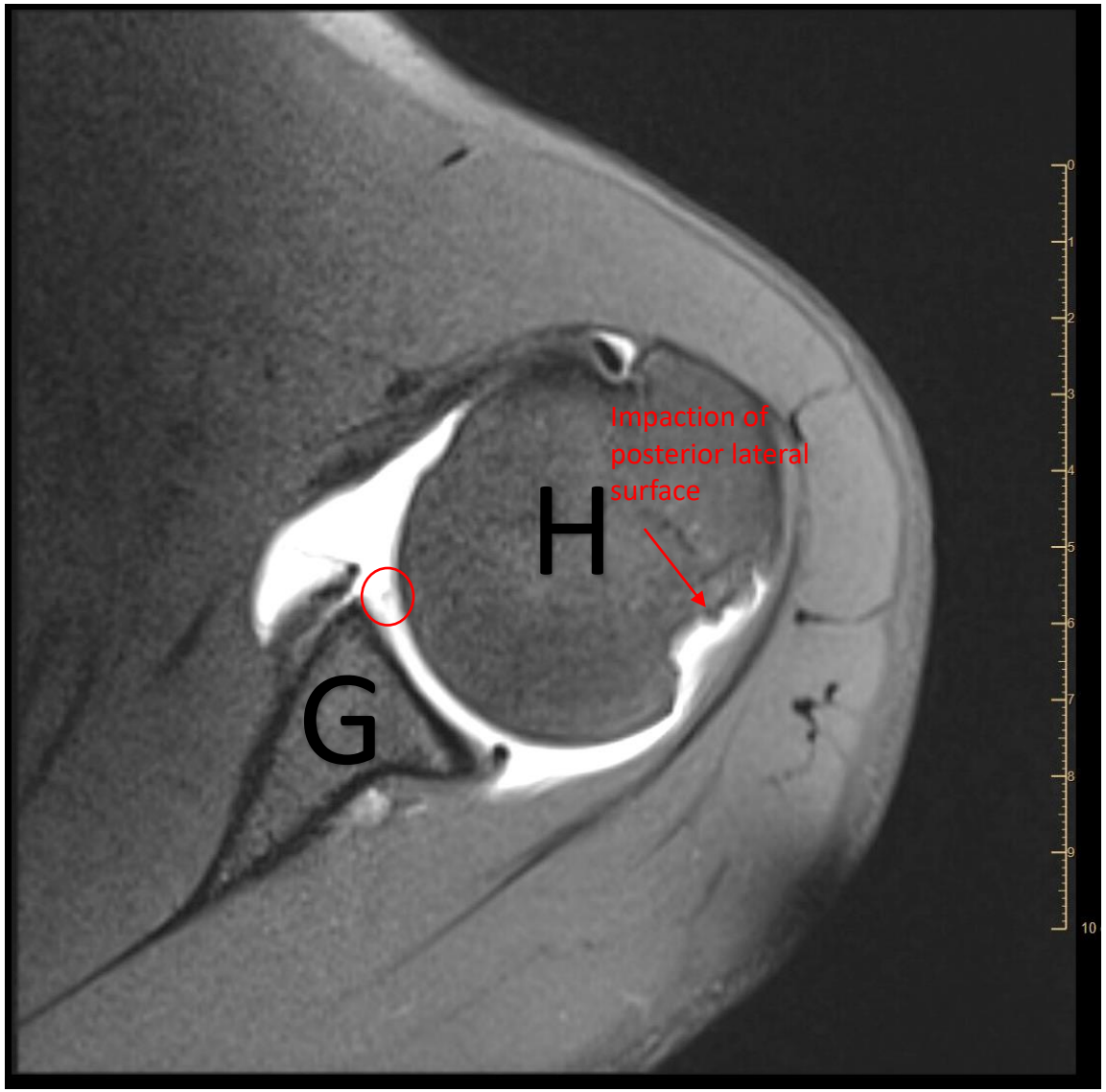

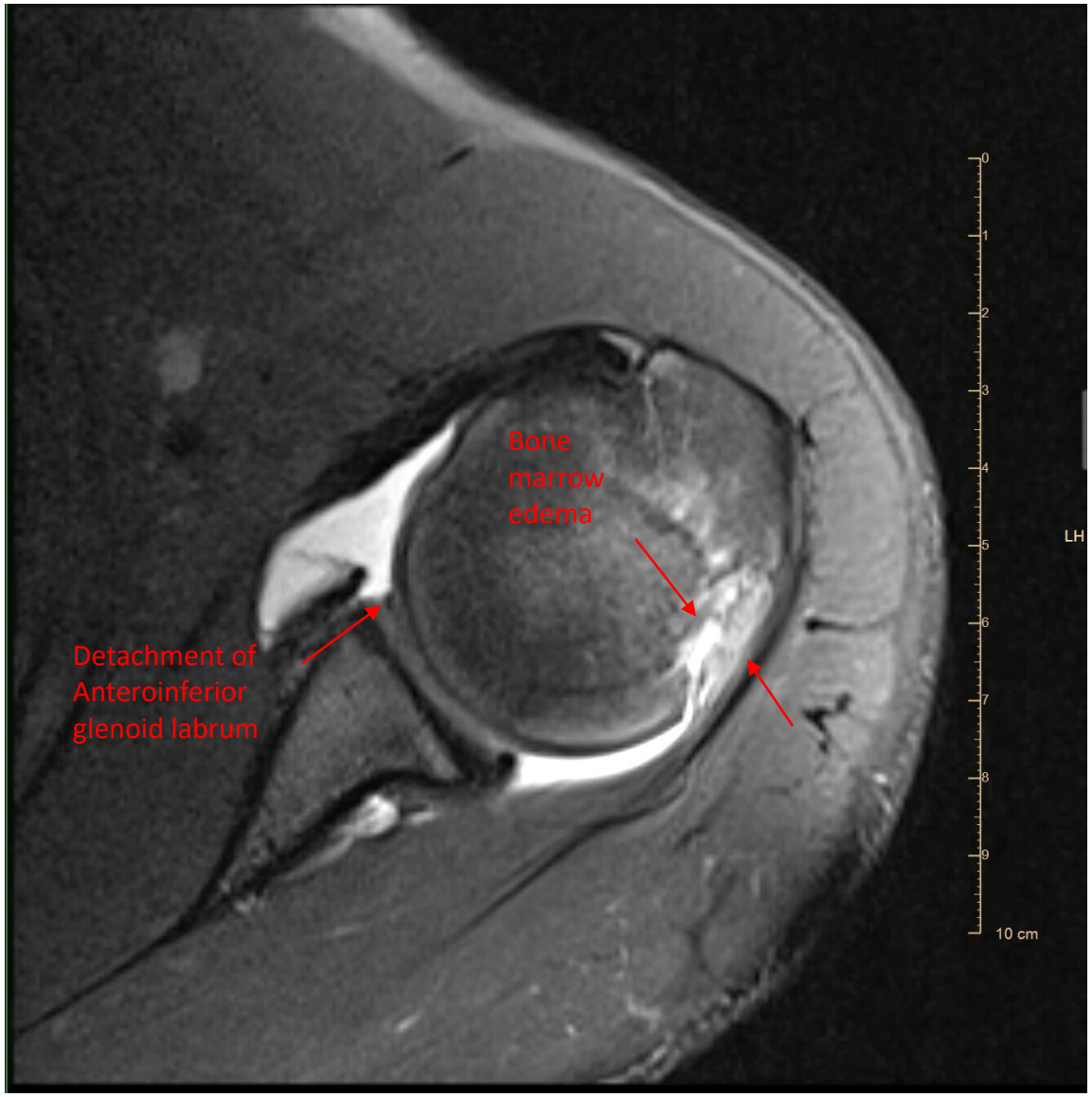

H= Humerus, G= Glenoid/Scapula

MRI (T1FS vs T2FS, Coronal)

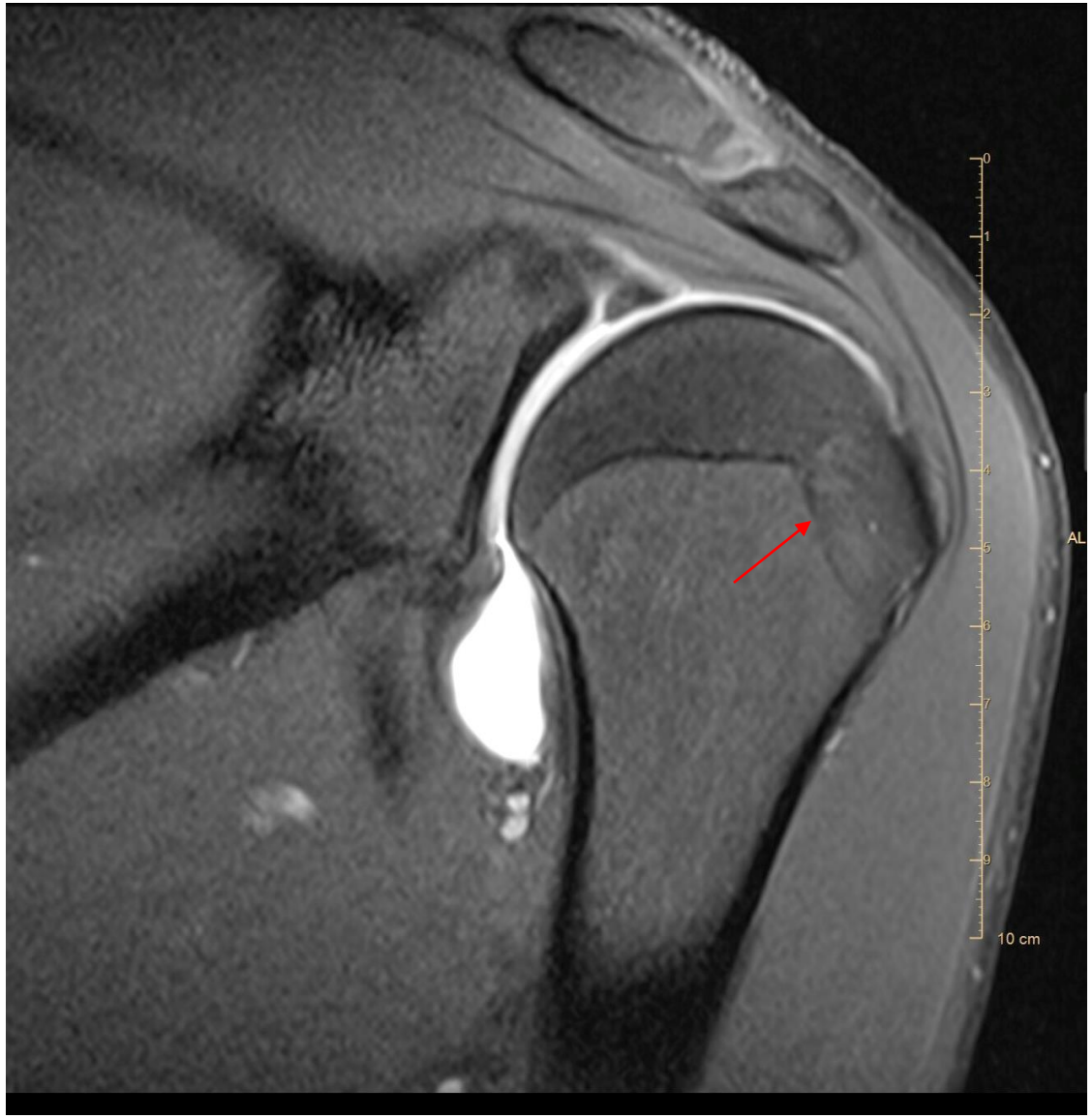

MRI (T1FS vs T2FS, Coronal)

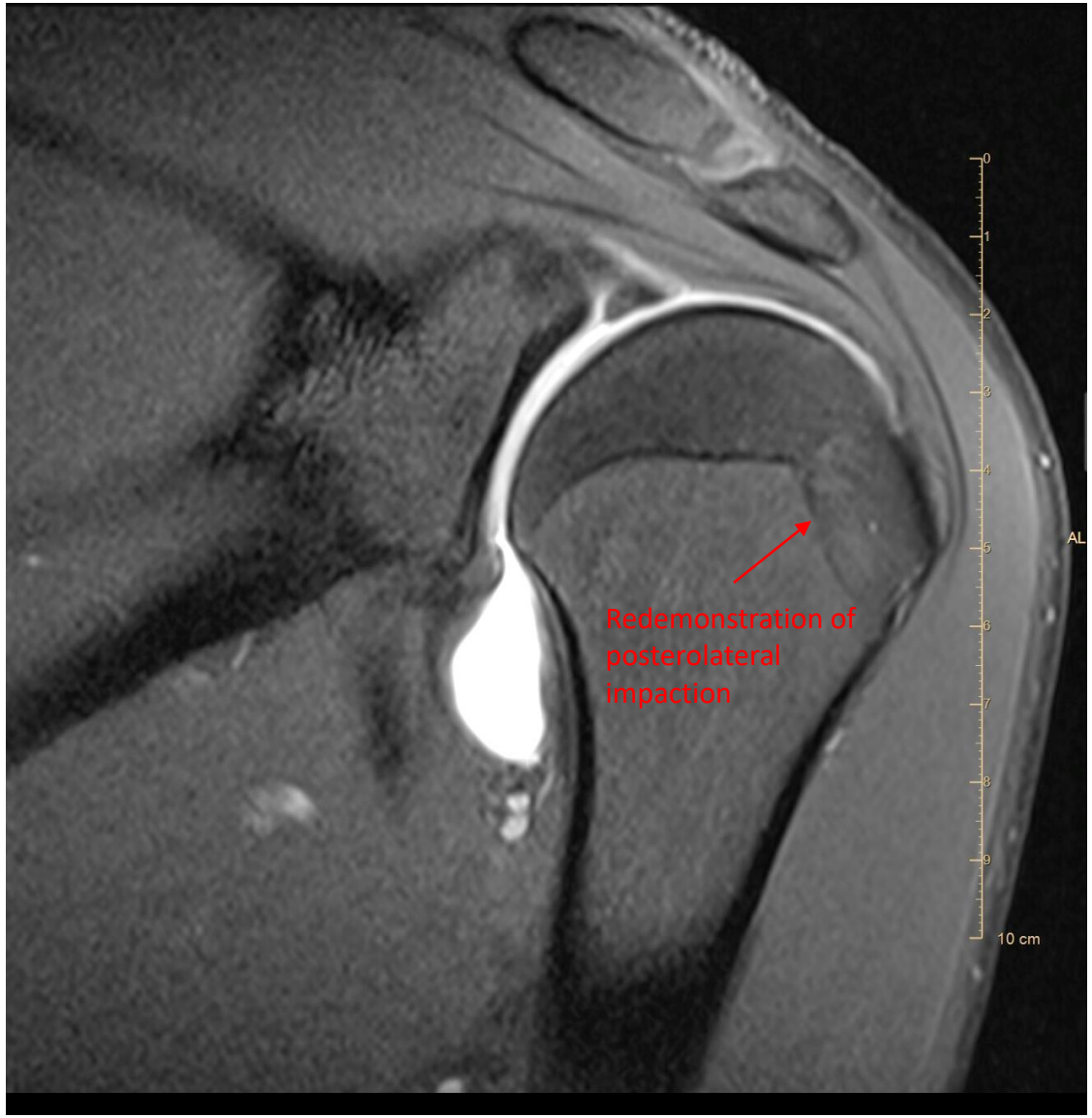

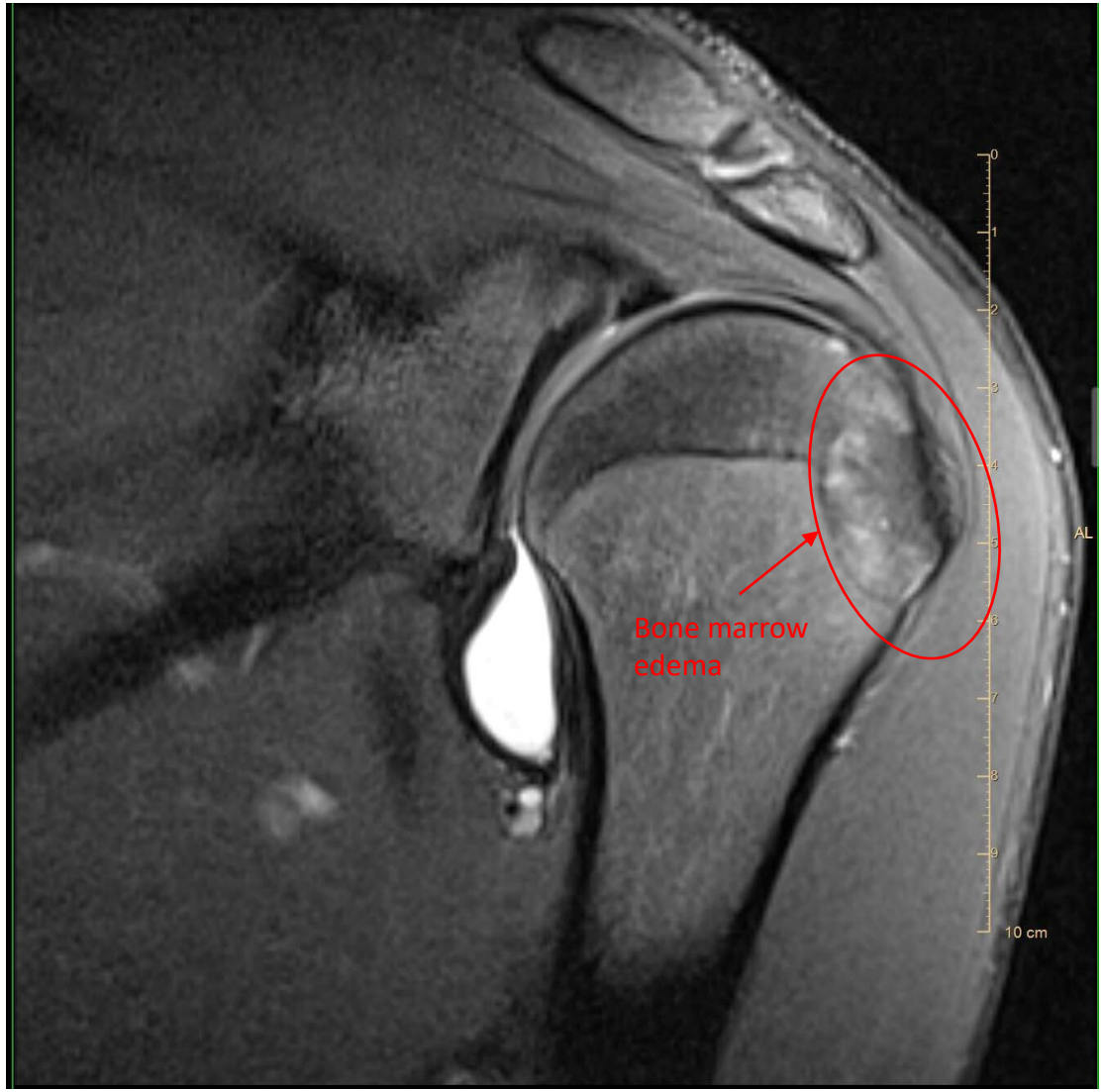

Shoulder dislocations: Anterior vs Posterior

- Anterior:
  - Most common
  - Usually results from forced abduction, external rotation, and extension
  - Can be further classified by where the humeral head lies
- Posterior:
  - Far less common
  - Usually results from a posteriorly directed force while the Humerus is in internal rotation and abduction.
  - Classically shows a “light bulb” sign, due to fixed internal rotation

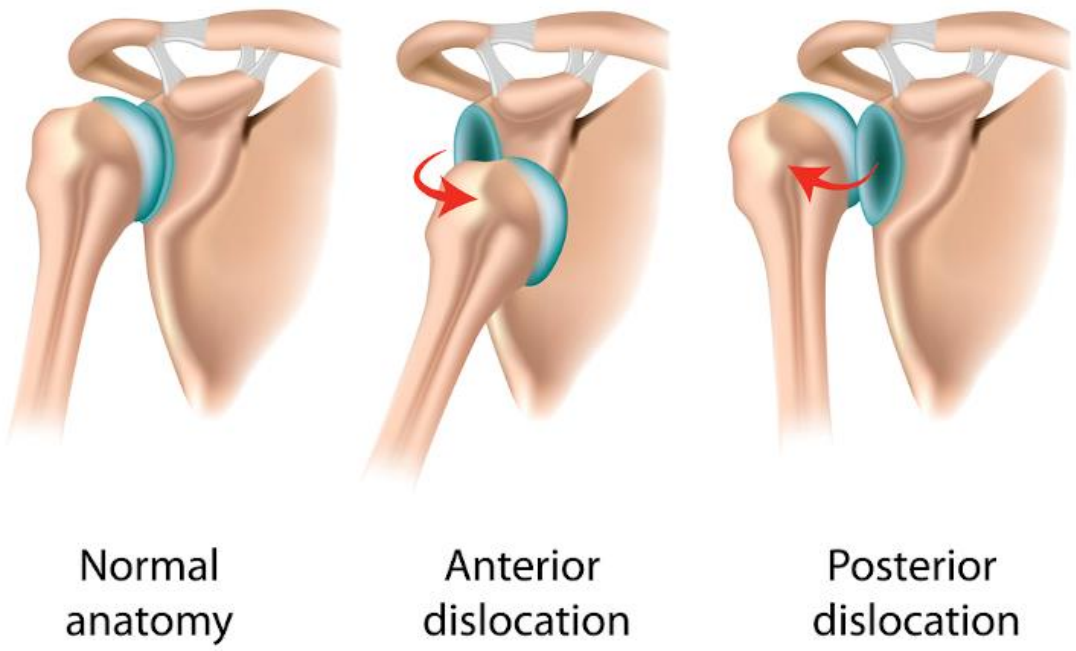

Image source: Boston Children’s Hospital

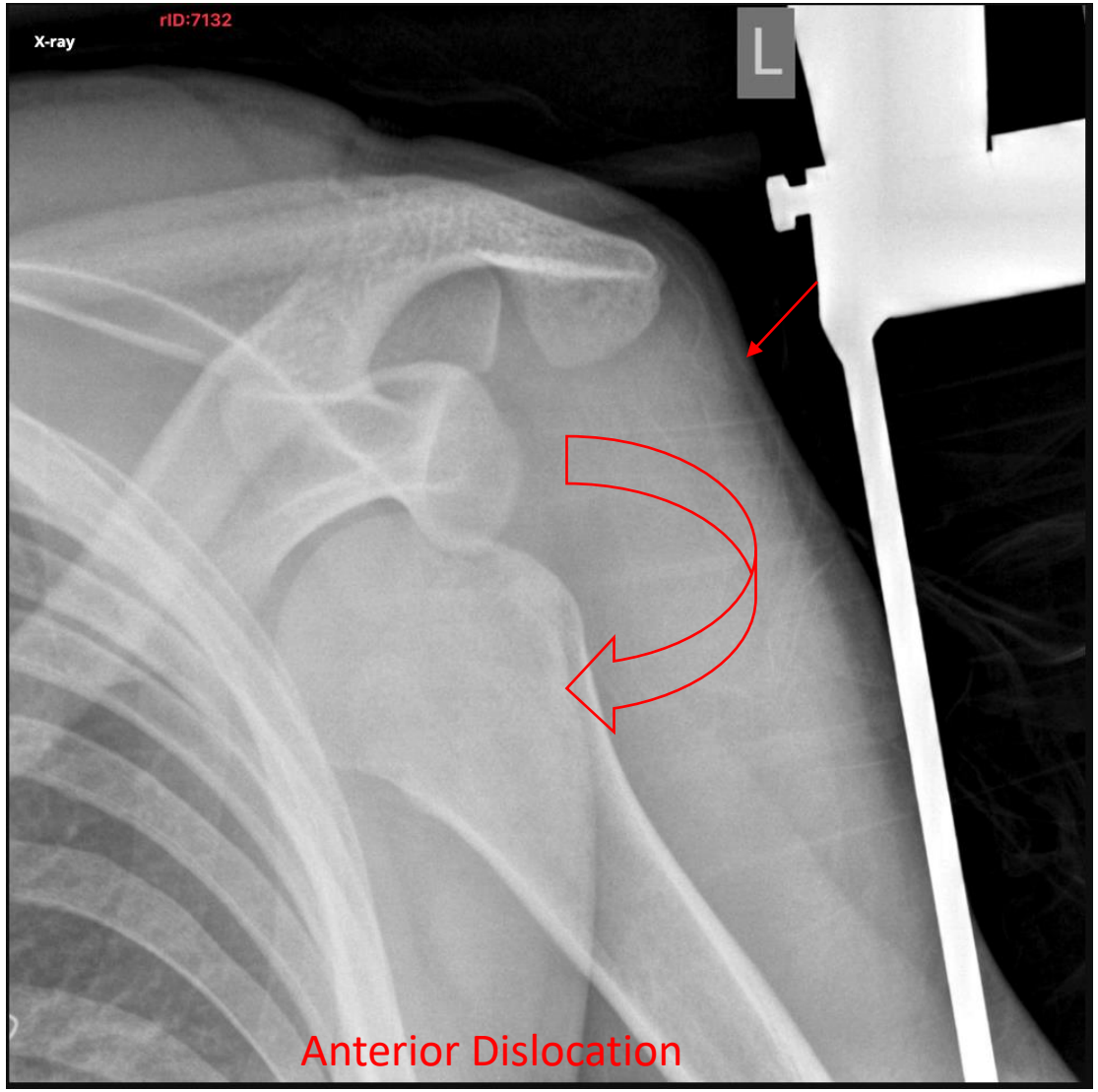
X-ray
rID:7132
L
Anterior Dislocation

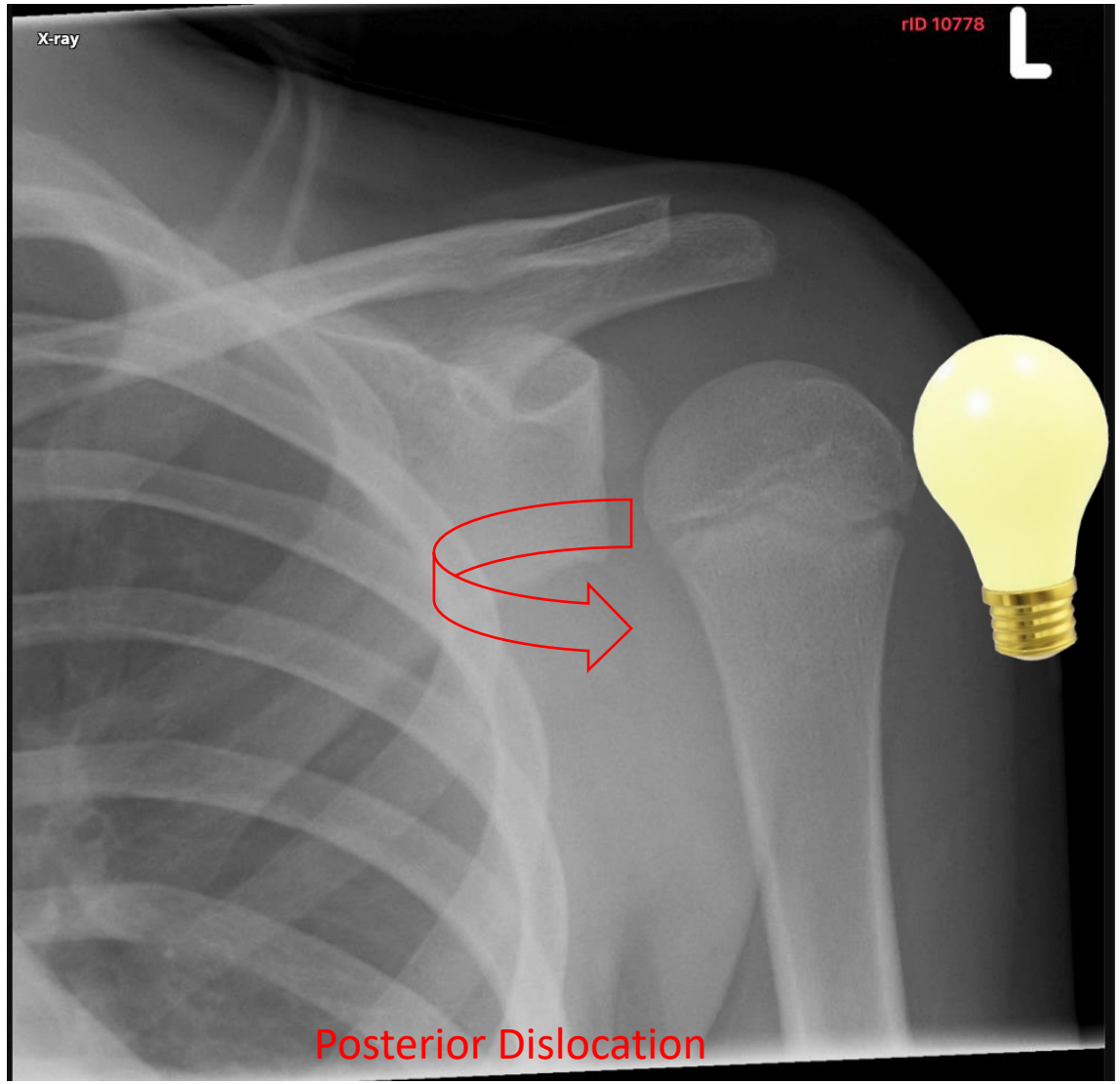
X-ray
rID 10778
L
Posterior Dislocation

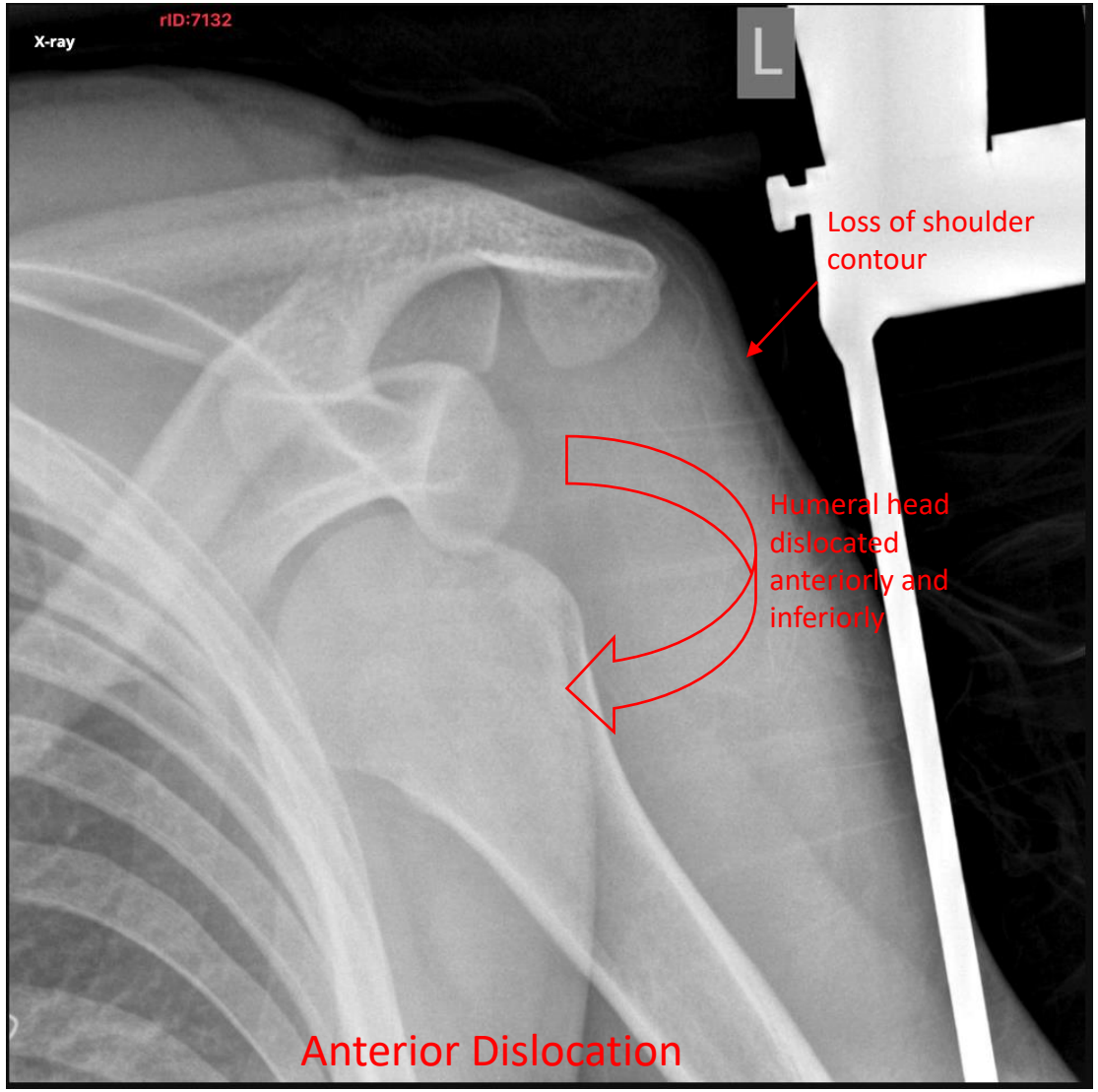
X-ray
rID:7132
L
Loss of shoulder contour
Humeral head dislocated anteriorly and inferiorly
Anterior Dislocation

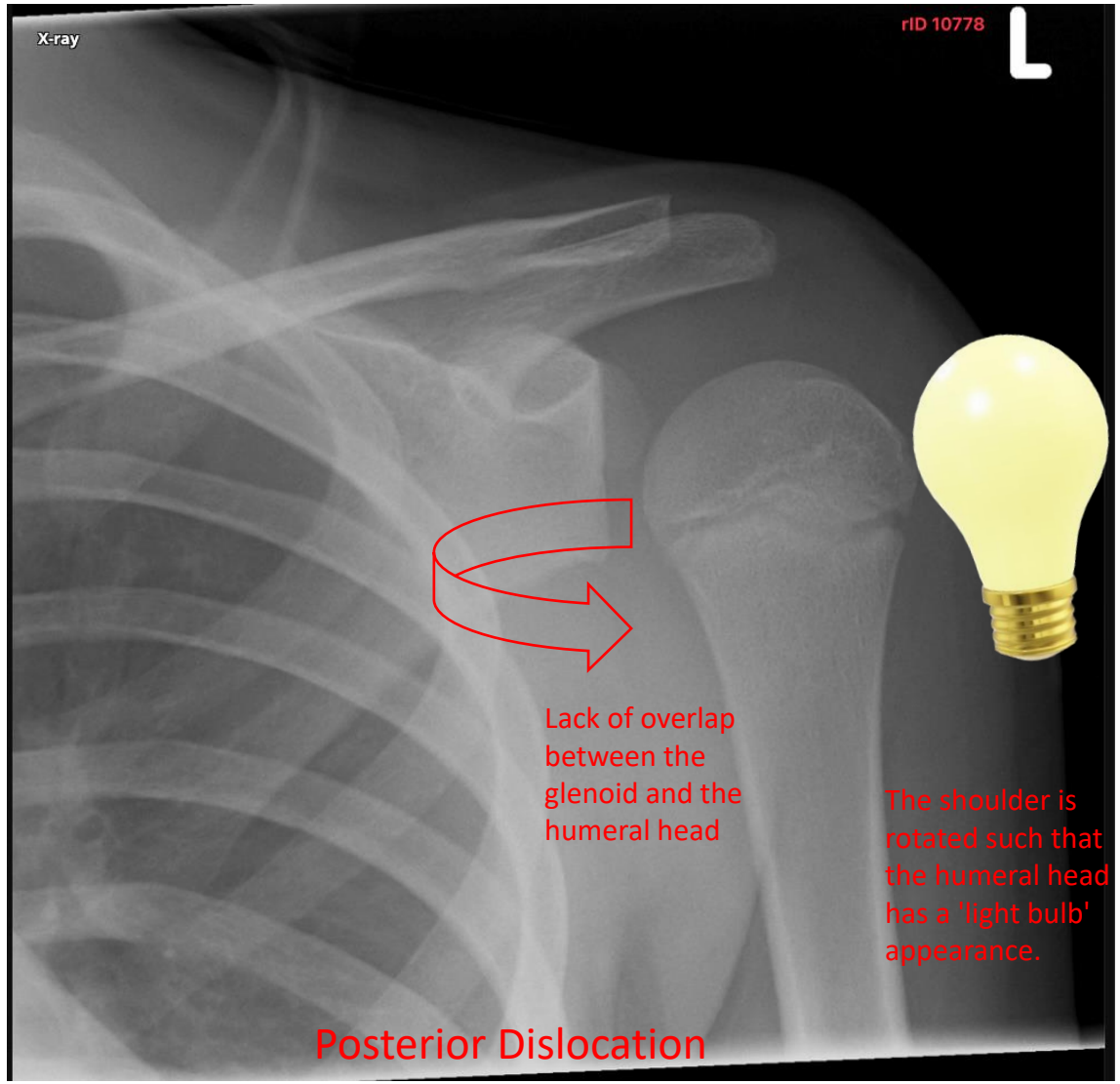
X-ray
rID 10778
L
Lack of overlap between the glenoid and the humeral head
The shoulder is rotated such that the humeral head has a 'light bulb' appearance.
Posterior Dislocation

Complications of Anterior Shoulder Dislocations

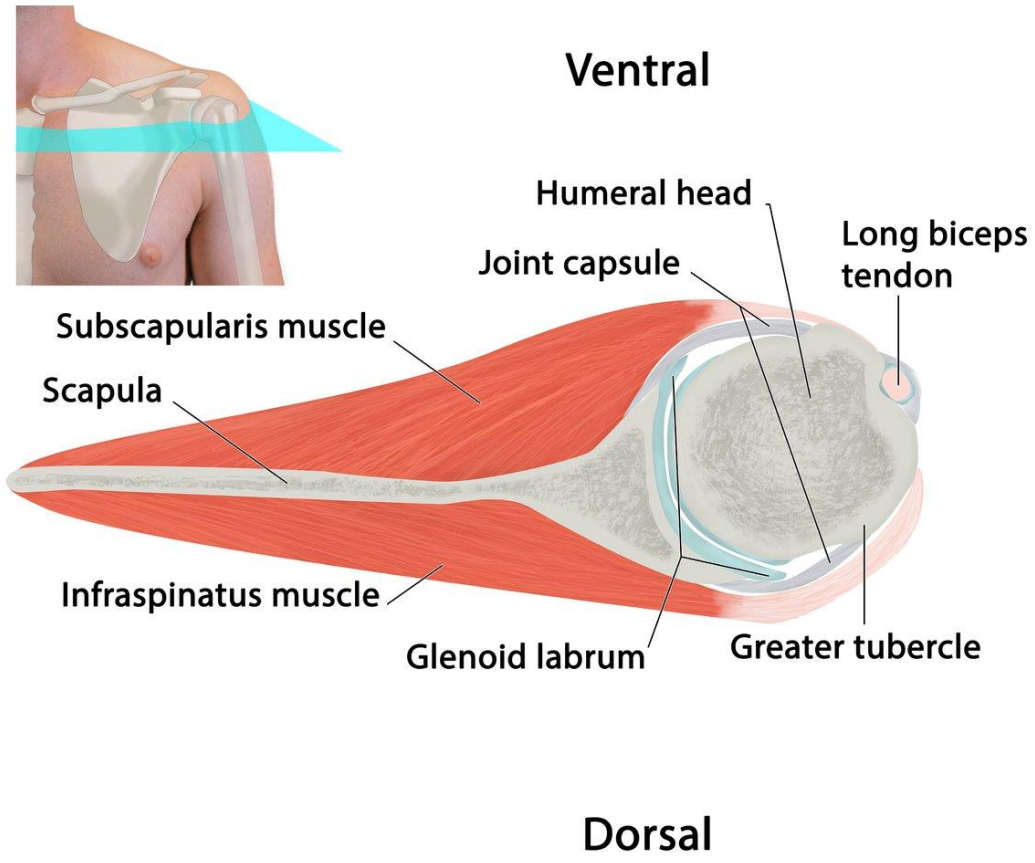

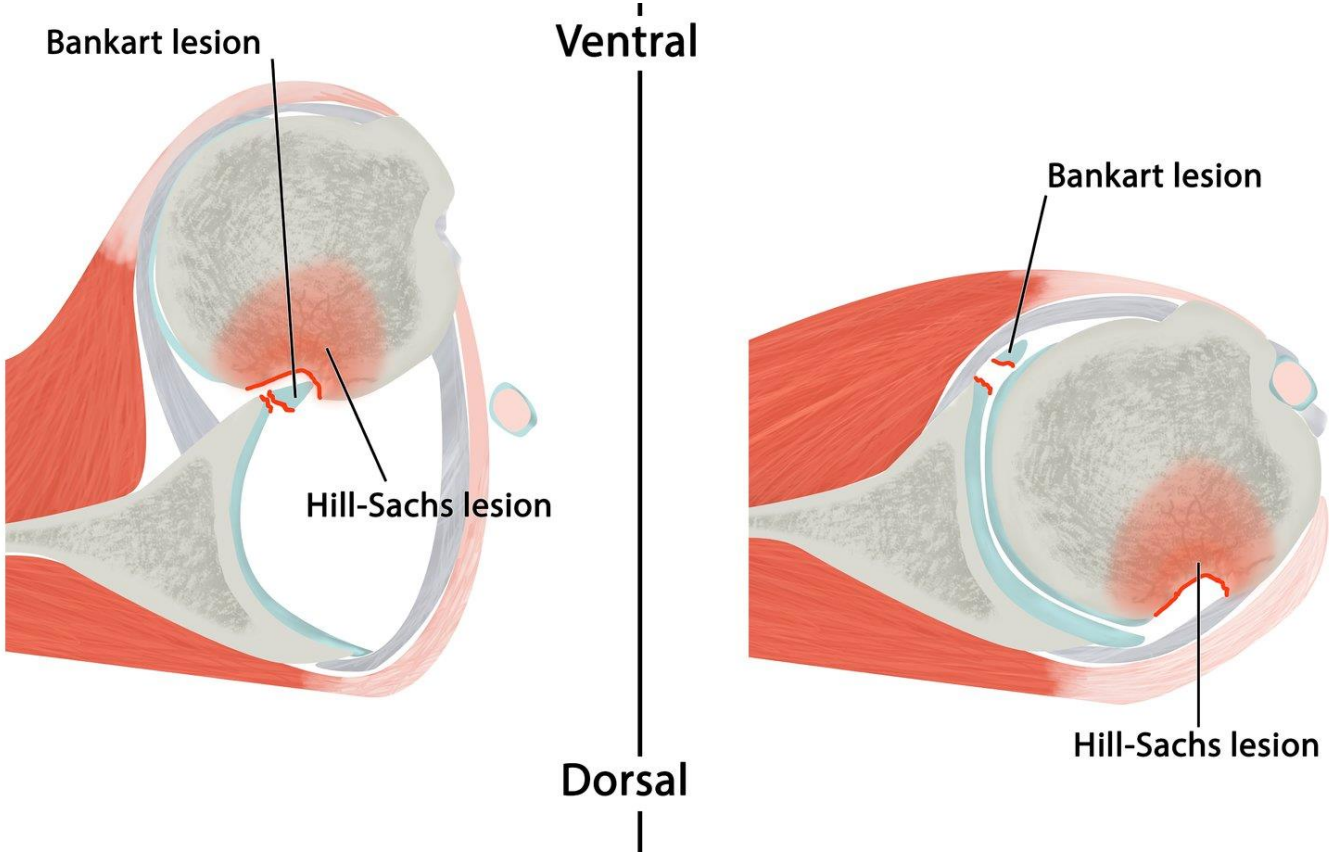

Image source: AMBOSS

Hill-Sachs Lesion

- Posterolateral humeral head depression fracture due to impaction of the anterior glenoid rim during an anterior dislocation
- Plain film will show a posterolateral wedge shape defect, MRI and CT will show smaller defects with bone marrow edema during acute injury.[1-2]

Modality	Sensitivity	Specificity
MR[2]	97%	91%
X-Ray[2]	84%	83%

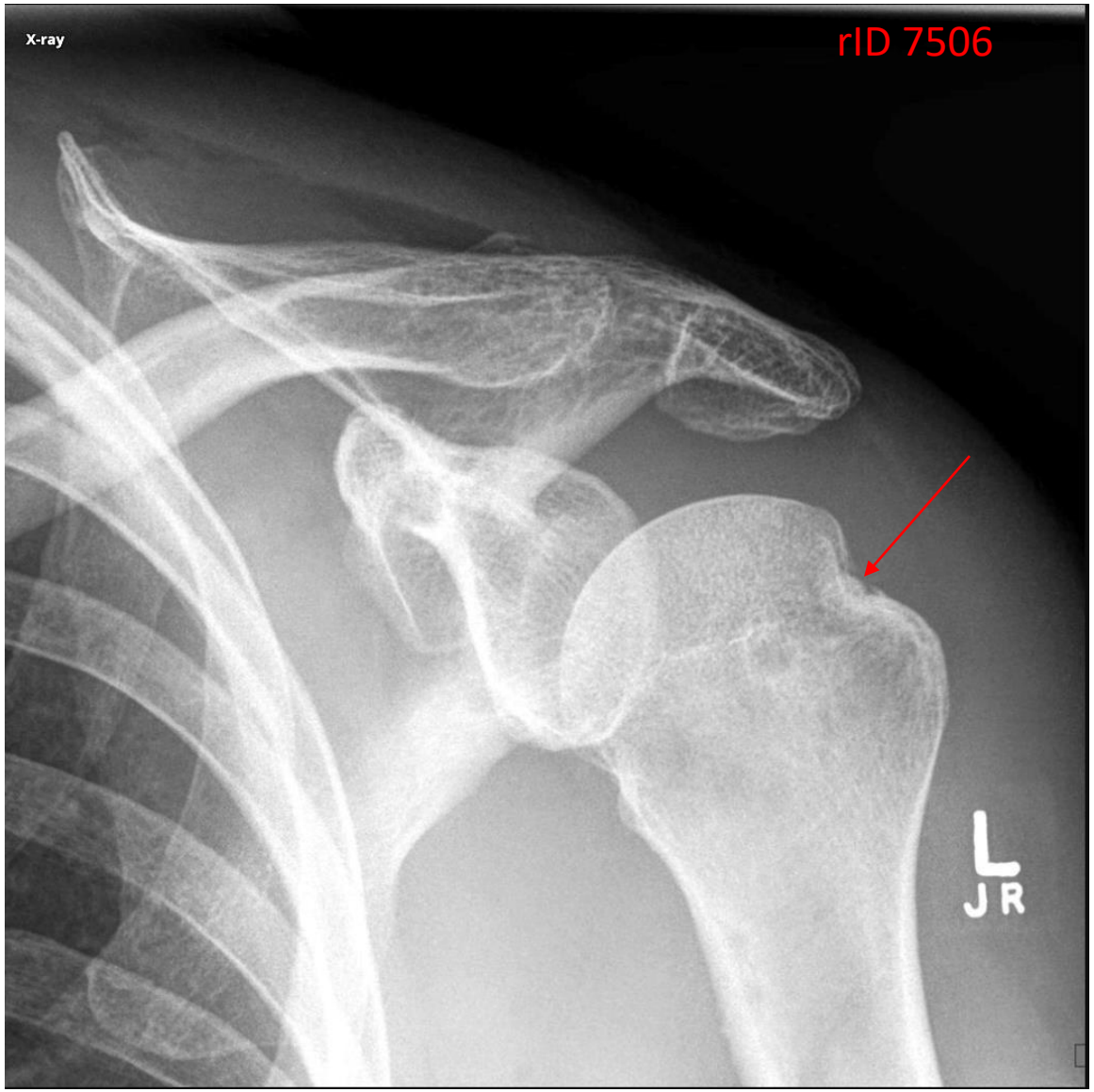
X-ray
rID 7506
L
J R

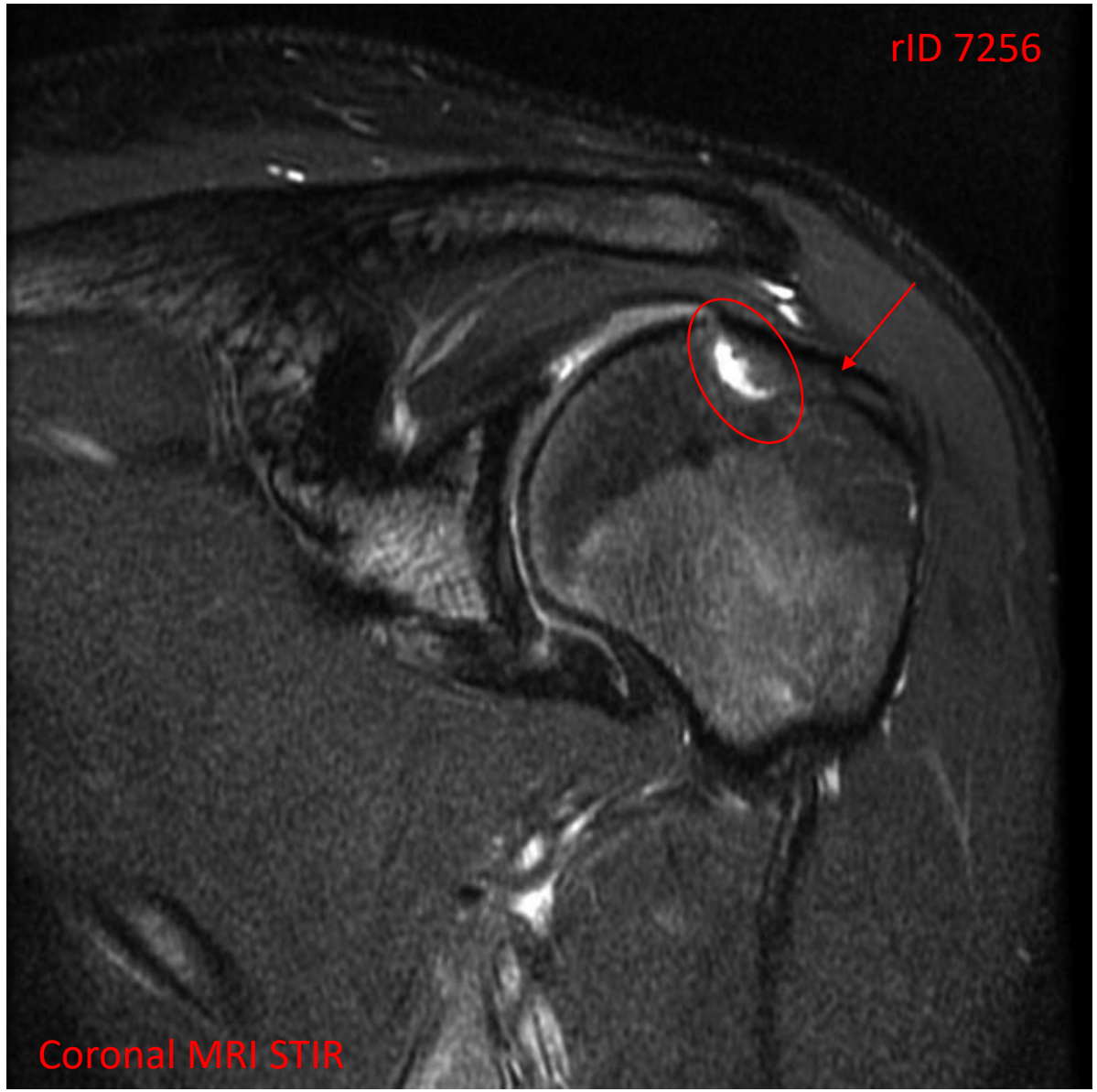
rID 7256
Coronal MRI STIR

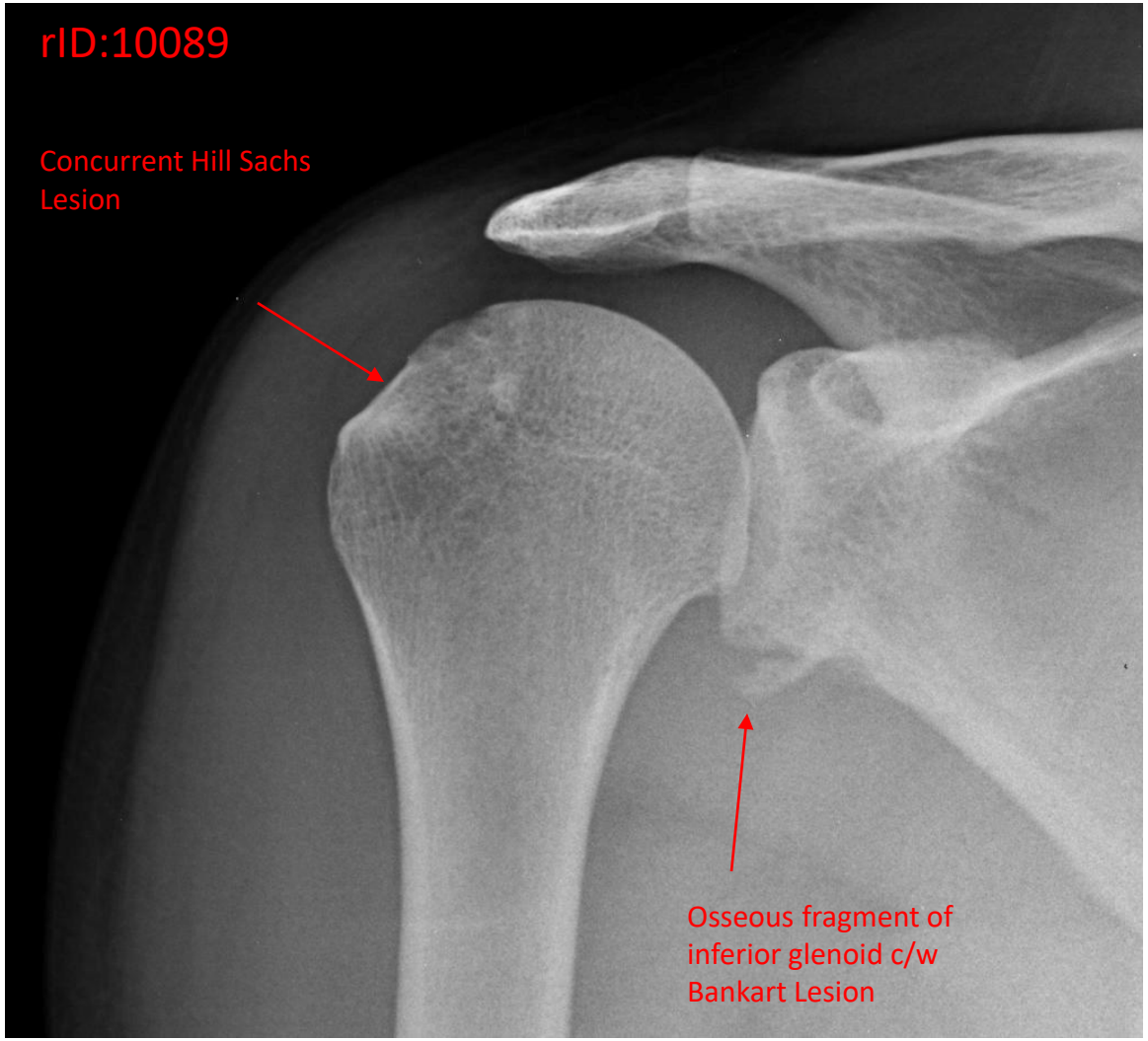
rID:10089
Concurrent Hill Sachs Lesion
Osseous fragment of inferior glenoid c/w Bankart Lesion

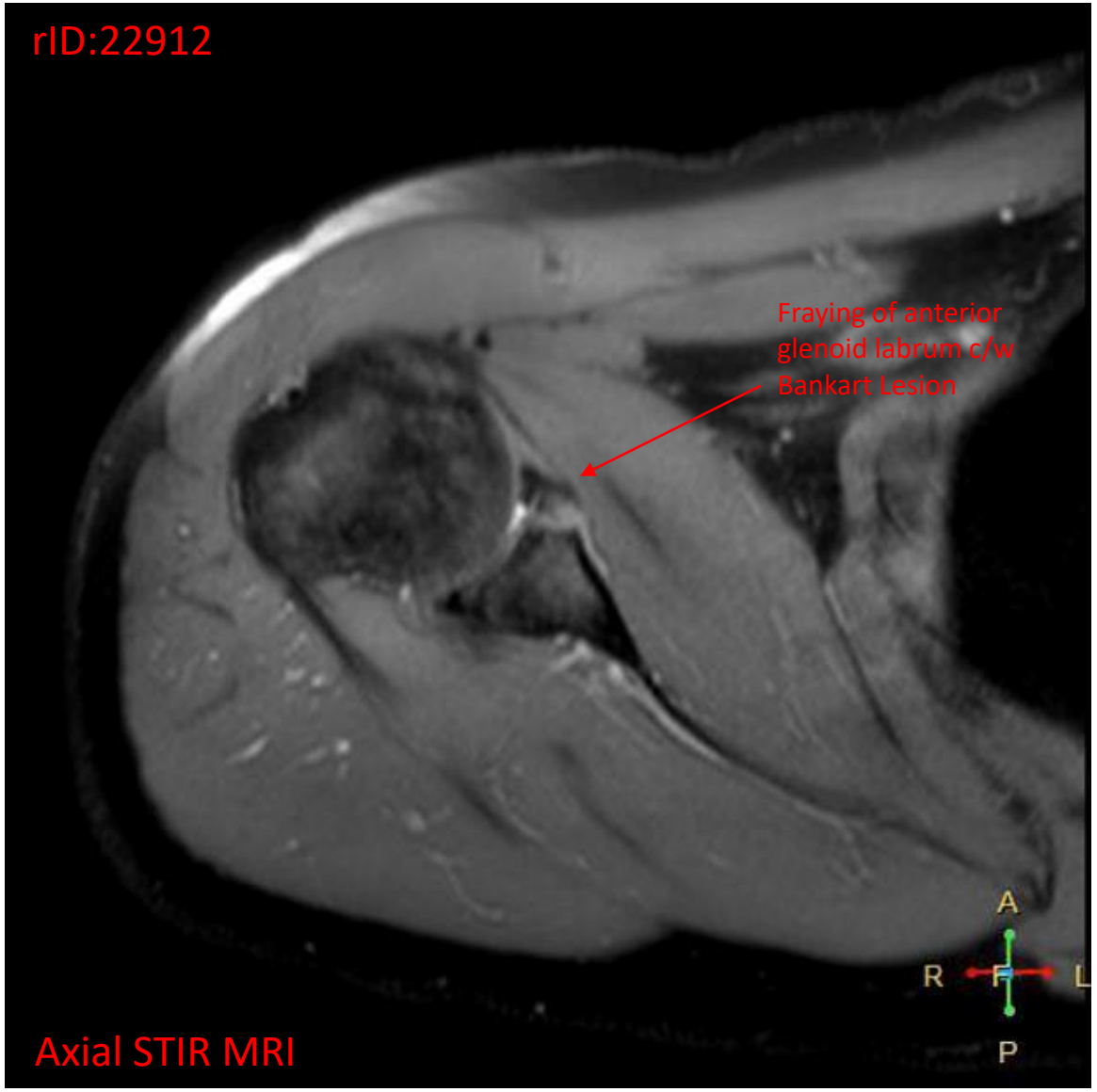
rID:22912
Fraying of anterior glenoid labrum c/w Bankart Lesion
A
R
L
P
Axial STIR MRI

Bankart Lesion

- Injury to the anteroinferior glenoid labrum during an anterior shoulder dislocation.
- Plain radiograph may show fracture of the anteroinferior aspect of the glenoid.[3]
- MRI will show frank displacement of the anterior labrum or can even show an abnormally small or absent labrum.[4]

Modality	Sensitivity	Specificity
MR[5]	90%	85%
X-Ray[6,*]	86%	73%

*As detected glenoid bone loss with two views

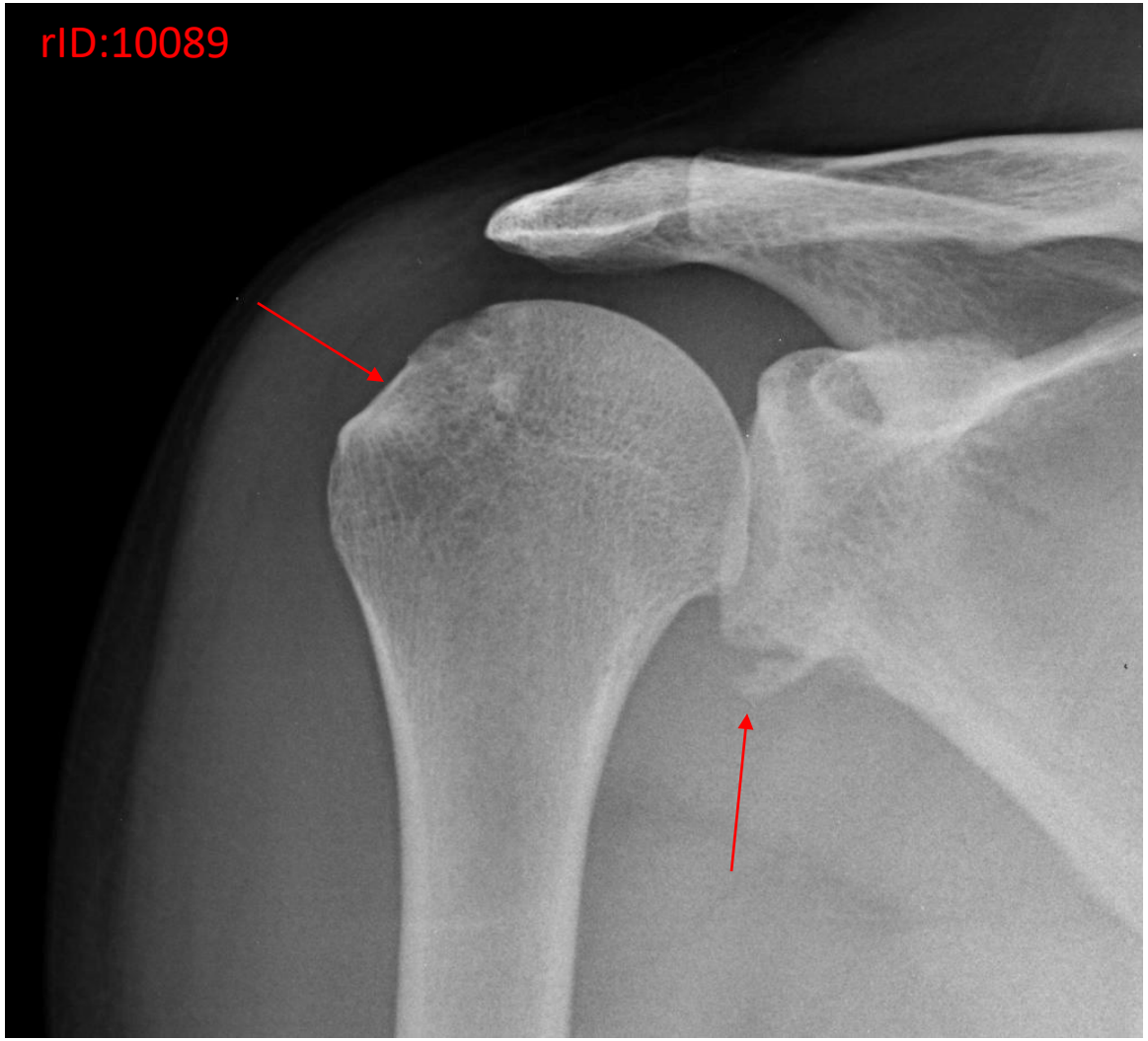
rID:10089

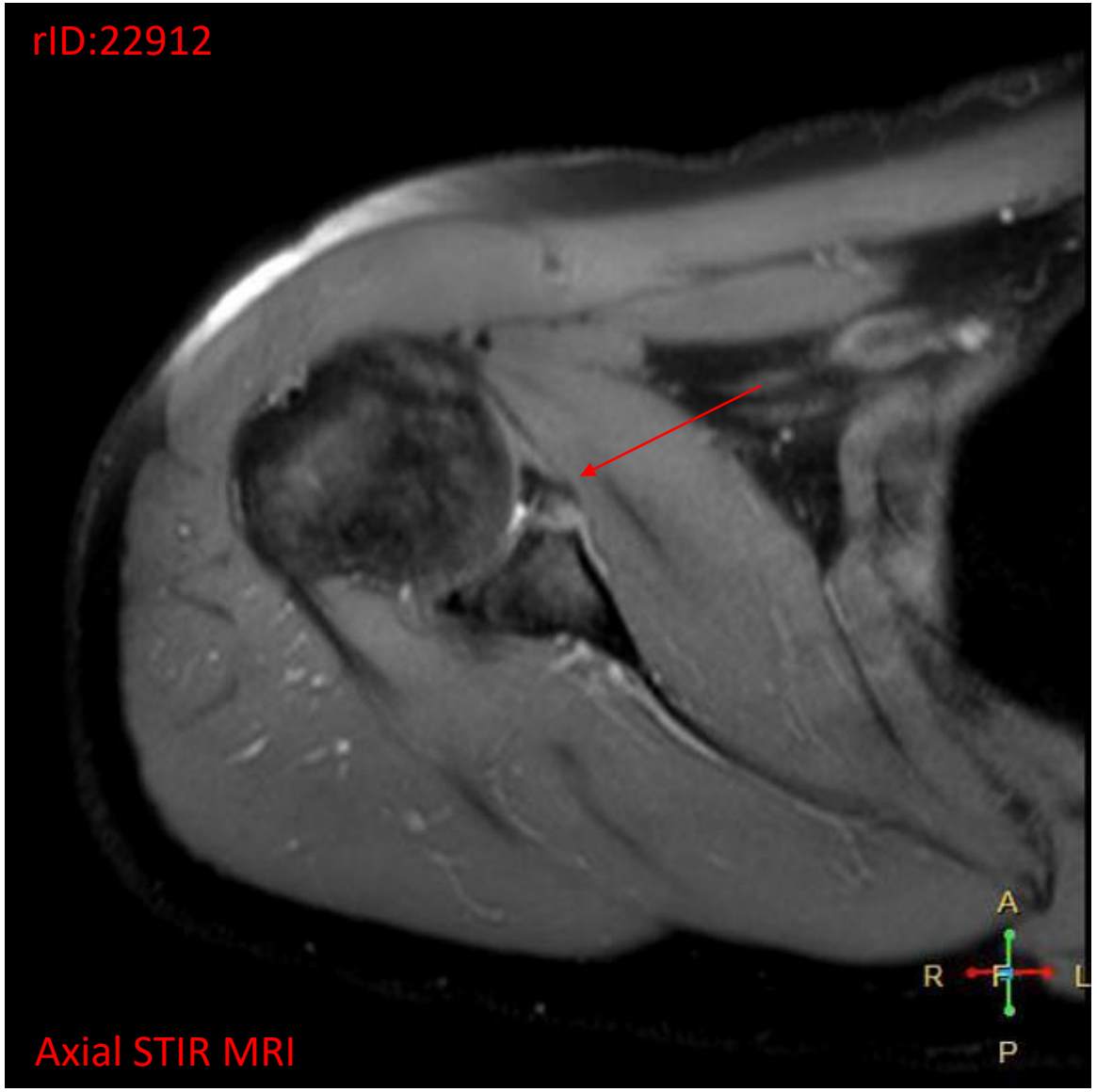
rID:22912
A
R
L
P
Axial STIR MRI

Appropriateness Criteria

Variant 1: **Traumatic shoulder pain. Any etiology. Initial imaging.**

Procedure	Appropriateness Category	Relative Radiation Level
Radiography shoulder	Usually Appropriate	☢
CT arthrography shoulder	Usually Not Appropriate	☢☢☢☢
CT shoulder with IV contrast	Usually Not Appropriate	☢☢☢
CT shoulder without and with IV contrast	Usually Not Appropriate	☢☢☢
CT shoulder without IV contrast	Usually Not Appropriate	☢☢☢
FDG-PET/CT skull base to mid-thigh	Usually Not Appropriate	☢☢☢☢
MR arthrography shoulder	Usually Not Appropriate	O
MRI shoulder without and with IV contrast	Usually Not Appropriate	O
MRI shoulder without IV contrast	Usually Not Appropriate	O
Bone scan shoulder	Usually Not Appropriate	☢☢☢
US shoulder	Usually Not Appropriate	O

Variant 6: **Traumatic shoulder pain. Radiographs normal. Physical examination and history consistent with dislocation event or instability. Next imaging study.**

Procedure	Appropriateness Category	Relative Radiation Level
MR arthrography shoulder	Usually Appropriate	O
MRI shoulder without IV contrast	Usually Appropriate	O
CT arthrography shoulder	May Be Appropriate	☢☢☢☢
CT shoulder without IV contrast	May Be Appropriate	☢☢☢
CT shoulder with IV contrast	Usually Not Appropriate	☢☢☢
CT shoulder without and with IV contrast	Usually Not Appropriate	☢☢☢
FDG-PET/CT skull base to mid-thigh	Usually Not Appropriate	☢☢☢☢
MRI shoulder without and with IV contrast	Usually Not Appropriate	O
Bone scan shoulder	Usually Not Appropriate	☢☢☢
US shoulder	Usually Not Appropriate	O

Appropriateness Category Name	Appropriateness Rating	Appropriateness Category Definition
Usually Appropriate	7, 8, or 9	The imaging procedure or treatment is indicated in the specified clinical scenarios at a favorable risk-benefit ratio for patients.
May Be Appropriate	4, 5, or 6	The imaging procedure or treatment may be indicated in the specified clinical scenarios as an alternative to imaging procedures or treatments with a more favorable risk-benefit ratio, or the risk-benefit ratio for patients is equivocal.
May Be Appropriate (Disagreement)	5	The individual ratings are too dispersed from the panel median. The different label provides transparency regarding the panel's recommendation. "May be appropriate" is the rating category and a rating of 5 is assigned.
Usually Not Appropriate	1, 2, or 3	The imaging procedure or treatment is unlikely to be indicated in the specified clinical scenarios, or the risk-benefit ratio for patients is likely to be unfavorable.

Relative Radiation Level Designations		
Relative Radiation Level*	Adult Effective Dose Estimate Range	Pediatric Effective Dose Estimate Range
O	0 mSv	0 mSv
☢	<0.1 mSv	<0.03 mSv
☢☢	0.1-1 mSv	0.03-0.3 mSv
☢☢☢	1-10 mSv	0.3-3 mSv
☢☢☢☢	10-30 mSv	3-10 mSv
☢☢☢☢☢	30-100 mSv	10-30 mSv

UNC SCHOOL OF MEDICINE Radiology

Patient treatment and outcome

- Hill Sachs lesion confirmed, no osseous Bankart lesion.
- Patient already at great ROM at time of MRI
  - No indication for surgery
- Following up with physical therapy to prevent future dislocations

UNC Top Three Key Take Aways

1. START WITH A TWO VW SHOULDER PLAIN FILM IN THE SETTING OF A TRAUMA
   Confirm the presence of a dislocation and more obvious Glenoid fractures

2. IF THERE IS PERSISTENT PAIN IN THE SETTING OF AN ANTERIOR DISLOCATION, CONSIDER A HILL-SACHS AND/OR A BANKART LESION
   MR Arthrography is the preferred modality for peds patients

3. IF YOU FIND HILL-SACHS LESION, LOOK CAREFULLY FOR CONCURRENT BANKART LESION
   The mechanism of injury makes both lesions occurring very likely

References

1.Vande Berg B & Omoumi P. Dislocation of the Shoulder Joint – Radiographic Analysis of Osseous Abnormalities. Journal of the Belgian Society of Radiology. 2016;100(1):89. doi:10.5334/jbr-btr.1210

2. Workman T, Burkhard T, Resnick D et al. Hill-Sachs Lesion: Comparison of Detection with MR Imaging, Radiography, and Arthroscopy. Radiology. 1992;185(3):847-52. doi:10.1148/radiology.185.3.1438774 – Pubmed

3. Emergency Radiology. Springer. (2007) ISBN:3540689087.

4. Jana M, Srivastava D, Sharma R et al. Spectrum of Magnetic Resonance Imaging Findings in Clinical Glenohumeral Instability. Indian J Radiol Imaging. 2011;21(2):98-106. doi:10.4103/0971-3026.82284 – Pubmed

5. Iqbal MS, Sharma Y, Sud AD, Sharma P, Magar MT. Accuracy of magnetic resonance imaging of the shoulder in evaluation of anterior shoulder instability. *Journal of Marine Medical Society*. 2019;21(1):15. doi:10.4103/jmms.jmms_7_19

6. Delage Royle A, Balg F, Bouliane MJ, et al. Indication for Computed Tomography Scan in Shoulder Instability: Sensitivity and Specificity of Standard Radiographs to Predict Bone Defects After Traumatic Anterior Glenohumeral Instability. Orthopaedic Journal of Sports Medicine. October 2017. doi:10.1177/2325967117733660