Original Investigation | Health Informatics

Deep Learning–Assisted Diagnosis of Cerebral Aneurysms Using the HeadXNet Model

Allison Park, BA; Chris Chute, BS; Pranav Rajpurkar, MS; Joe Lou; Robyn L. Ball, PhD; Katie Shpanskaya, BS; Rashad Jabarkheel, BS; Lily H. Kim, BS; Emily McKenna, BS; Joe Tseng, MD; Jason Ni, MD; Fidaa Wishah, MD; Fred Wittber, MD; David S. Hong, MD; Thomas J. Wilson, MD; Safwan Halabi, MD; Sanjay Basu, MD, PhD; Bhavik N. Patel, MD, MBA; Matthew P. Lungren, MD, MPH; Andrew Y. Ng, PhD; Kristen W. Yeom, MD

Julia Kuno

May 20, 2022

UNC SCHOOL OF MEDICINE Radiology

Learning objectives

By the end of this journal club, participants will be able to:

1. Describe unruptured intracranial aneurysms and the primary imaging modality, CT angiography
2. Be familiar with deep learning and other applications of artificial intelligence in imaging
3. Understand future directions of AI tools

Module Outline

I. <u>Case</u>
II. Background
III. Article Overview
IV. Clinical Questions
V. Key Points

Case presentation

A 55-year-old female with the ”worst headache of her life” for the past hour. She coincidentally had a CTA done the week before as part of a research study, which is analyzed while she goes to head CT. Sagittal projection is shown below:

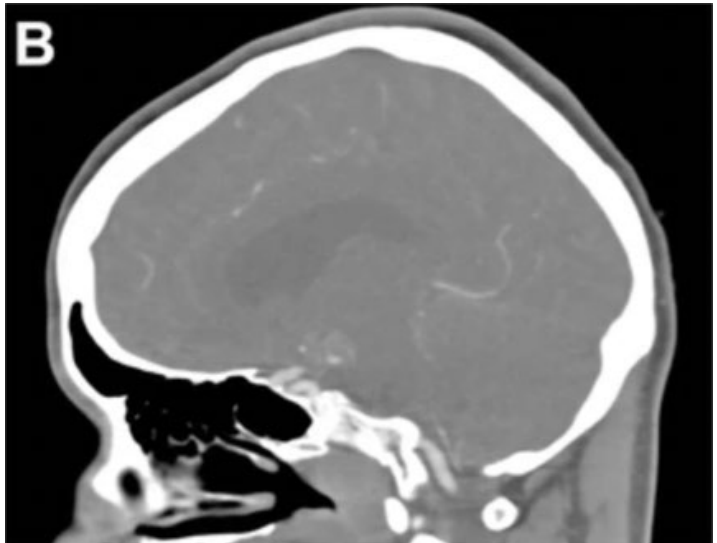

UNC SCHOOL OF MEDICINE Radiology

Case imaging

Head CT demonstrates the following:

How would you describe the imaging and what is your primary diagnosis?

Case imaging

Head CT demonstrates the following:

Correct! Diffuse hyperdense subarachnoid hemorrhage

Case imaging

Head CT demonstrates the following:

Thankfully, she is sent to surgery, where a small ruptured aneurysm is discovered at the branchpoint of posterior communicating and internal carotid artery, and successfully treated with clipping

Case questions

1. What is the primary imaging modality of an active subarachnoid hemorrhage vs unruptured intracranial aneurysm?
2. How could treatment have changed had CTA been able to identify the aneurysm prior to rupture?
3. How could these imaging modalities be improved?

Module Outline

I. Case

II. **Background**

III. Article Overview

IV. Clinical Questions

V. Key Points

Unruptured Intracranial Aneurysms

- Dilation/outpouching at branching arteries
- Most often saccular (berry) aneurysms
- 3-5% adult population, between 4th and 6th decade
- Asymptomatic if ≤7 mm
- If rupture → subarachnoid hemorrhage

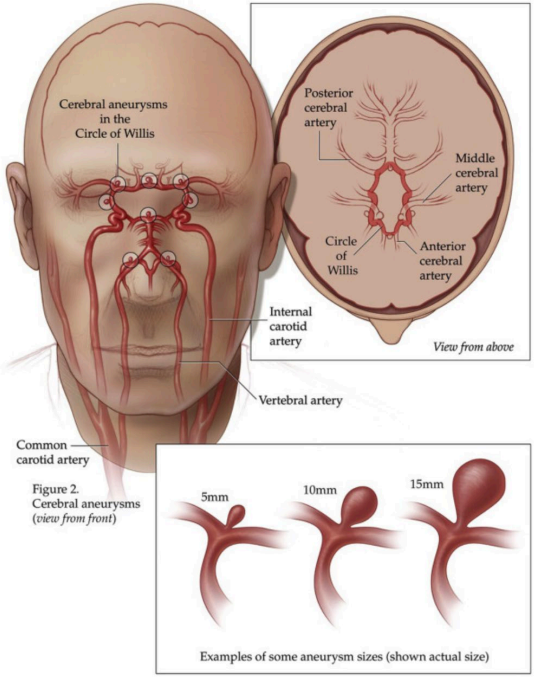

CTA

- IV contrast in arterial phase
- Used for aneurysms, AVM, thrombosis, dissection, stroke prior to thrombectomy
- Can identify aneurysms ≥3 mm
- Interpretation can be time-consuming
- Low interrater agreement

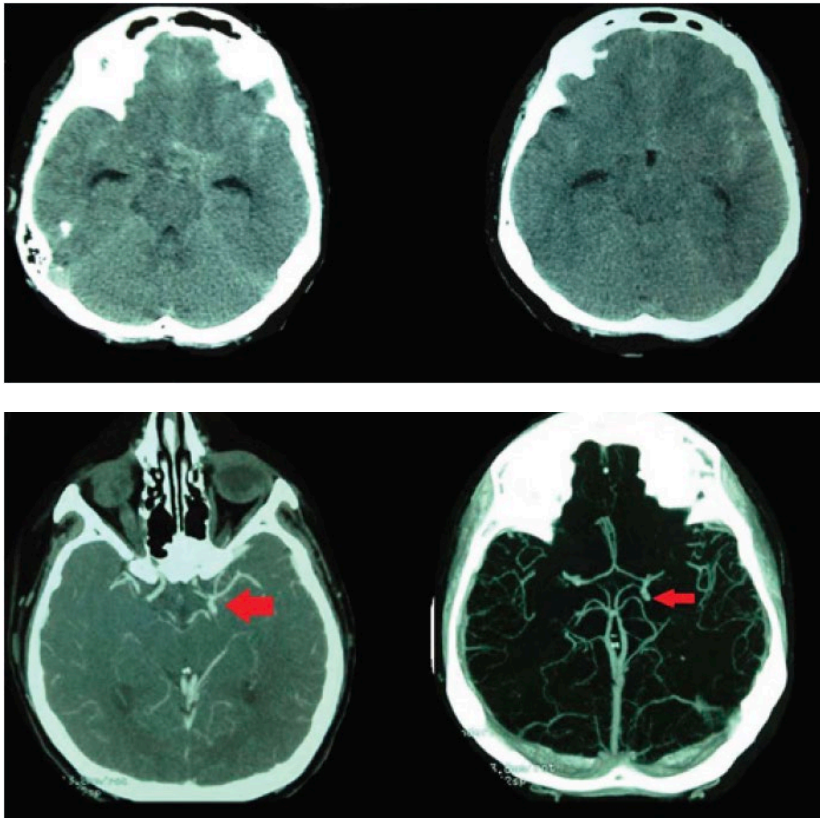

Deep Learning and HeadXNet

- 3-dimensional convolutional neural network (CNN), machine-learning method with high performance at image recognition
- Used 611 CT scans with clinically significant aneurysms to train
- Highlights abnormal areas in red, which can be toggled on and off

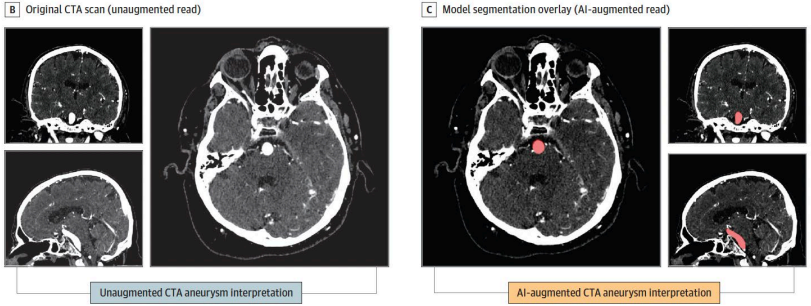

UNC SCHOOL OF MEDICINE Radiology

Module Outline

I. Case

II. Background

III. <u>Article Overview</u>

IV. Clinical Questions

V. Key Points

Article Specifics

I. Purpose: to evaluate whether deep learning can be used to improve clinical performance in CTA interpretation of intracranial aneurysms

II. Journal: JAMA Network Open

III. Study type: crossover study

IV. # cases: 115 examinations

V. Data: presence or absence of at least 1 clinically significant aneurysm

Study cohort

- Out of 9455 CTA's of head or head and neck performed at Stanford University Medical Center between Jan 3, 2003 and May 31, 2017, excluded:
  - Those with parenchymal hemorrhage, SAH, pseudoaneurysm, AVM, ischemic stroke, and vascular findings
  - Those with surgical clips, coils, catheters, other surgical hardware
  - Those with injuries that were a result of trauma or degraded by motion
- Included:
  - Those with non-ruptured, clinically significant (≥3 mm) aneurysms

Study cohort (cont.)

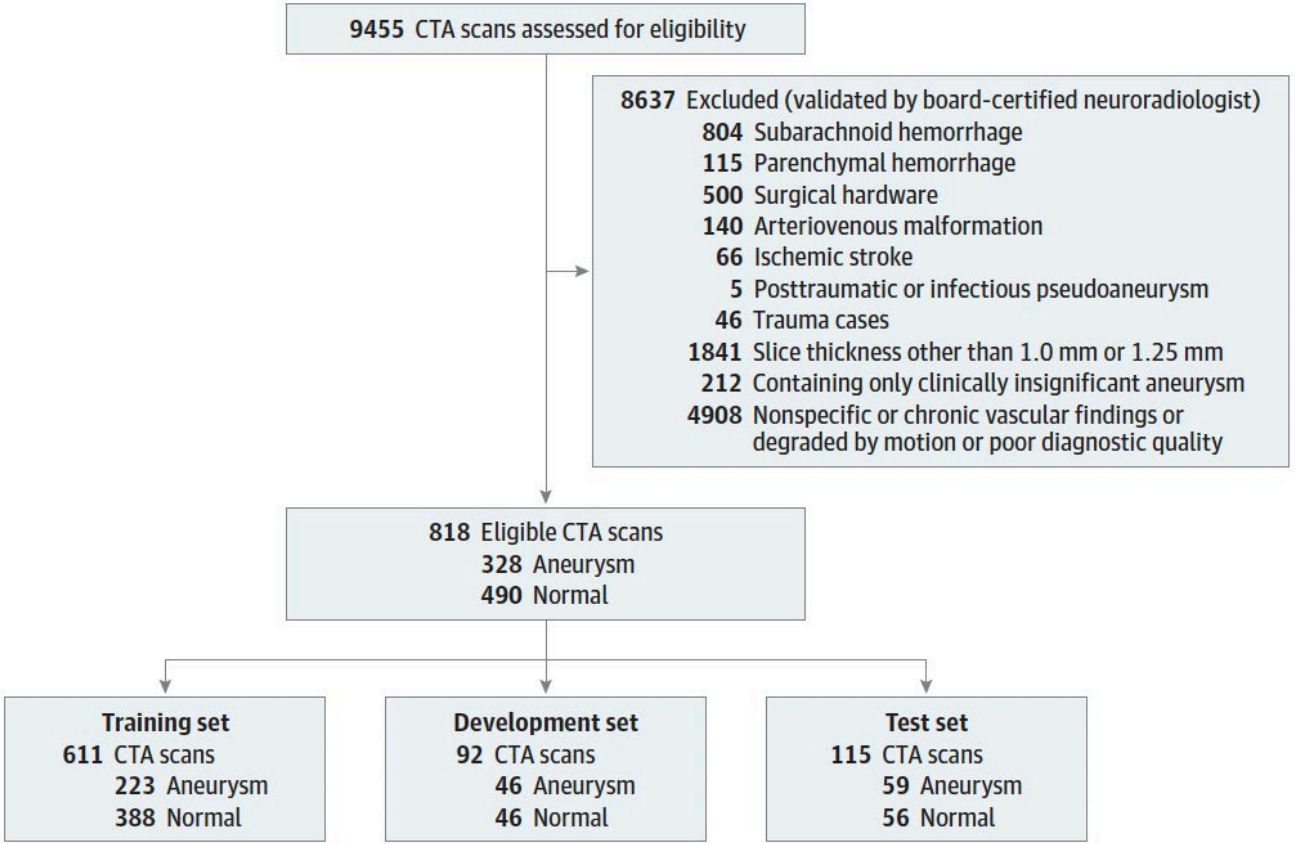

Materials and Methods

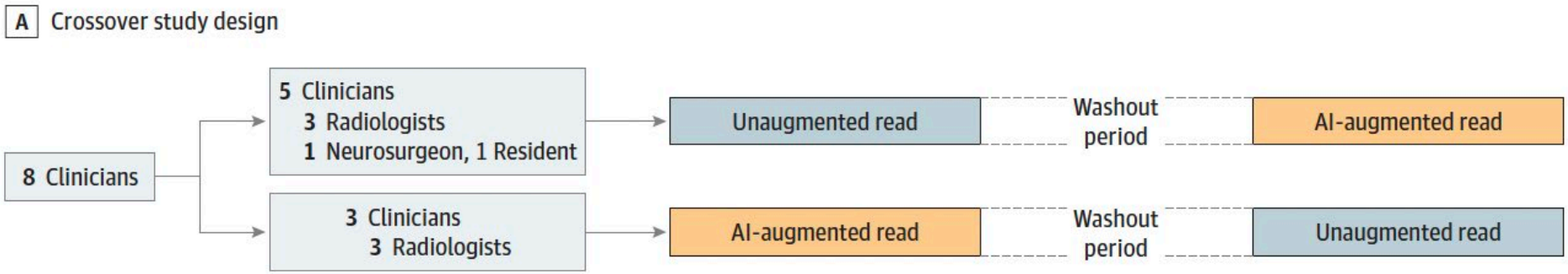

Results

Table. Clinician Performance Metrics With and Without Augmentation

Metric	Microaverage (95% CI)		Mean Increase (95% CI)	*P* Value	
	Without Augmentation	With Augmentation		Unadjusted	Adjusted[a]
Sensitivity	0.831 (0.794 to 0.862)	0.890 (0.858 to 0.915)	0.059 (0.028 to 0.091)	.001	.01
Specificity	0.960 (0.937 to 0.974)	0.975 (0.957 to 0.986)	0.016 (−0.010 to 0.041)	.10	.16
Accuracy	0.893 (0.782 to 0.912)	0.932 (0.913 to 0.946)	0.038 (0.014 to 0.062)	.004	.02

[a] *P* values were adjusted for multiple hypothesis testing using the Benjamini-Hochberg correction.

Results (cont.)

Figure 3. Change in Individual Clinicians' Performance Metric

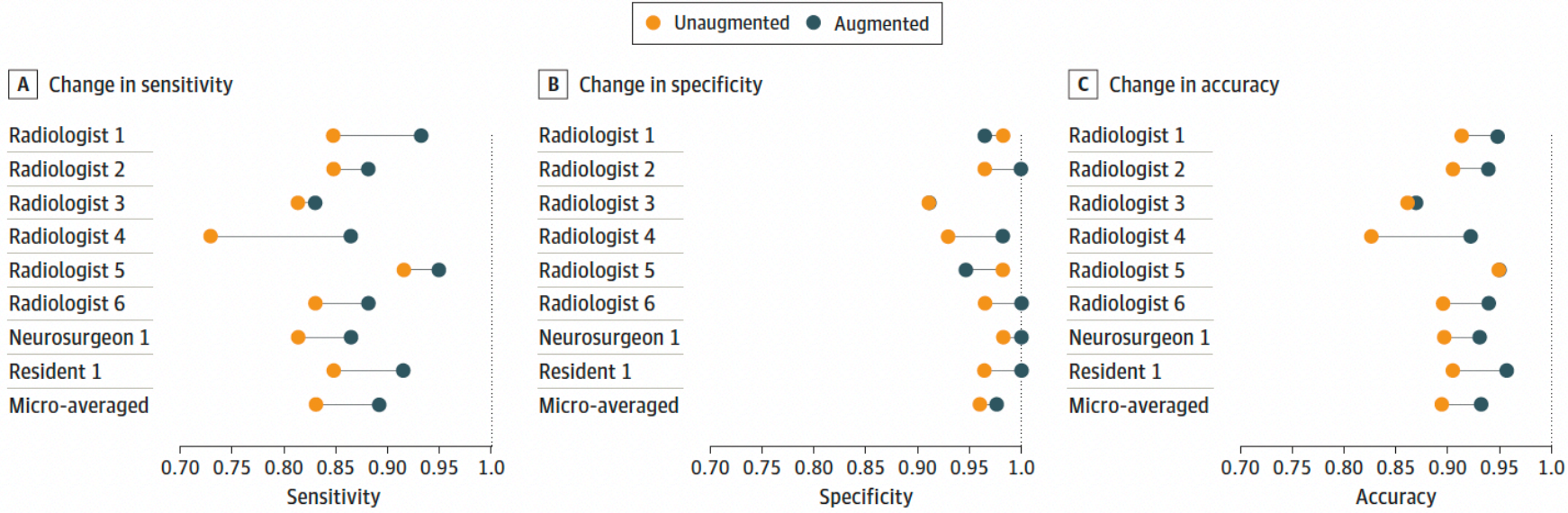

Horizontal lines depict the change in performance metric for each clinician with and without model augmentation. The orange dot represents performance without model, and the blue dot represents performance with model augmentation.

Discussion

- Statistically significant increases in mean sensitivity, accuracy, interrater agreement
- No statistical change in specificity and time to diagnosis
- Other tools include:
  - Bone subtraction
  - 3-D rendering of intracranial vasculature
  - 2-D CNNs on CT
  - Deep learning in MRA

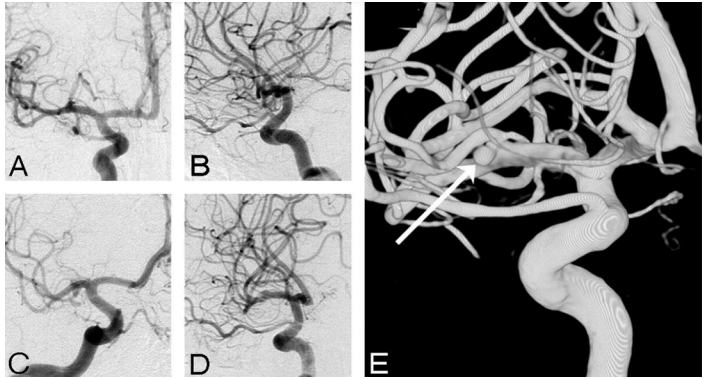

Limitations

- Only non-ruptured aneurysms
- Recall exclusion criteria…
  - Those with parenchymal hemorrhage, SAH, pseudoaneurysm, AVM, ischemic stroke, and vascular findings
  - Those with surgical clips, coils, catheters, other surgical hardware
  - Those with injuries that were a result of trauma or degraded by motion
- Bias inherent to task
- Single academic institution

Module Outline

I. Case

II. Background

III. Article Overview

IV. <u>Clinical Questions</u>

V. <u>Key Points</u>

Clinical questions

- Could this deep learning program have applications apart from identifying unruptured intracranial aneurysms?
- How has imaging changed/adapted advanced diagnostic tools in other subspecialties in recent years?
- In the setting of unruptured intracranial aneurysms and other asymptomatic, incidental findings, how should we establish a threshold of imaging?

Key points

- Unruptured intracranial aneurysms often go undiagnosed, especially if small and asymptomatic
- CT Angiography is the primary imaging modality in identifying unruptured intracranial aneurysms
- Artificial intelligence tools can be helpful in augmenting diagnostic capabilities of CTA

References

I. Park, A., Chute, C., Rajpurkar, P., Lou, J., Ball, R. L., Shpanskaya, K., Jabarkheel, R., Kim, L. H., McKenna, E., Tseng, J., Ni, J., Wishah, F., Wittber, F., Hong, D. S., Wilson, T. J., Halabi, S., Basu, S., Patel, B. N., Lungren, M. P., Ng, A. Y., … Yeom, K. W. (2019). Deep Learning-Assisted Diagnosis of Cerebral Aneurysms Using the HeadXNet Model. *JAMA network open*, *2*(6), e195600. https://doi.org/10.1001/jamanetworkopen.2019.5600

II. Etminan, N., & Rinkel, G. J. (2016). Unruptured intracranial aneurysms: development, rupture and preventive management. *Nature reviews. Neurology*, *12*(12), 699–713. https://doi.org/10.1038/nrneurol.2016.150

III. Tawk, R. G., Hasan, T. F., D'Souza, C. E., Peel, J. B., & Freeman, W. D. (2021). Diagnosis and treatment of unruptured intracranial aneurysms and aneurysmal subarachnoid hemorrhage. *Mayo Clinic Proceedings*, *96*(7), 1970–2000. https://doi.org/10.1016/j.mayocp.2021.01.005

IV. Muhammed Amin, O. S. (2013). Intracranial Congenital Berry's Aneurysm, Recurrent Subarachnoid Hemorrhages, and Congenital Adrenal Hyperplasia: Any Association? *Journal of Neurological Disorders & Stroke*, *1*(3).

V. W.J. van Rooij, M.E. Sprengers, A.N. de Gast, J.P.P. Peluso and M. Sluzewski. American Journal of Neuroradiology May 2008, 29 (5) 976-979; DOI: https://doi.org/10.3174/ajnr.A0964

VI. Yoon, N.K., McNally, S., Taussky, P. *et al.* Imaging of cerebral aneurysms: a clinical perspective. *Neurovasc Imaging* 2, 6 (2016). https://doi.org/10.1186/s40809-016-0016-3