Role of Ultrasound in Evaluating Pediatric Post-Operative Abdominal Pain: A Case Report in Pediatric Surgery

Ultrasound Scholarly Concentration
Case Conference #4
09.15.2021

Alexander White, MS3

THE UNIVERSITY
of NORTH CAROLINA
at CHAPEL HILL

Learning Objectives

I. Case Report in Pediatric Surgery
II. Clinical Question
III. Literature Review
IV. Advantages of Ultrasound in Postoperative Care
V. Limitations of Ultrasound in Postoperative Care

Clinical History

- 9 year-old female POD #4 s/p laparoscopic right ovarian cystectomy for a mature teratoma
- Had **intermittent fevers** (max 102.8) and transient mild **abdominal and shoulder pain** on POD #3-4
- Tolerating regular diet with loose stools (on MiraLAX)
- Abdominal and **chest XR** taken in clinic for first post-op visit
- Afebrile with **benign abdominal exam** and no pain in clinic

Imaging POD #4

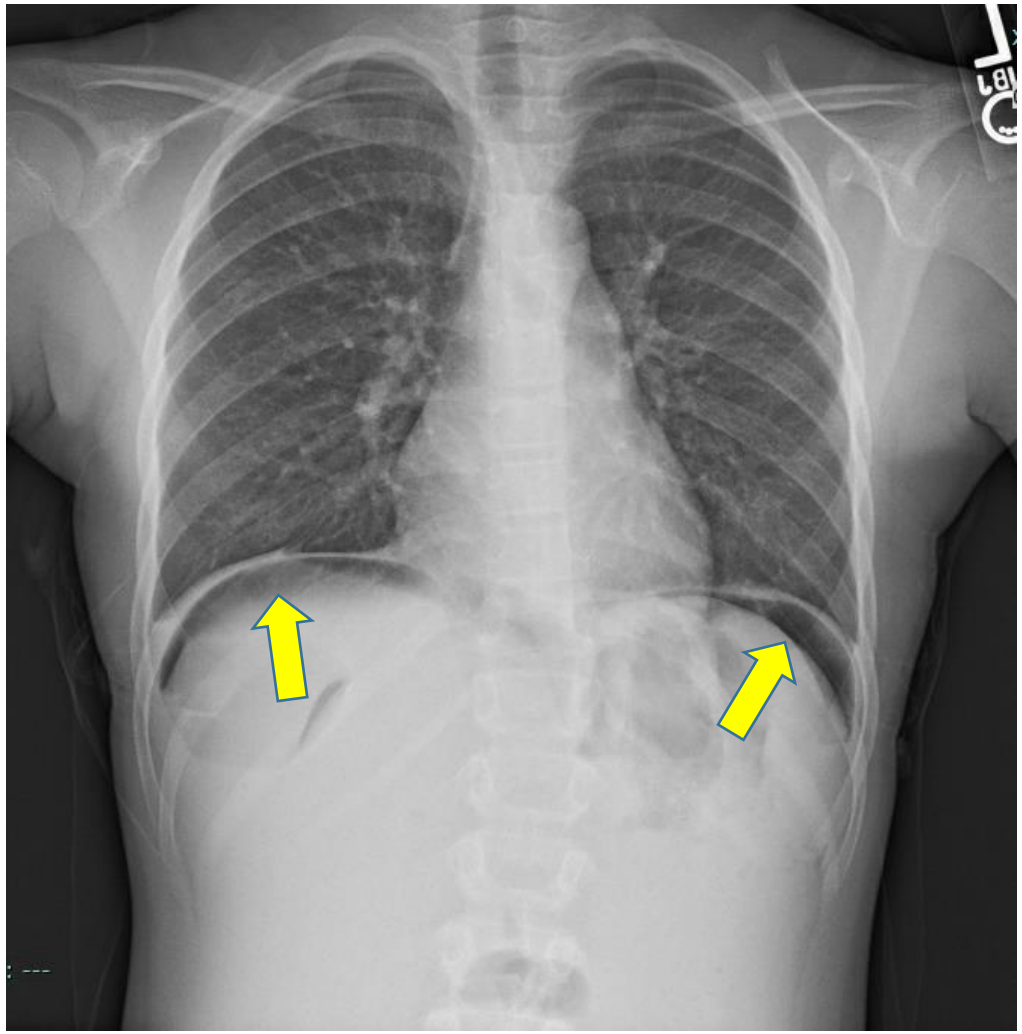

Figure 1: PA CXR

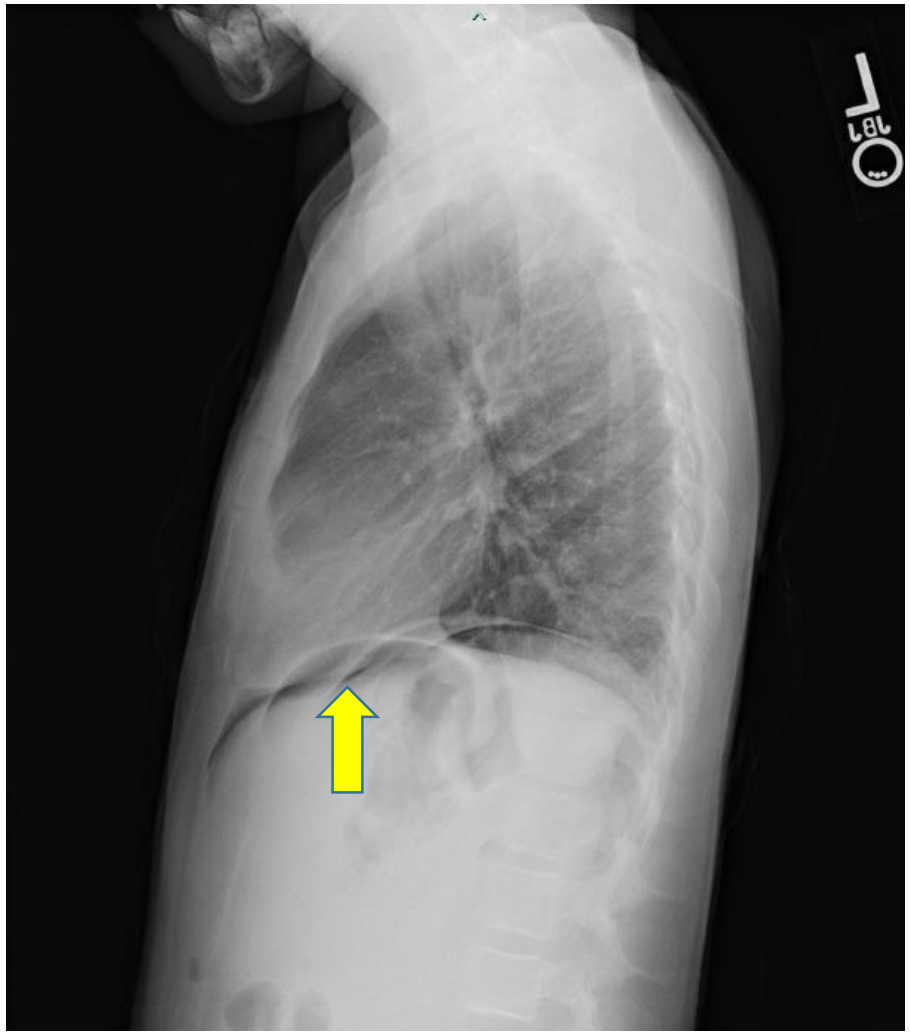

Figure 2: Lateral CXR

Clinical History

- Small **pneumoperitoneum** secondary to residual gas from laparoscopy
- Concern for occult bowel injury, deemed improbable based on benign physical exam
- Options:
  - Watchful waiting
  - CT scan with IV/PO contrast
  - Immediate laparoscopy

Admission

- POD #5 patient had persistent shoulder and abdominal pain with T-max 100.9 and loose green stools
- Still tolerating liquids, not eating
- Admitted to general pediatrics floor
- CBC w/ diff, BMP, GI stool micro panel, C. diff, SARS-CoV-2
- CT abdomen and pelvis

Imaging POD #5

Red arrow:
Small volume pneumoperitoneum

Yellow arrow:
Complex free fluid in hepatorenal space

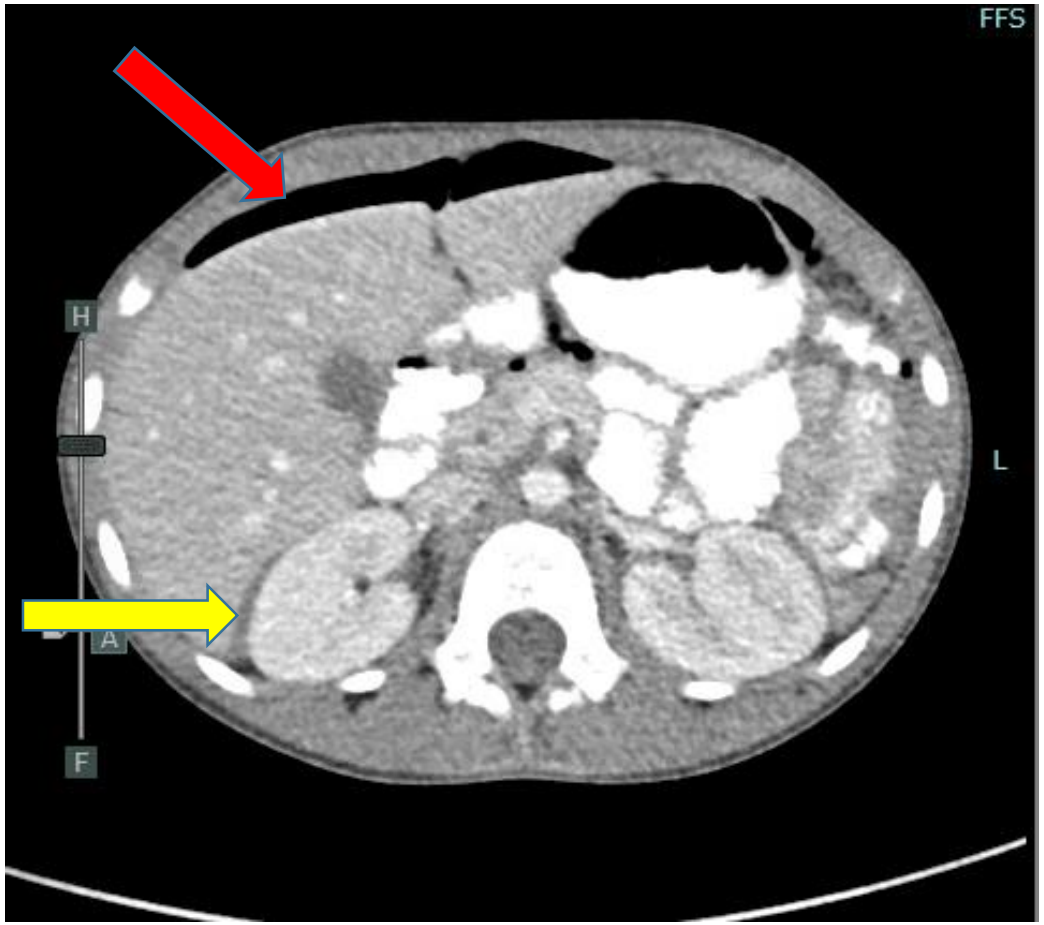

Figure 3: Axial view – CT abdomen/pelvis with IV and PO contrast

Imaging POD #5

Yellow arrow:
Complex hyperdense mass external to bowel located within the pelvis

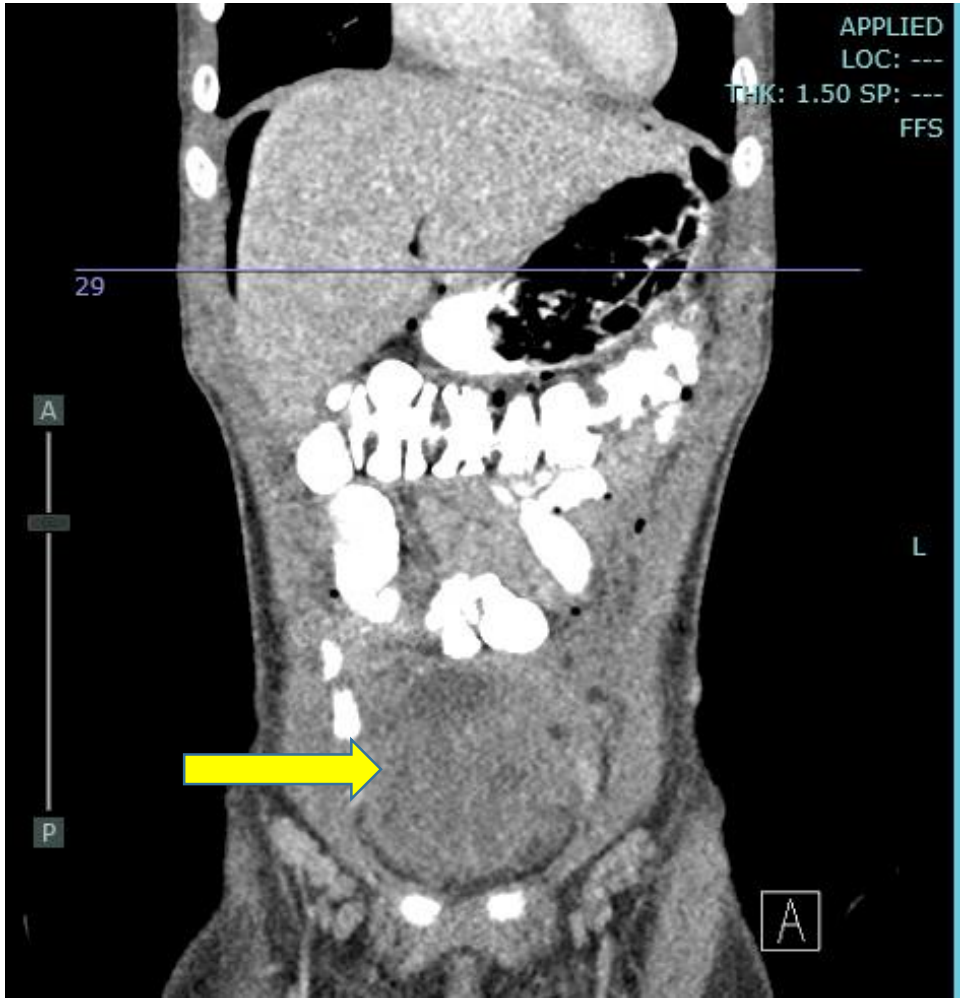

Figure 4: Coronal view – CT abdomen/pelvis with IV and PO contrast

Admission HD #1 POD #5

- Small-volume pneumoperitoneum confirmed
- No bowel obstruction, obvious intra-abdominal fluid collection, or extravasation of contrast
- *"Delineation of pelvic structures impossible due to patient's thin size and body habitus" – CT report*
- (-) GI stool panel
- (-) C. diff
- (-) SARS-CoV-2

Labs/Studies:

Recent Labs

Lab	08/10/21 1204
NA	136
K	4.0
CL	103
CO2	26.0
BUN	12
CREATININE	**0.50***

Recent Labs

Lab	08/10/21 1204
WBC	9.1
HGB	**10.1***
HCT	**30.8***
PLT	351

Admission HD#2 POD#6

- Acute worsening of diffuse abdominal pain (rated 8/10) most severe in RLQ
- Rebound tenderness and voluntary guarding
- Difficulty ambulating due to pain
- BP 111/64 | Pulse 100 | Temp 98.4 °F (Oral) | Resp 22
- Possible peritoneal signs → **Transabdominal US**

Transabdominal US

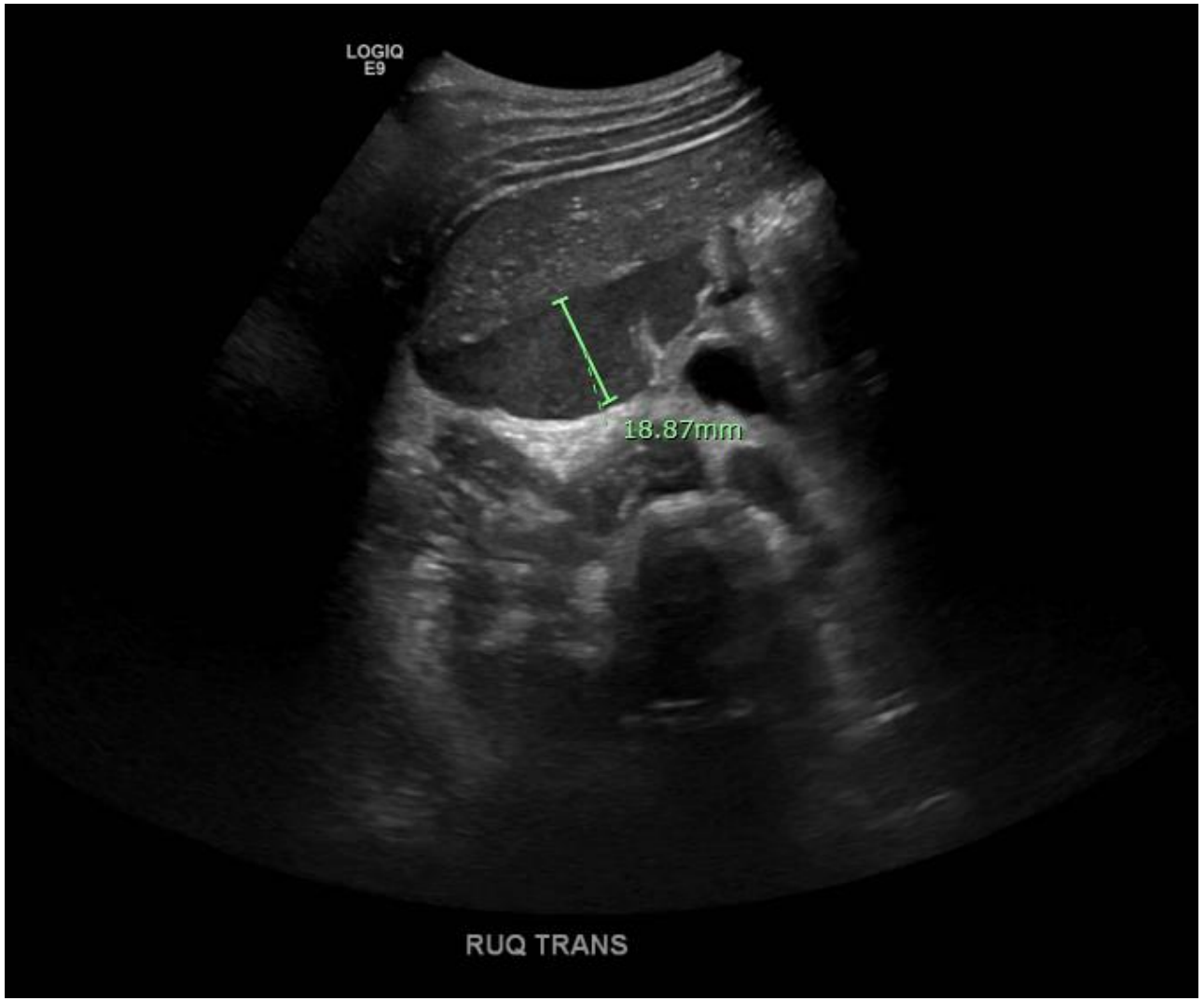

Figure 5: Complex free fluid in hepatorenal space about 2 cm in thickness suggesting hemorrhage.

Transabdominal US

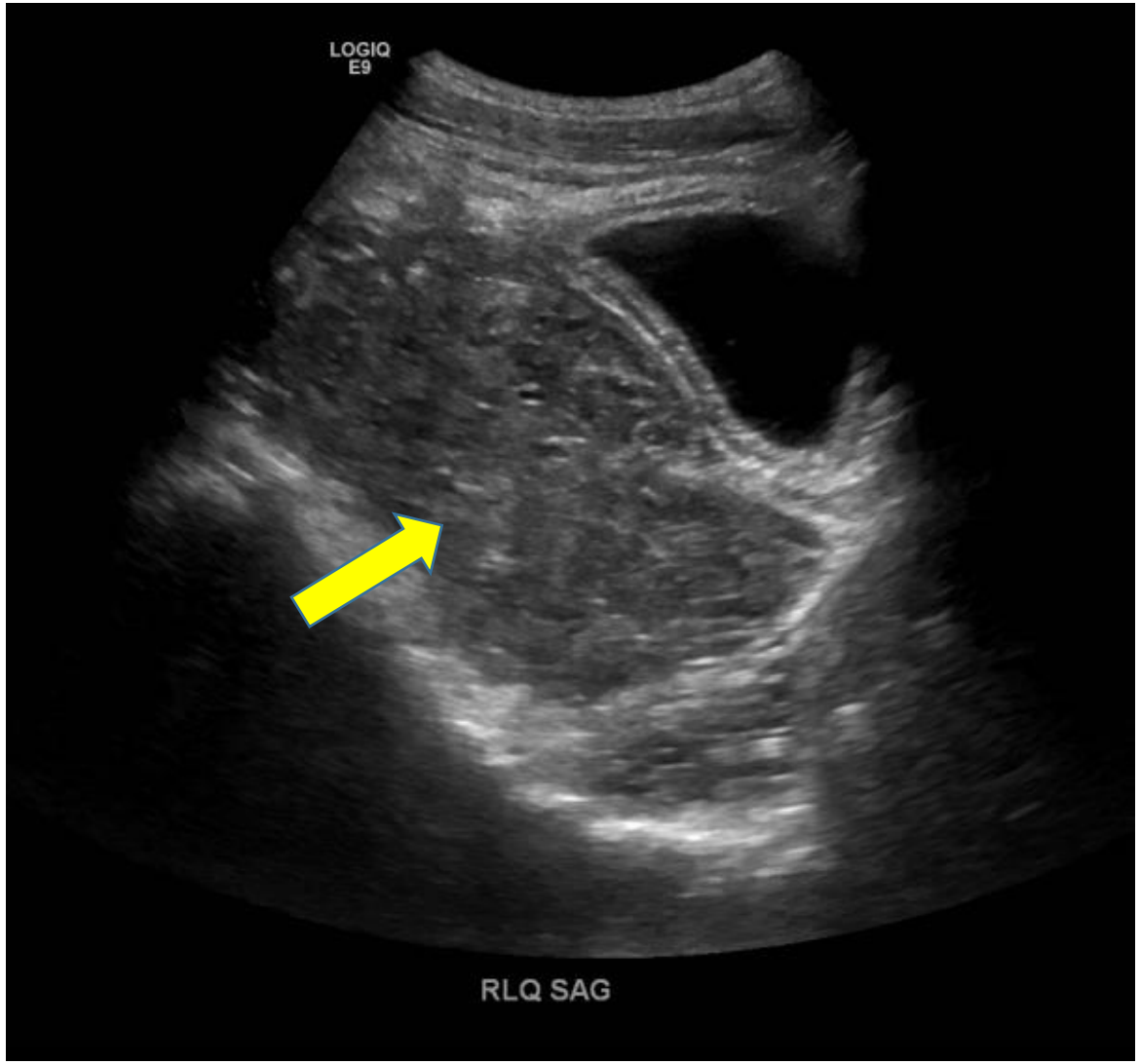

Figure 6: Heterogenous mass external to bowel measuring 7.5 x 6.6 x 4.3 cm consistent with hemorrhage and focal hematoma.

Similar in size to that found on previous CT suggesting low likelihood of active bleed.

Diagnostic US vs. POCUS

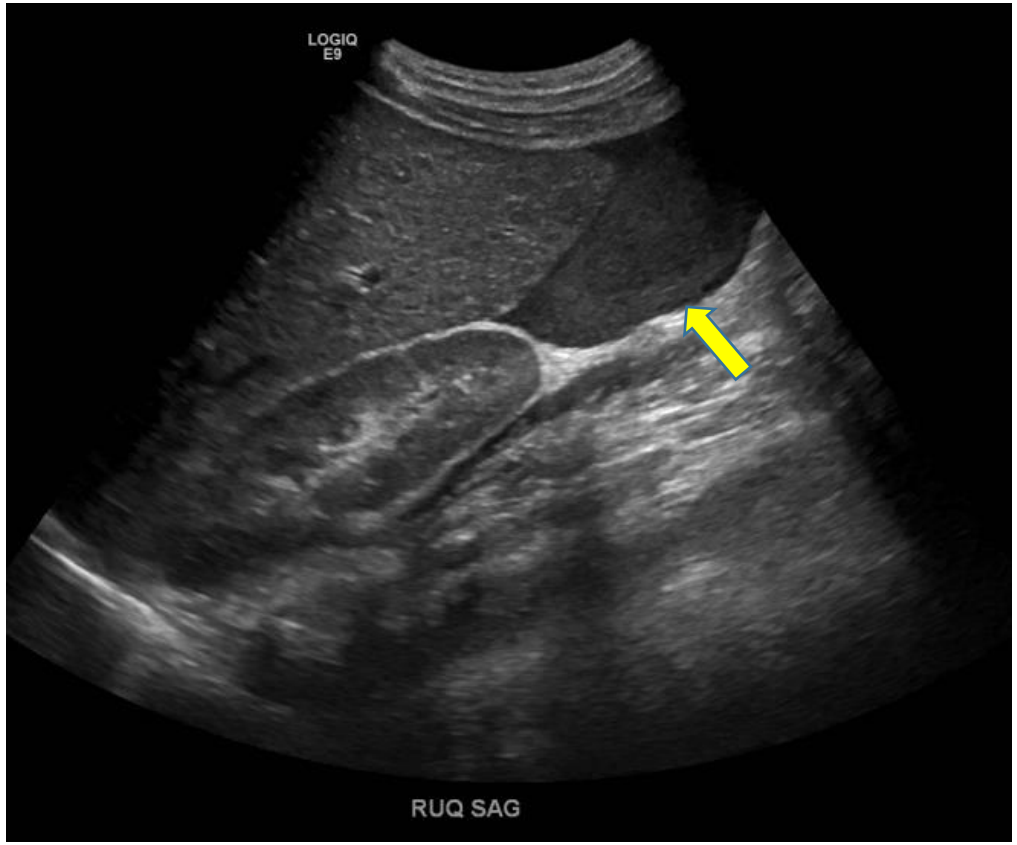

Figure 7: Diagnostic US displaying hepatorenal hemorrhage.

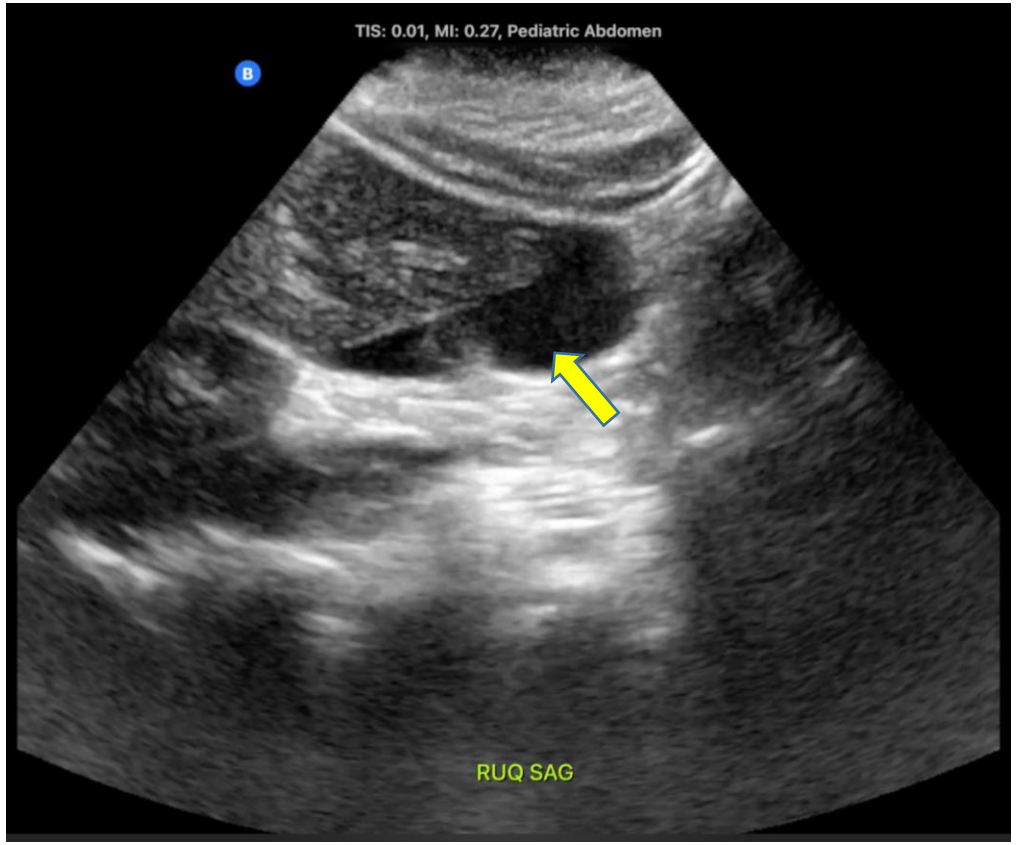

Figure 8: POCUS (Butterfly™ Probe) displaying hepatorenal hemorrhage at bedside.

Case Conclusion

- US confirmed **intra-abdominal pelvic hematoma** and small **hepatorenal hemorrhage**.
- Pelvic hematoma likely secondary to slow bleed of surrounding vasculature at site of cystectomy
- Hepatorenal hemorrhage theorized to result from iatrogenic injury from laparoscope or manipulation of surrounding structures
- Normal WBC count, **stable vitals**, transient pain flares (likely secondary to fear and anxiety)
- Return to OR for diagnostic laparoscopy not clinically indicated
- Patient discharged to home with close follow-up

Clinical Question

What is the role of POCUS for evaluating pediatric post-operative abdominal pain?

Literature Review

- **Objective**: Meta-analysis to obtain best estimate of test performance of abdominal US for pediatric intra-abdominal injury (IAI)
- **Methods**: Included retrospective and prospective studies identifying intraperitoneal fluid or IAI in blunt trauma <18 years
- **Results**: Hemoperitoneum: sensitivity 66%; specificity 95%, positive likelihood ratio 14.5, negative likelihood ratio 0.36
- **Conclusion:** *"Because of the high risk of IAI, the hemodynamically stable child with a positive US examination should immediately undergo abdominal CT scanning"*

Journal of Pediatric Surgery (2007) **42**, 1588–1594

ELSEVIER

Journal of Pediatric Surgery

www.elsevier.com/locate/jpedsurg

Performance of abdominal ultrasonography in pediatric blunt trauma patients: a meta-analysis

James F. Holmes[a,*], Aaron Gladman[b], Cindy H. Chang[c]

[a] *Department of Emergency Medicine, UC Davis School of Medicine, Davis, Sacramento, CA 95817, USA*
[b] *UC Davis School of Medicine, Davis, CA 95616, USA*
[c] *Mercy San Juan Medical Center, Carmichael, CA 95608, USA*

Literature Review

- **Objective**: Evaluate accuracy of surgeon-performed ultrasound (US) for diagnosing pediatric appendicitis
- **Methods**: Prospective study of surgeon-performed US with clinical exam compared to radiology department US to diagnose appendicitis. Final diagnosis confirmed by operative findings and pathology.
- **Results**: Surgeon-performed US had accuracy of 89%, sensitivity 93%, specificity 84%. No significant difference vs. radiology US.
- **Conclusion:** Surgeon-performed US has a high degree of accuracy for pediatric appendicitis and should be used for primary diagnosis, with CT reserved for challenging cases due to cost and radiation exposure.

Journal of Pediatric Surgery (2011) 46, 1115–1120

ELSEVIER

Journal of Pediatric Surgery

www.elsevier.com/locate/jpedsurg

Surgeon-performed ultrasound as a diagnostic tool in appendicitis

Jeffrey M. Burford[a,b], Melvin S. Dassinger[a,*], Samuel D. Smith[a]

[a]Pediatric Surgery, Arkansas Children's Hospital 1 Children's Way Little Rock, AR 72202-3591, USA
[b]Surgery, University of Arkansas for Medical Sciences, Little Rock, AR, USA

Table 1 Comparison of results

	SPUS	SPUS with clinical examination	Radiology-performed US	SPUS on patients with radiology US
No. of patients	54	54	21	21
True positive (sensitivity)	23/29 (79%)	27/29 (93%)	3/6 (50%)	5/6 (83%)
False negative	6/29 (21%)	2/29 (7%)	3/6 (50%)	1/6 (17%)
False positive	1/25 (4%)	4/25 (16%)	1/15 (7%)	1/15 (7%)
True negative (specificity)	24/25 (96%)	21/25 (84%)	14/15 (93%)	14/15 (93%)
Positive predictive value	23/24 (96%)	27/31 (87%)	3/4 (75%)	5/6 (83%)
Negative predictive value	24/30 (80%)	21/23 (91%)	14/17 (82%)	14/15 (93%)
Accuracy	47/54 (87%)	48/54 (89%)	17/21 (81%)	19/21 (90%)

Literature Review

Journal of Pediatric Surgery (2009) 44, 1189–1192

ELSEVIER

Journal of Pediatric Surgery

www.elsevier.com/locate/jpedsurg

Return of the surgeon in the diagnosis of pyloric stenosis

Daniel R. Copeland[a,b], Graham H. Cosper[a], Lisa E. McMahon[a], Cristiano Boneti[a,b], Danny C. Little[a], Melvin S. Dassinger[a], Evan R. Kokoska[a], Richard J. Jackson[a], Samuel D. Smith[a,*]

[a]*Pediatric Surgery, Arkansas Children's Hospital, Little Rock, AR 72202-3591, USA*
[b]*Surgery, University of Arkansas for Medical Sciences, Little Rock, AR 72202-3591, USA*

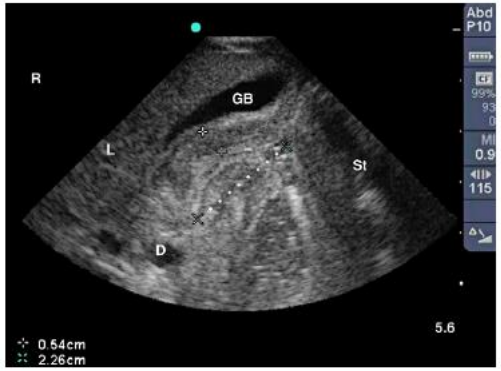

Fig. 1 Surgeon-performed US of PS. The muscle thickness (5.4 mm) and channel length (22.6 mm) are measured. Notice the "train track" appearance of the pyloric channel in this longitudinal view. GB indicates gallbladder; St, stomach; L, liver; D, duodenum.

- **Objective**: Demonstrate diagnosis of pyloric stenosis can be made by surgeon-performed ultrasound (US) alone
- **Methods**: Prospective study of surgeon-performed US to diagnose pyloric stenosis based on channel length and muscle thickness measurements. Positive results confirmed with pyloromyotomy. Negative results verified with radiologist-performed US.
- **Results**: All 32 consecutive patients were accurately diagnosed with pyloric stenosis by surgeon-performed US alone, with no false positives or false negatives.
- **Conclusion:** Surgeons trained on focused US can accurately diagnose pyloric stenosis without confirmatory testing by a radiologist.

Literature Review

Original Article

Vascular and Endovascular Surgery
2017, Vol. 51(5) 295-300

DOI: 10.1177/1538574417708131
journals.sagepub.com/home/ves
SAGE

Duplex Ultrasound Surveillance After Uncomplicated Endovascular Abdominal Aortic Aneurysm Repair

Jacob S. Schaeffer, MD[1], Irina Shakhnovich, MD, RPVI[2], Kyle N. Sieck, BS[3], Kara J. Kallies, MS[3], Clark A. Davis, MD, FACS[2], and Thomas H. Cogbill, MD, FACS[2]

- **Objective**: Evaluate duplex US as initial and subsequent surveillance technique vs. standard practice CTA after uncomplicated endovascular abdominal aortic aneurysm repair (EVAR)
- **Methods**: Retrospective chart review of patients post-EVAR who underwent initial duplex US followed by CTA pending suspicious findings.
- **Results**: Among 88 patients imaged with both duplex US and CTA, PPV was 0.88 and NPV was 0.94 for identifying post-op endoleaks.
- **Conclusion:** *"Duplex US was safe and effective for initial and follow-up surveillance after uncomplicated EVAR…we have been able to reduce the known cost burden, as well as radiation-induced and nephrotoxic complications related to surveillance by CTA in 65% of our patients"*

Literature Review

Review: US used as the primary imaging modality for pediatric female pelvis. Differentiating hemorrhage and complex free fluid from decompressed bowel loops by lack of peristalsis is achieved with real-time US imaging.

- Back et al. *Pediatr Radiol* (2017)

1138 Pediatr Radiol (2017) 47:1134–1143

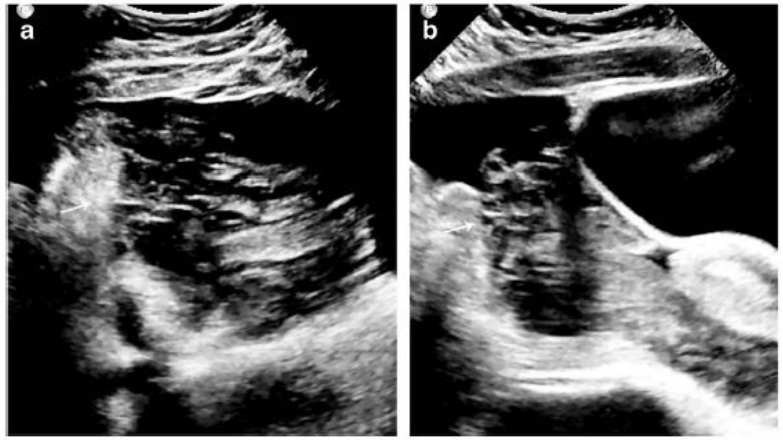

Fig. 6 Hemorrhagic ovarian cyst in a 16-year-old girl with abdominal pain, distension and syncope. **a, b** Transabdominal gray-scale US of the upper abdomen shows complex free fluid (*arrow*) in the (**a**) abdomen as well as the (**b**) pelvis. There is a heterogeneous echotexture with a reticular pattern. The material is not confined to a structure as it spans the abdomen and pelvis. The right ovary was not discretely identified. Hemorrhage and complex fluid can be differentiated from decompressed bowel loops by lack of peristalsis during real-time US imaging. The girl underwent exploratory laparotomy because of an acute decrease in hemoglobin. Two liters of blood were removed from the abdomen and a briskly bleeding hemorrhagic right ovarian cyst was identified and cauterized

Review: Sonography used in the MSK space to evaluate pain in the post-arthroplasty hip when conventional radiographs are normal. US used to identify hip effusions, bursitis, tendinitis, infections, and thromboses.

- Douis et al. *Skeletal Radiol* (2012)

Fig. 2 **a** Longitudinal image showing a distended anterior recess with a complex soft tissue and fluid collection consistent with synovitis. The two *crosses* indicate the depth of the abnormality measured at 2.5 cm. **b** Longitudinal image illustrating color flow within the anterior recess allowing differentiation of synovitis over simple effusion

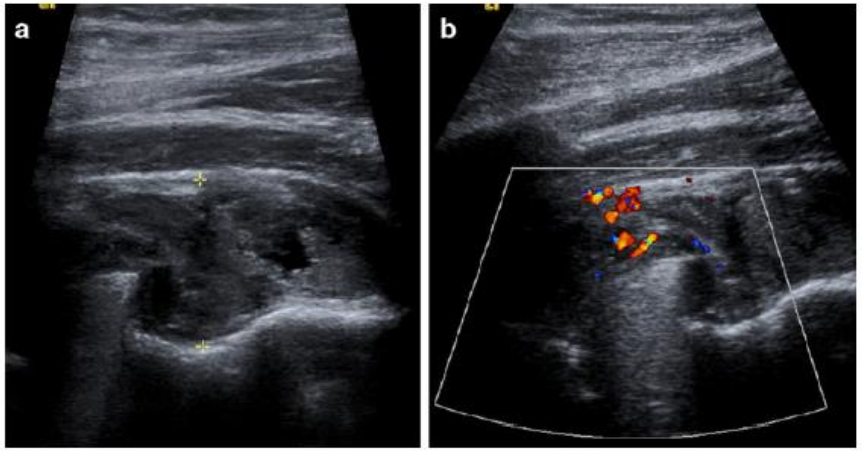

Literature Review

PEDIATRICS®

Articles ⌄ Authors/Reviewers ⌄ Policy Sub:

Volume 112, Issue 4
October 2003

REVIEW ARTICLE | OCTOBER 01 2003

Computed Tomography and Radiation Risks: What Pediatric Health Care Providers Should Know

Donald P. Frush, MD; Lane F. Donnelly, MD; Nancy S. Rosen, MD

- Frequency of **CT use in children is increasing**, however, regulations on CT use are delayed compared to adult guidelines
- Pediatric patients have increased radiosensitivity of certain tissues (thyroid, gonads, breast), longer life-span for radiation-related cancer to occur, and a lack of physical size-based adjustments in technique and dosing
- Dose of radiation from each CT is cumulative overtime, with high-dose (>100 mSv) CT associated with **fatal cancer**
- The association of CT with non-fatal cancer is unknown
- CT **disproportionately affects pediatric organs** based on their small size relative to the entire body (compared to adults)

Advantages of Post-Op US

- CT may have **suboptimal image clarity** in a thin pediatric body habitus
- US required anyway in the diagnostic work-up of this case
- **Literature limited** in the use of US for post-op pediatric abdominal pain – primary diagnosis of appendicitis, IAI, and pyloric stenosis
- Rule in intra-abdominal bleeding or hematoma
  - Low sensitivity vs. high specificity of detection
  - More judicious indication for follow-up CT
- POCUS allows rapid visualization in clinic
- Prioritize US as first-line evaluation in pediatric surgery
  - May assist clinical judgement in **watchful waiting vs. CT imaging**
- POCUS as an additional **bedside diagnostic tool**

Limitations of Post-Op US

- Not able to effectively visualize pneumoperitoneum
- Not able to evaluate small bowel perforation
  - Use of oral/IV contrast with CT
- NOT A REPLACEMENT FOR CT
  - Aid clinical decision-making
- Art of clinical medicine
  - False negative reassurance → watchful waiting
  - Skill of surgeon performing the ultrasound
- Challenges in billing, CPT codes, territorial medicine

References

1. Holmes JF, Gladman A, Chang CH. Performance of abdominal ultrasonography in pediatric blunt trauma patients: a meta-analysis. *J Pediatr Surg*. 2007;42(9):1588-1594. doi:10.1016/j.jpedsurg.2007.04.023
2. Bonasso PC, Dassinger MS, Wyrick DL, Gurien LA, Burford JM, Smith SD. Review of bedside surgeon-performed ultrasound in pediatric patients. *J Pediatr Surg*. 2018;53(11):2279-2289. doi:10.1016/j.jpedsurg.2018.04.040
3. Burford JM, Dassinger MS, Smith SD. Surgeon-performed ultrasound as a diagnostic tool in appendicitis. *J Pediatr Surg*. 2011;46(6):1115-1120. doi:10.1016/j.jpedsurg.2011.03.040
4. Copeland DR, Cosper GH, McMahon LE, et al. Return of the surgeon in the diagnosis of pyloric stenosis. *J Pediatr Surg*. 2009;44(6):1189-1192. doi:10.1016/j.jpedsurg.2009.02.025
5. Shreffler J, Huecker MR. Diagnostic Testing Accuracy: Sensitivity, Specificity, Predictive Values and Likelihood Ratios. In: *StatPearls*. Treasure Island (FL): StatPearls Publishing; March 3, 2021.
6. Schaeffer JS, Shakhnovich I, Sieck KN, Kallies KJ, Davis CA, Cogbill TH. Duplex Ultrasound Surveillance After Uncomplicated Endovascular Abdominal Aortic Aneurysm Repair. *Vasc Endovascular Surg*. 2017;51(5):295-300. doi:10.1177/1538574417708131
7. Back SJ, Maya CL, Zewdneh D, Epelman M. Emergent ultrasound evaluation of the pediatric female pelvis. *Pediatr Radiol*. 2017;47(9):1134-1143. doi:10.1007/s00247-017-3843-8
8. Douis H, Dunlop DJ, Pearson AM, O'Hara JN, James SL. The role of ultrasound in the assessment of post-operative complications following hip arthroplasty. *Skeletal Radiol*. 2012;41(9):1035-1046. doi:10.1007/s00256-012-1390-9
9. Frush DP, Donnelly LF, Rosen NS. Computed tomography and radiation risks: what pediatric health care providers should know. *Pediatrics*. 2003;112(4):951-957. doi:10.1542/peds.112.4.951