RADY 401 Case Presentation

Nathan Suskovic, MS4

July 19th 2021

UNC SCHOOL OF MEDICINE Radiology

Focused patient history and workup

- 66 year old male with history of hypertension with left sided flank pain that radiates to the left lower abdomen that started two days ago that has increased in severity. There is associated nausea and vomiting. Denies hematuria, fever, chills, urinary frequency, dysuria. Denies previous kidney stones.
- Vitals
  - BP 151/91 HR 77 T 37.1 RR 18 O2 97%
- Physical Exam
  - GU: positive left CVA tenderness
- Labs
  - CBC-wnl
  - CM-wnl with creatinine 1.05
  - Urinalysis- neg leuks, neg nitrite, 20 RBCs, 4 WBC, no bacteria

Imaging studies

CT A/P non contrast

CT A/P non-contrast

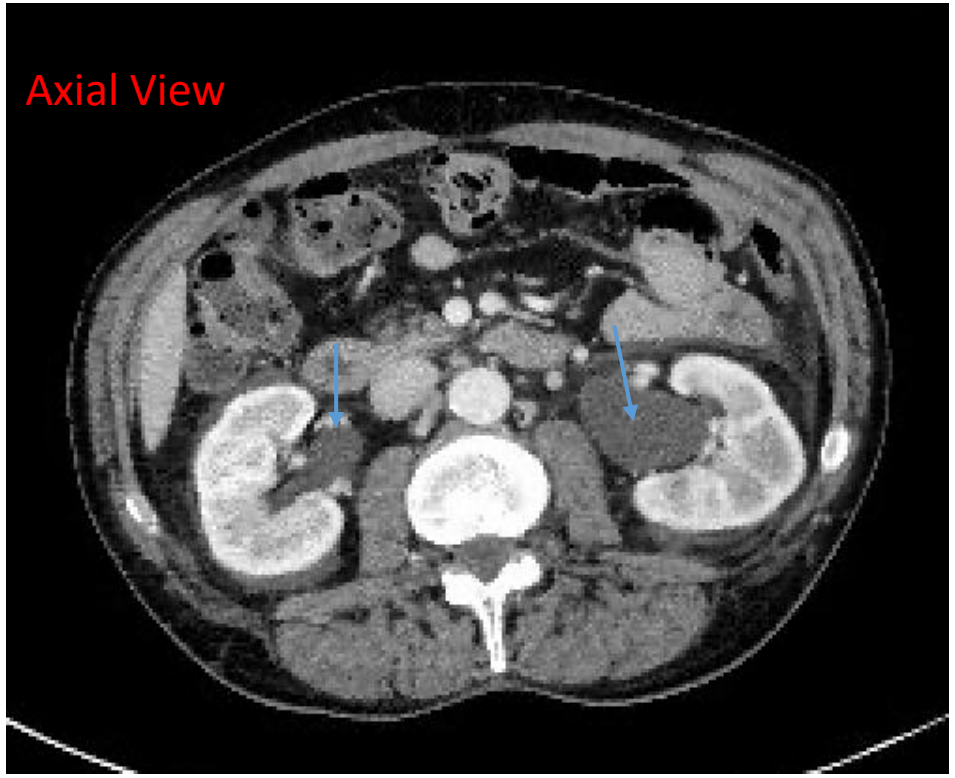

Moderate right sided hydroureteronephrosis

Moderate to severe left sided hydroureteronephrosis

Perinephric and periureteral stranding

Urothelial enhancement and dilatation

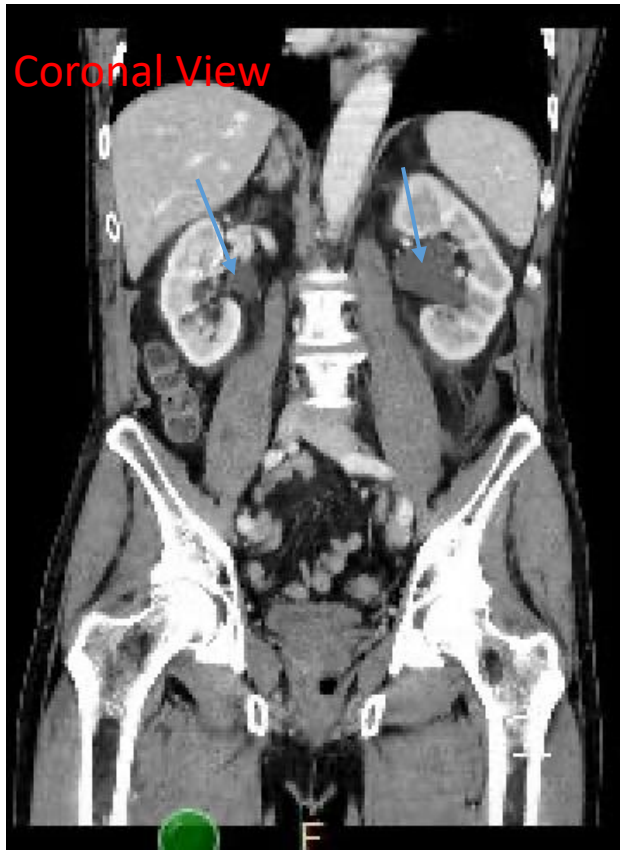

CT A/P non contrast continued

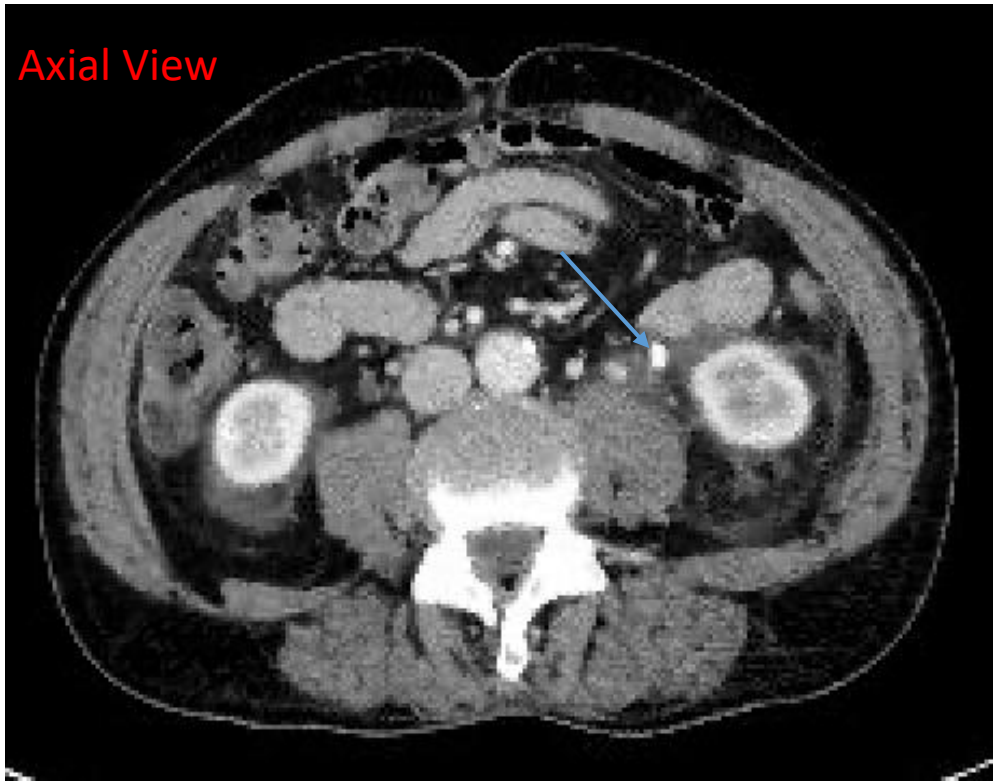

8 mm calculus in the left proximal ureter

948 Hounsfield Units

Bilateral ureteral dilation

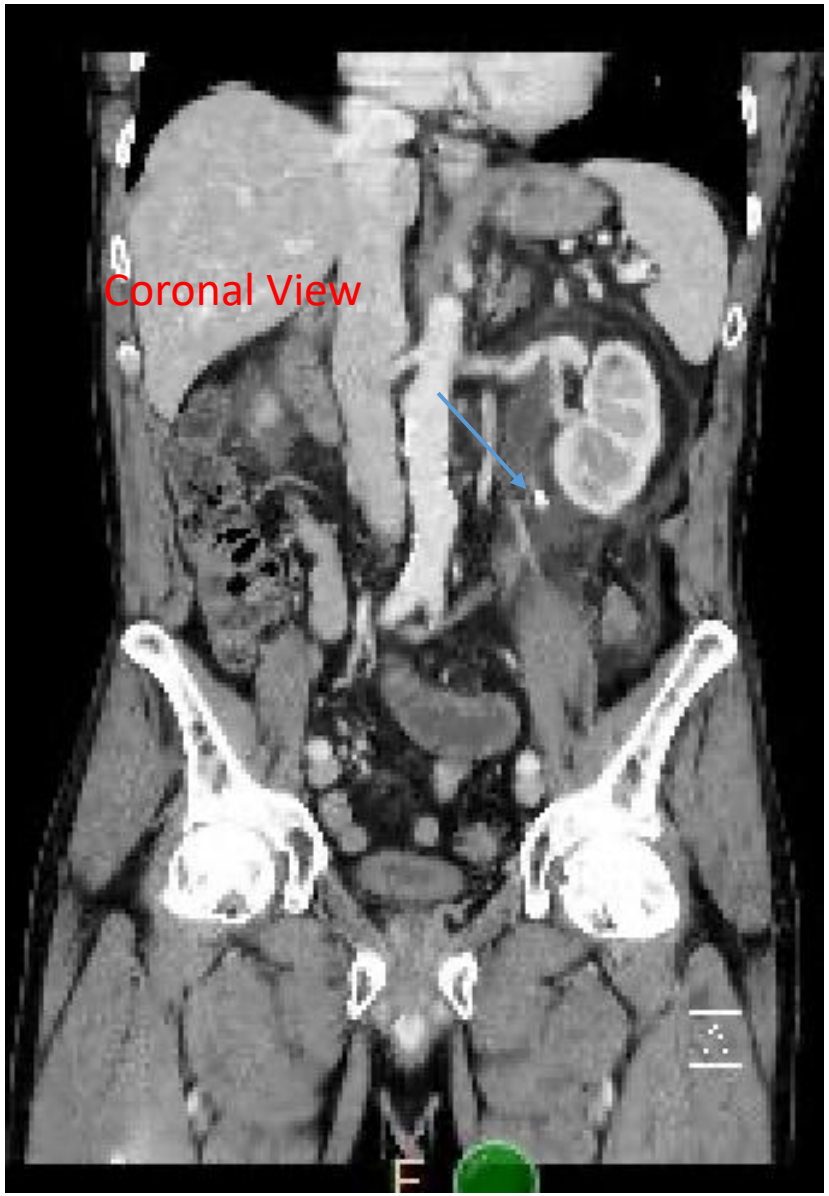

CT A/P non contrast continued

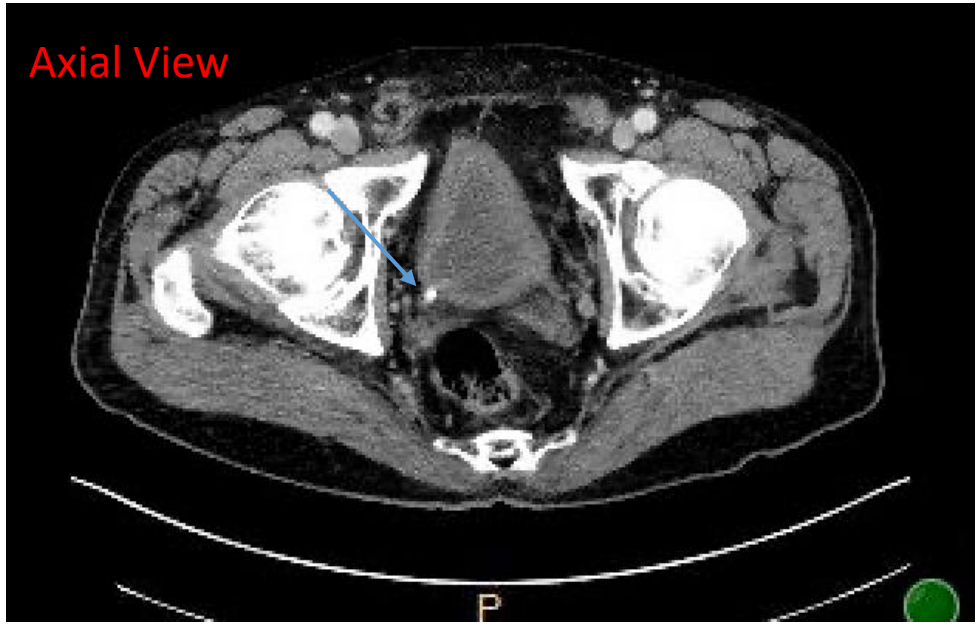

6 mm calculus at the right ureterovesical junction (UVJ)

704 Hounsfield Units

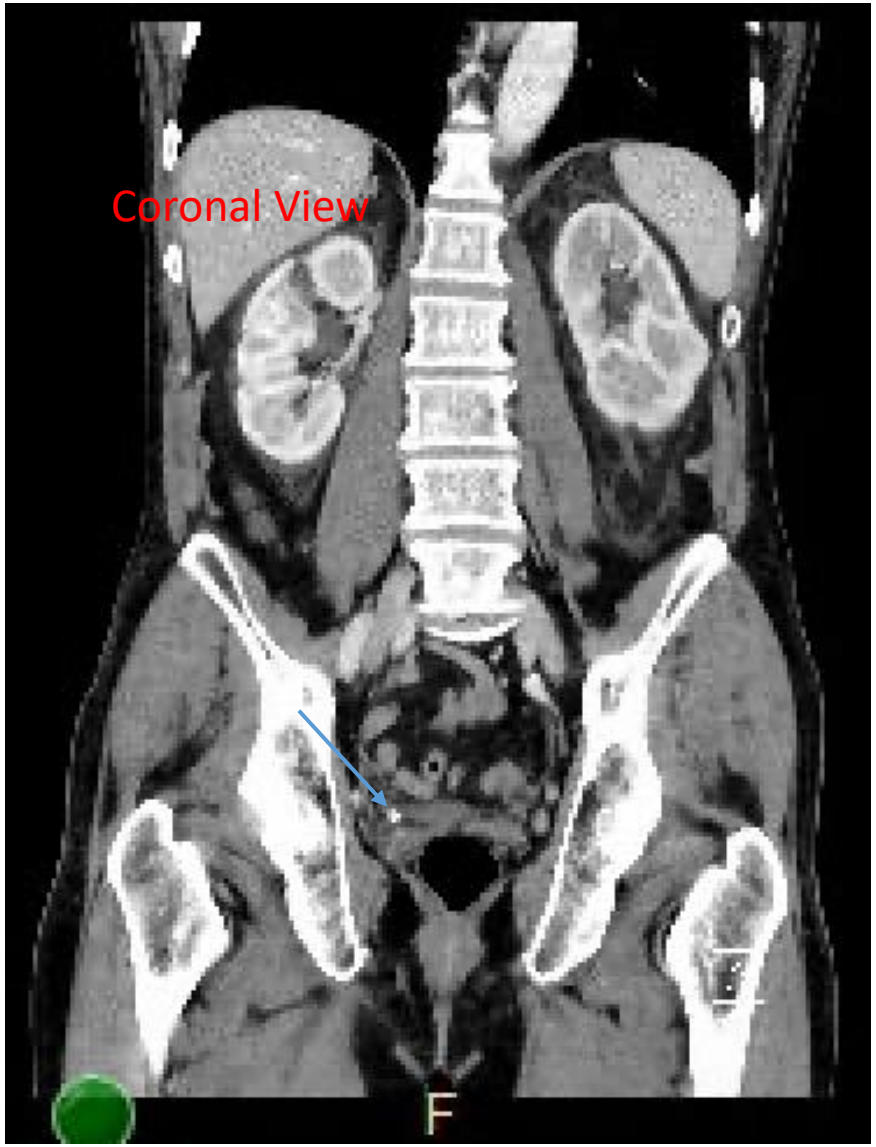

Patient treatment or outcome

- Bilateral ureteral obstruction meets criteria for emergent decompression with ureteral stent placement or nephrostomy tube placement.
- Emergent bilateral ureteral stent placement in the OR.
- Scheduled for ureteroscopy with definitive stone treatment (5 weeks later). Most likely replace bilateral ureteral stents and keep for 3-5 days post-op.

ACR® AMERICAN COLLEGE OF RADIOLOGY

2021 ACR Appropriateness Criteria®

Scenario	Procedure	Adult RRL	Peds RRL	Appropriateness Category	
Flank pain, stone disease suspected	CT abdomen and pelvis without IV contrast	1-10 mSv ☢☢☢	3-10 mSv [ped] ☢☢☢☢	Usually appropriate	🟢
	US color Doppler kidneys and bladder retroperitoneal	0 mSv O	0 mSv [ped] O	May be appropriate	🟡
	CT abdomen and pelvis without and with IV contrast	10-30 mSv ☢☢☢☢	10-30 mSv [ped] ☢☢☢☢☢	May be appropriate	🟡
	Radiography intravenous urography	1-10 mSv ☢☢☢	0.3-3 mSv [ped] ☢☢☢	May be appropriate	🟡
	MRI abdomen and pelvis without IV contrast	0 mSv O	0 mSv [ped] O	May be appropriate	🟡
	MRI abdomen and pelvis without and with IV contrast	0 mSv O	0 mSv [ped] O	May be appropriate	🟡
	Radiography abdomen and pelvis (KUB)	0.1-1mSv ☢☢	0.03-0.3 mSv [ped]..	Usually not appropriate	🔴
	CT abdomen and pelvis with IV contrast	1-10 mSv ☢☢☢	3-10 mSv [ped] ☢☢☢☢	Usually not appropriate	🔴
	US color Doppler kidneys and bladder	0 mSv	0 mSv [ped]		

UNC SCHOOL OF MEDICINE Radiology

ACR® AMERICAN COLLEGE OF RADIOLOGY

2021 ACR Appropriateness Criteria®

Scenario	Procedure	Adult RRL	Peds RRL	Appropriateness Category	
Flank pain, recurrent stone disease suspected	US color Doppler kidneys and bladder retroperitoneal	0 mSv O	0 mSv [ped] O	Usually appropriate	
	CT abdomen and pelvis without IV contrast	1-10 mSv ☢☢☢	3-10 mSv [ped] ☢☢☢☢	Usually appropriate	
	CT abdomen and pelvis without and with IV contrast	10-30 mSv ☢☢☢☢	10-30 mSv [ped] ☢☢☢☢☢	May be appropriate	
	Radiography abdomen and pelvis (KUB)	0.1-1mSv ☢☢	0.03-0.3 mSv [ped]..	May be appropriate	
	MRI abdomen and pelvis without IV contrast	0 mSv O	0 mSv [ped] O	May be appropriate	
	MRI abdomen and pelvis without and with IV contrast	0 mSv O	0 mSv [ped] O	May be appropriate	
	CT abdomen and pelvis with IV contrast	1-10 mSv ☢☢☢	3-10 mSv [ped] ☢☢☢☢	Usually not appropriate	
	Radiography intravenous urography	1-10 mSv ☢☢☢	0.3-3 mSv [ped] ☢☢☢	Usually not appropriate	

ACR® AMERICAN COLLEGE OF RADIOLOGY

2021 ACR Appropriateness Criteria®

Flank pain, stone disease suspected (pregnant)	US color Doppler kidneys and bladder retroperitoneal	0 mSv O	0 mSv [ped] O	Usually appropriate	
	CT abdomen and pelvis without IV contrast	1-10 mSv ☢☢☢	3-10 mSv [ped] ☢☢☢☢	May be appropriate	
	MRI abdomen and pelvis without IV contrast	0 mSv O	0 mSv [ped] O	May be appropriate	
	Radiography abdomen and pelvis (KUB)	0.1-1mSv ☢☢	0.03-0.3 mSv [ped]..	Usually not appropriate	
	CT abdomen and pelvis with IV contrast	1-10 mSv ☢☢☢	3-10 mSv [ped] ☢☢☢☢	Usually not appropriate	
	CT abdomen and pelvis without and with IV contrast	10-30 mSv ☢☢☢☢	10-30 mSv [ped] ☢☢☢☢☢	Usually not appropriate	
	Radiography intravenous urography	1-10 mSv ☢☢☢	0.3-3 mSv [ped] ☢☢☢	Usually not appropriate	
	MRI abdomen and pelvis without and with IV contrast	0 mSv O	0 mSv [ped] O	Usually not appropriate	

An overview of kidney stone imaging techniques

Wayne Brisbane[1], **Michael R. Bailey**[2], and **Mathew D. Sorensen**[1,3]

Table 1

Comparison of different imaging modalities for kidney stones

Imaging modality	Sensitivity* (%)	Specificity* (%)	Radiation exposure (mSv)[25]	Cost multiple relative to that of KUB[25]
CT	95 (REF [12])	98 (REF [12])	10.0	10
Low-dose CT	95 (REF [12])	97 (REF [12])	~3.0	10
Ultrasonography	84 (REF [25])	53 (REF [25])	None	5
KUB	57 (REF [25])	76 (REF [25])	0.7	1
MRI	82 (REF [25])	98 (REF [25])	None	30

Discussion: Classic Findings in Ureteral Calculus

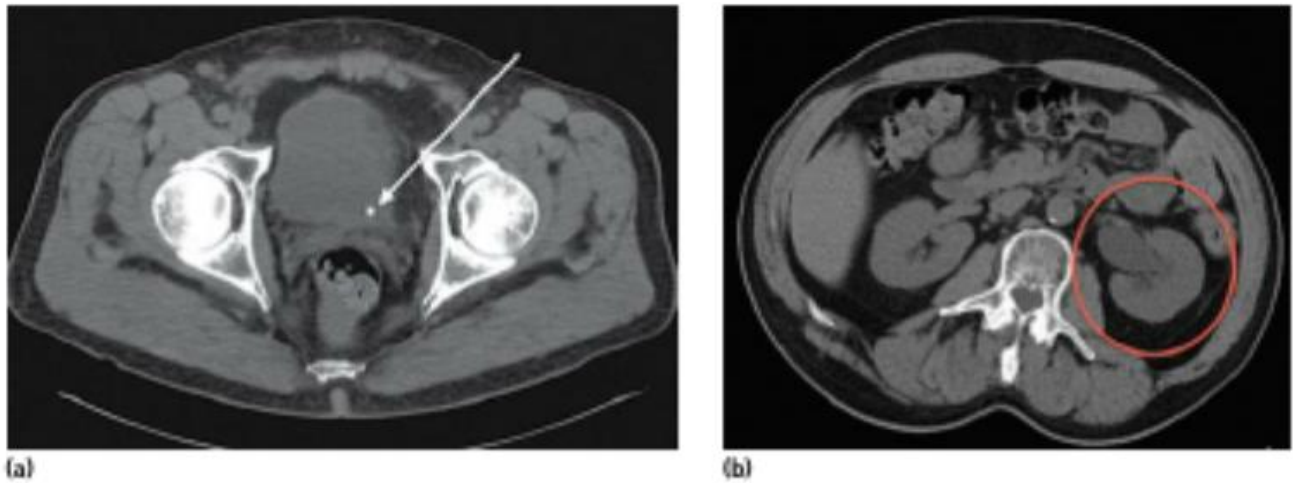

Figure 5.32 Obstructive uropathy—Two unenhanced axial CT images demonstrate a single stone in the left ureterovesicular junction (arrow) (a), with associated ureteral obstruction evidenced by the ipsilateral hydronephrosis (b).

Importance of size

5 mm-50% chances of spontaneous passage of stone

Locations of ureteral obstruction

1. Ureteropelvic junction (proximal)
2. Iliac cross the ureter (mid)
3. Ureterovesical junction (distal)

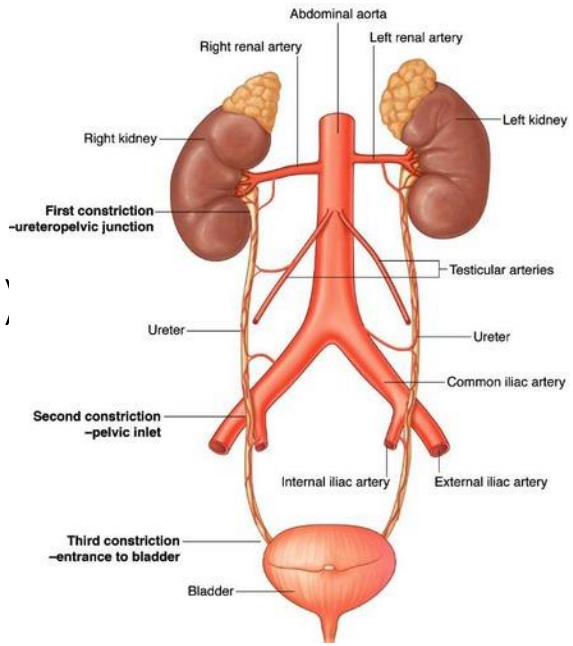

Discussion: Indications for Emergent Decompression

- Multiple ED visits, intractable pain, N/V unable to tolerate PO intake,
- Unstable vitals: hypotensive, fever, tachycardia
- Labs: leukocytosis, AKI-elevated creatinine, urinalysis suggestive of infection-leukocyte esterase, nitrites, RBCs, WBCs, bacteria
- Anatomical: bilateral ureteral obstruction or unilateral obstruction of solidary kidney

- Failure to place ureteral stent can place percutaneous nephrostomy tube.

Discussion: Treatment

- Medical expulsive therapy (MET)
  - Stones <5 mm
  - Pain management and Tamsulosin 0.4 mg two times daily
- Ureteroscopy (laser, basket)
- Extracorporeal Shock Wave Lithotripsy
  - Least invasive but lower rates of complete stone burden relief
  - <970 HU
- Percutaneous Nephrolithotomy
  - Large UPJ and renal stones
- Open approach with nephrectomy
  - Large stone burden, refractory nephrolithiasis and recurrent disease.

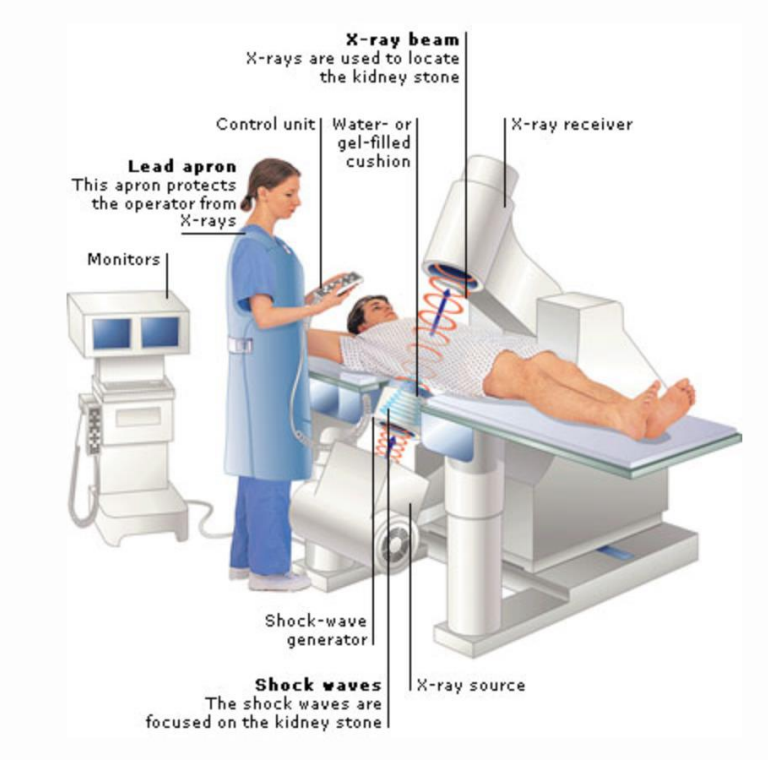

Discussion: Hounsfield Units CT measurement

HOUNSFIELD UNITS

Water = 0 HU

All other densities relative to water

- Air -1000 black
- Lung -600 to -400
- Fat -100 to – 40
- Soft tissue 40 to 80
- Bone 400 to 1000 white

Usefulness of hounsfield unit and density in the assessment and treatment of urinary stones

World Journal of Nephrology

Adnan Gücük, Uğur Üyetürk

Table 1 Some critical hounsfield unit values in recent literature

	Ref.	Year	Hounsfield units	Affected parameters
Prediction of stones	Motley *et al*[4]	2001	Density < 76 /mm	Non-calcium stone
	Patel *et al*[5]	2009	Mean, 879 ± 230	Calcium oxalate monohydrate stone
			Mean, 844 ± 346	Apatite stone
			Mean, 550 ± 74	Cystine stone
	Spettel *et al*[7]	2013	< 500	Uric acid stone
Prediction of Radio-opacity	Chua *et al*[9]	2012	> 498.5	Radio-opaque stone
	Huang *et al*[10]	2009	> 800 (ureteral stones)	Radio-opaque
			< 200	Radiolucent
Predicting the success of ESWL	Hameed *et al*[15]	2013	> 1350	Low ESWL success
	El-Assmy *et al*[16]	2011	> 1000	Low ESWL success
	El-Assmy *et al*[17]	2013	⩽ 600 and stone length ⩽ 12 mm (in children)	High ESWL success
	Ouzaid *et al*[18]	2012	> 970	Low ESWL success
	Foda *et al*[19]	2013	> 934	Low ESWL success
Use in PNL	Gücük *et al*[20]	2012	< 677.5	Low PNL success
	Gücük *et al*[21]	2013	< 677.5	Increases success with flexible nephroscope use
Use in URS	Kim *et al*[22]	2014	Any	No effect
Medical expulsive treatment	Erturan *et al*[24]	2013	Any	No effect

UNC Top Three ie Key Points on Ureteral Stones

1. Gold standard imaging is **CT A/P non contrast** for stone disease.
2. There are published indications for decompression via **emergent stent placement**.
3. There are published density ranges [**Hounsfield Units**] for types of calculi along with urologic intervention successes.

References

1. Acute Onset Flank Pain—Suspicion of Stone Disease (Urolithiasis). *American College of Radiology*, 2015, https://www.acr.org/Clinical-Resources/ACR-Appropriateness-Criteria.
2. Brisbane W, Bailey M, Sorensesn M. An overview of kidney stone imaging techniques. An overview of kidney stone imaging techniques. *Nat Rev Urol.* 2016 Nov; 13(11): 654-662.
3. Birchard, Katherine R., et al. "Abdominal Pelvic Imaging." *Critical Observations in Radiology for Medical Students*, John Wiley and Sons, 2015, p. 84–85.
4. Barrow, Kaitlyn. "ANATOMY OF THE UPPER AND LOWER URINARY TRACT." *Quizlet*, 2018, https://quizlet.com/336638745/anatomy-of-the-upper-and-lower-urinary-tract-flash-cards/.
5. Kim Jeremy and Jordan Sheryl. Body CT-Radiology Residency Educational Scholarship. *University of North Carolina School of Medicine-Department of Radiology*, 2020.
6. Preminger G. Kidney stones in adults: Surgical management of kidney and ureteral stones. *UpToDate.* June 23 2021.
7. Ouzaid I, Al-Qahtani S, Dominique S, et al. A 970 Hounsfield units (HU) threshold of kidney stone density on non-contrast computed tomography (NCCT) improves patients' selection for extracorporeal shockwave lithotripsy (ESWL): evidence from a prospective study. *BJU Int.* 2012 Dec; 110(11): 438-42.
8. Lithotripsy (ESWL). *Urology associates*, 2021, https://www.urology.co.nz/info/lithotripsy.
9. Gücük A, Uyetürk U, Oztürk U, Kemahli E, Yildiz M, Metin A. Does the Hounsfield unit value determined by computed tomography predict the outcome of percutaneous nephrolithotomy? J Endourol. 2012 Jul;26(7):792-6.