RSNA®
Radiological Society
of North America

Original Research
Breast Imaging

Free Access

Beyond Wires and Seeds: Reflector-guided Breast Lesion Localization and Excision

Victoria L. Mango, Ralph T. Wynn, Sheldon Feldman, Lauren Friedlander, Elise Desperito, Sejal N. Patel, Ameer Gomberawalla, Richard Ha

Author Affiliations

Published Online: Apr 21 2017 | https://doi.org/10.1148/radiol.2017161661

Eric Fromke, MS4

August 13, 2021

Learning objectives

By the end of this journal club, participants will be able to:

1. Understand the basic anatomy of the breast
2. Understand basics of breast cancer
3. Understand the BI-RADS lexicon
4. Appreciate the need for and history of localization procedures
5. Differentiate methods of localization
    - Benefits, pitfalls, reasoning behind using each

Module Outline

I. <u>Case</u>
II. Background
III. Article Overview
IV. Clinical Questions
V. Key Points

Case presentation

70 yo female with a medical history of benign right breast biopsy in 1989 who presented for diagnostic mammogram in the setting of new palpable right breast mass.

She is G1P1, first pregnancy at age 25 yo, menarche at 15 yo, LMP 2003. Her mother had breast cancer.

Case Imaging: Mammogram

R MLO

L MLO

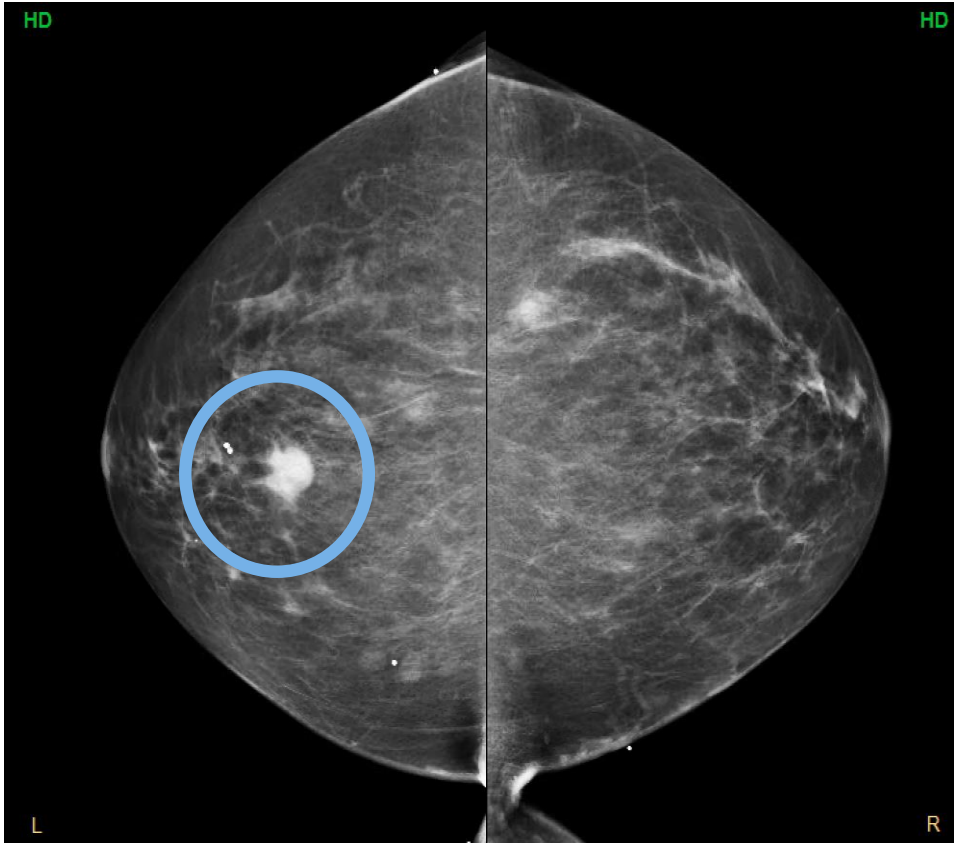

R CC

L CC

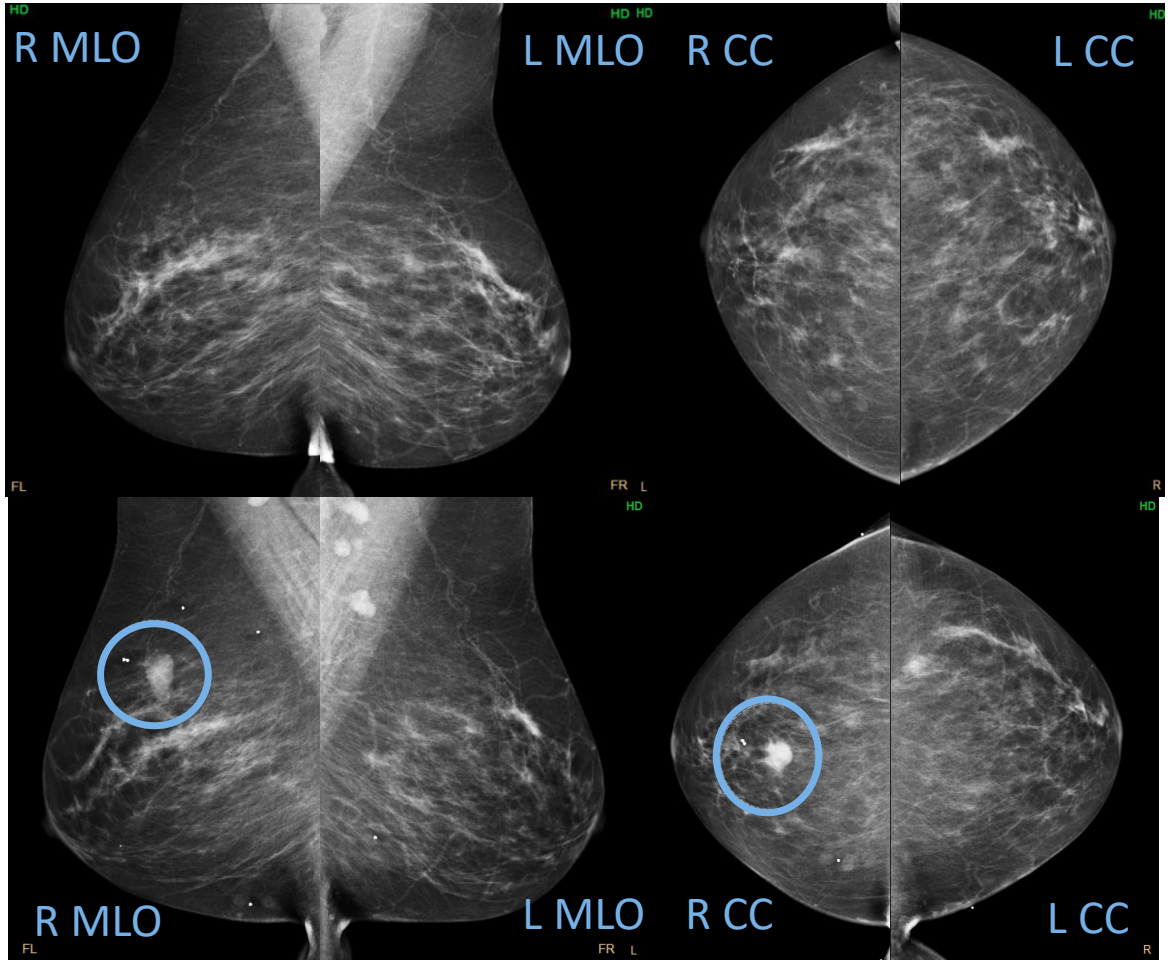

prior

current

Case imaging: US

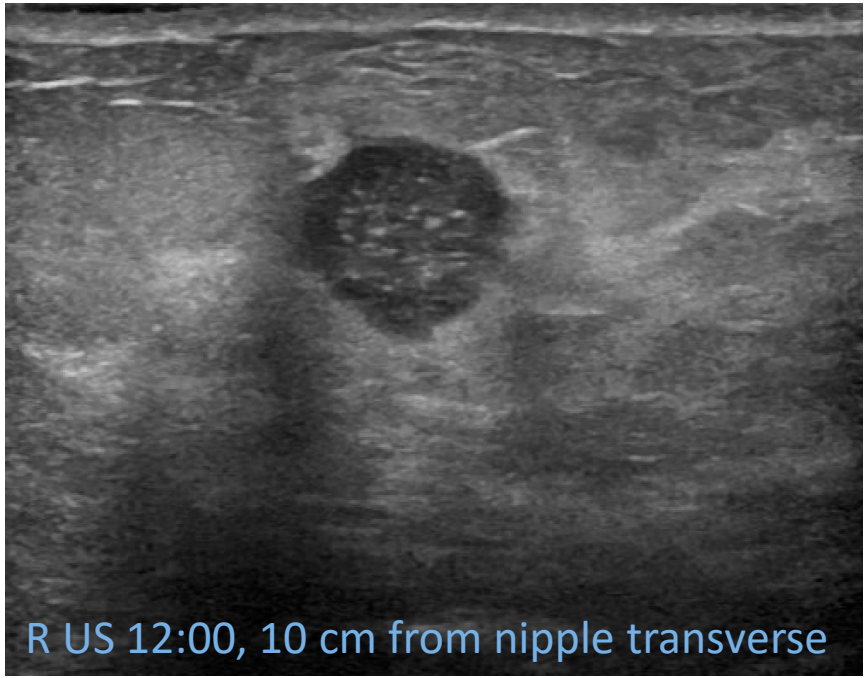

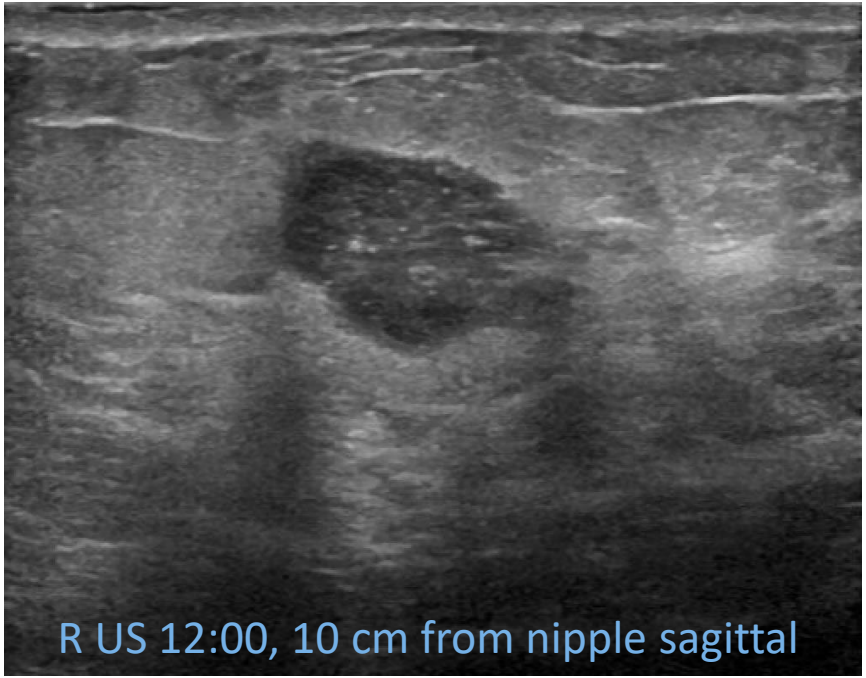

Irregular, hypoechoic, not circumscribed mass measuring 1.7 x 1.9 x 1.8 cm; multiple echogenic foci c/w internal calcifications

Case imaging: US-guided CNB

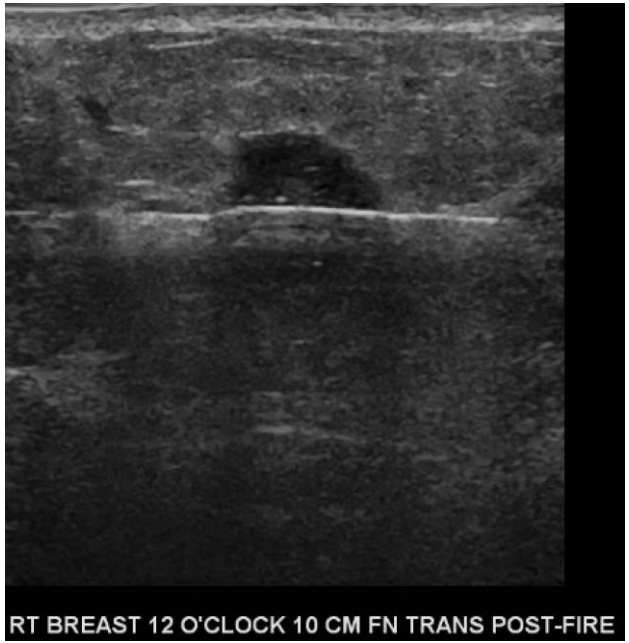

Case imaging: Post bx mammogram

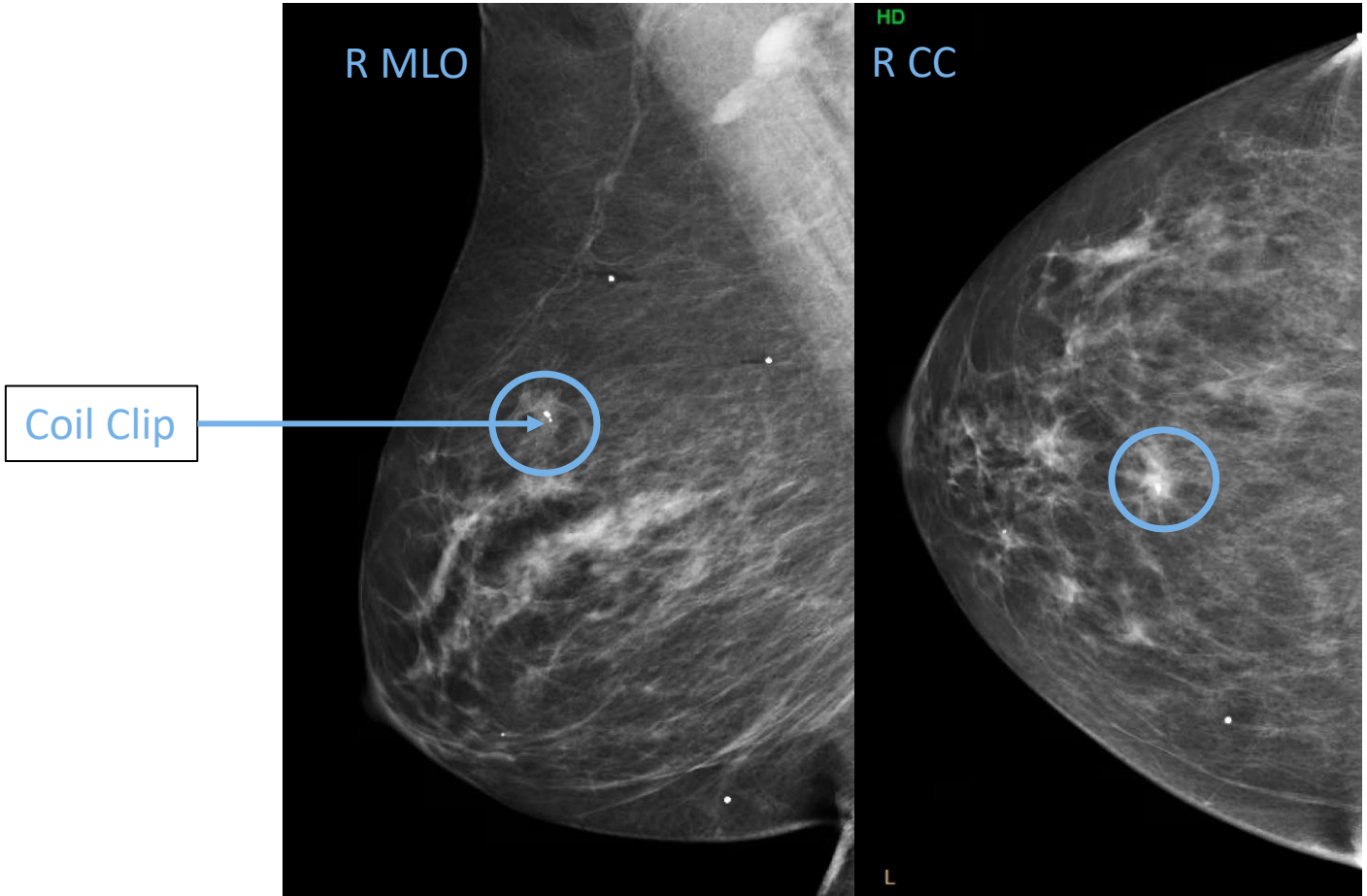

Patient Course

- Biopsy results
  - Invasive ductal carcinoma (IDC), histologic grade 3
    - *Triple Negative*: ER (-), PR (-), HER2 (-)

- Treatment plan via Multidisciplinary Conference (MDC)
  - Neoadjuvant chemotherapy prior to BCT/SLNBx
    - BCT requiring localization of the lesion

Case questions

- How do we localize a non-palpable breast mass for a surgeon?
- What methods can we employ to localize a breast mass?
  - Why deploy a Scout?
  - Is one method better than another?

Module Outline

I. Case

II. **Background**

III. Article Overview

IV. Clinical Questions

V. Key Points

Background: Anatomy of the Breast

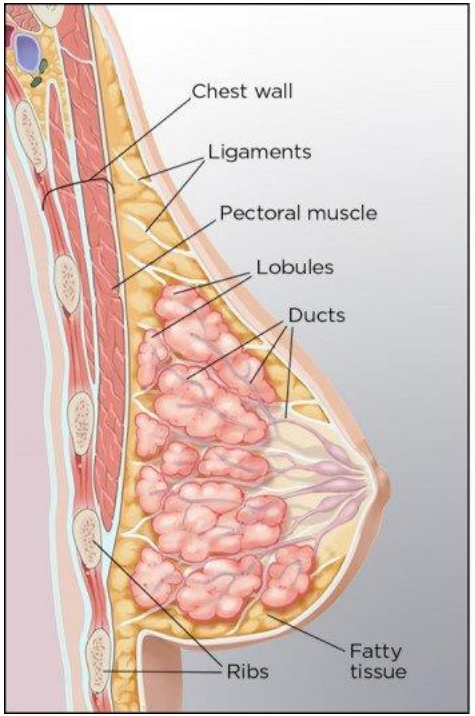

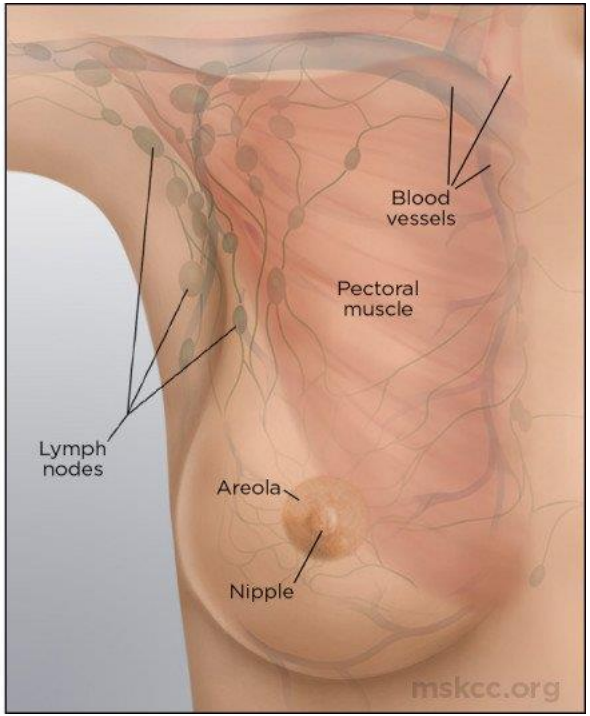

Background: Breast Cancer

- Most common cancer in women in the US outside of skin cancer
  - 2021 estimated new cases: 281,550
- Second leading cause of cancer death in women (lung cancer)
  - 2021 estimated deaths: 43,600
- Most cancers are dependent on estrogen and/or progesterone for growth
  - We test for hormone receptors
    - HR positivity is associated with longer disease-free survival, better overall survival, and longer survival after recurrence
    - Treat with hormonal therapy (aromatase inhibitors, tamoxifen)
- HER2/neu oncogene (part of EGFR family) plays a role in angiogenesis and tumor growth when over-expressed
  - We test for HER2/neu oncogene, too
    - Over-expressed in 15% of cancers
      - Poor differentiation, high grade tumors, high cell proliferation rates, DNA aneuploidy, and hormone receptor negativity
    - Treat with HER2 specific therapies (Herceptin and pertuzumab), anthracyclines as able

Intro to BI-RADS

BI-RADS® ASSESSMENT CATEGORIES

includes PPV for malignancy and suggested verbiage for the accompanying Recommendation

- Category 0: INCOMPLETE - NEED ADDITIONAL IMAGING EVALUATION AND/OR PRIOR MAMMOGRAMS FOR COMPARISON
  - Recall for additional imaging and/or comparison with prior examinations
- Category 1: NEGATIVE (0% risk)
  - Routine mammography screening
- Category 2: BENIGN (0% risk)
  - Routine mammography screening
- Category 3: PROBABLY BENIGN (<2% risk)
  - Short interval 6 month follow-up *OR continued surveillance*
- Category 4: SUSPICIOUS (2-95% risk)
  - Biopsy should be performed in the absence of clinical contraindications
- Category 5: HIGHLY SUGGESTIVE OF MALIGNANCY (>95% risk)
  - Biopsy should be performed in the absence of clinical contraindications
- Category 6: KNOWN BIOPSY-PROVEN MALIGNANCY (100% risk)
  - Surgical excision when clinically appropriate

Triple Negative Breast Cancer (TNBC)

- ER (-) / PR (-) / HER2 (-)
  - No therapeutic targets --> difficult to treat
  - More aggressive biology
    - Earlier onset of metastatic disease, visceral mets, higher histologic grade

- 15-20% of breast cancers diagnosed worldwide
  - More likely to affect younger people and races such as African Americans, Hispanics, those with a BRCA1 gene mutation

- Imaging features
  - Often much different than other classical malignancies
    - Often lacks spiculated margins and associated suspicious calcifications on mammography
      - Round-ish irregular or obscured mass
      - Look for secondary features: edema, skin thickening, suspicious axillary adenopathy
    - On ultrasound, can have benign-like features: well-circumscribed margins, posterior enhancement
      - However, roundness can help hint at TNBC
      - Can have complex cystic and solid mass features (necrotic)

- Treatment course
  - Chemotherapy: platinum-based; poly ADP-ribose polymerase (PARP) inhibitors
    - Immunotherapy with Pembrolizumab (PD-L1) when applicable
  - Radiation
  - Surgery

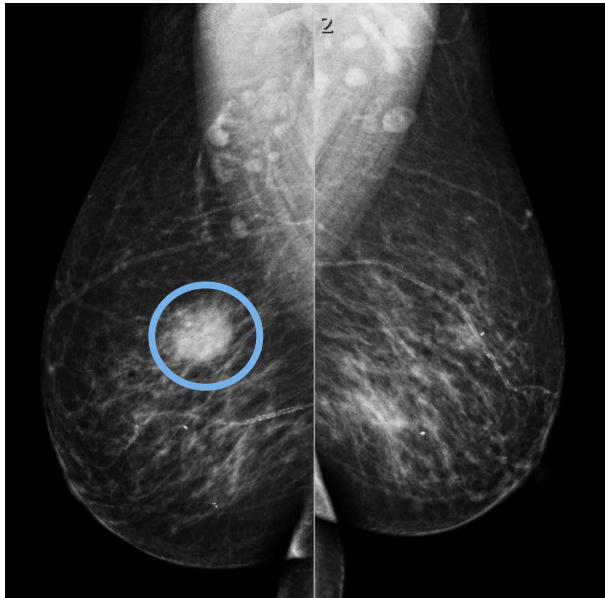

The Basics of Pre-op Needle Localization

- Nonpalpable lesion localization is required prior to surgical removal/Breast Conserving Therapy (BCT)

- Since 1970s, wire localization has been successfully employed
  - Pros:
    - Locate the nonpalpable lesion under image guidance
    - Allows for BCT, improving aesthetics

  - Cons:
    - Uncomfortable; complicates OR scheduling/efficiency; wire can fracture or displace due to external component; may complicate surgical approach as wire may be in suboptimal surgical entrance

- Recently, radioactive iodine seed localization has gained popularity
  - Radioactive precautions/regulations; sometimes difficult to schedule (decay)

Breast Needle/Wire Localization

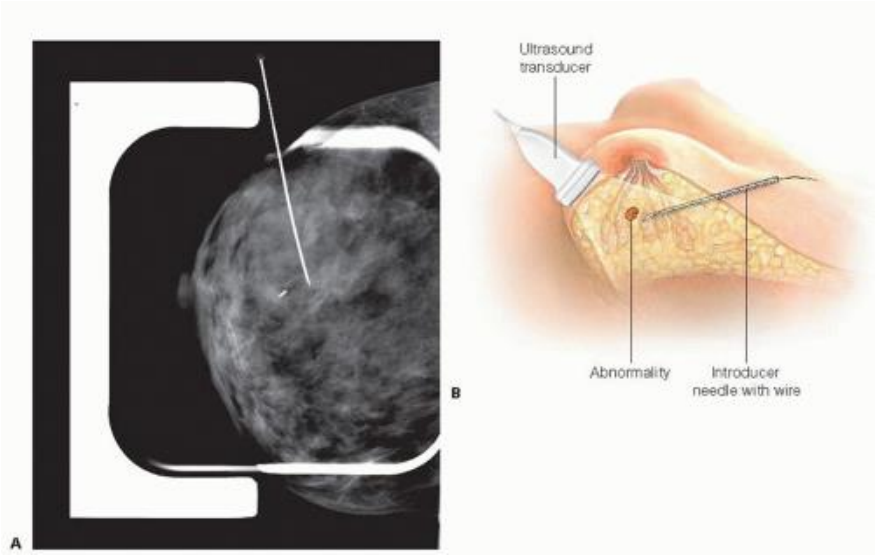

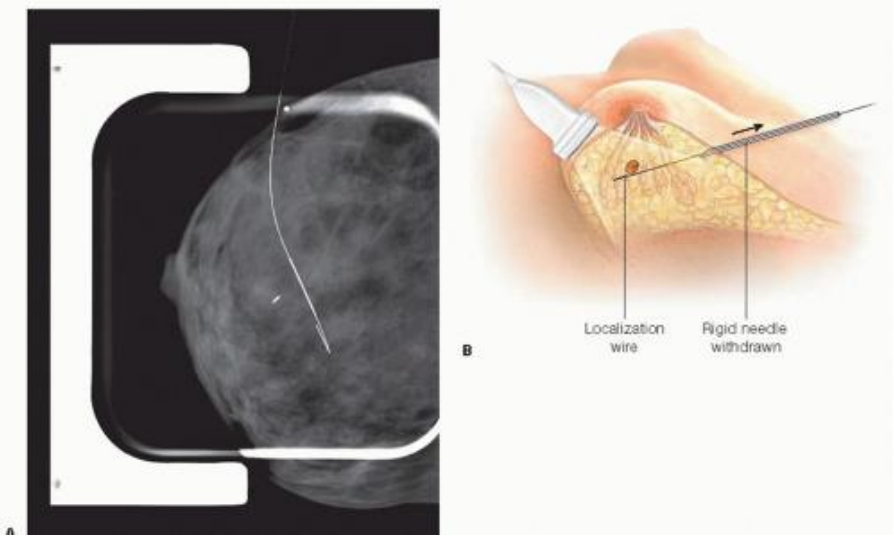

Why SCOUT?

- 1.2 cm infrared-activated, electromagnetic wave reflector
  - Placed via image guidance
  - Can detect percutaneously with a handpiece/console system
    - Infrared light receptor, resistor, and two antennae
      - Antennae are offset to secure the Scout in tissue

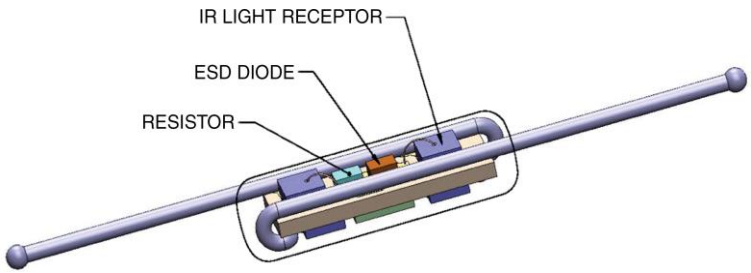

- Pros
  - Not radioactive
  - No external component
  - FDA-approved for up to 30 days prior to procedure
  - Does not pigeon-hole surgeon's operative approach

Mango et al

Why SCOUT?

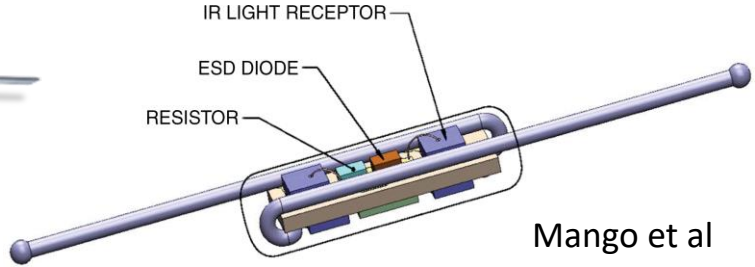

Mango et al

How SCOUT?

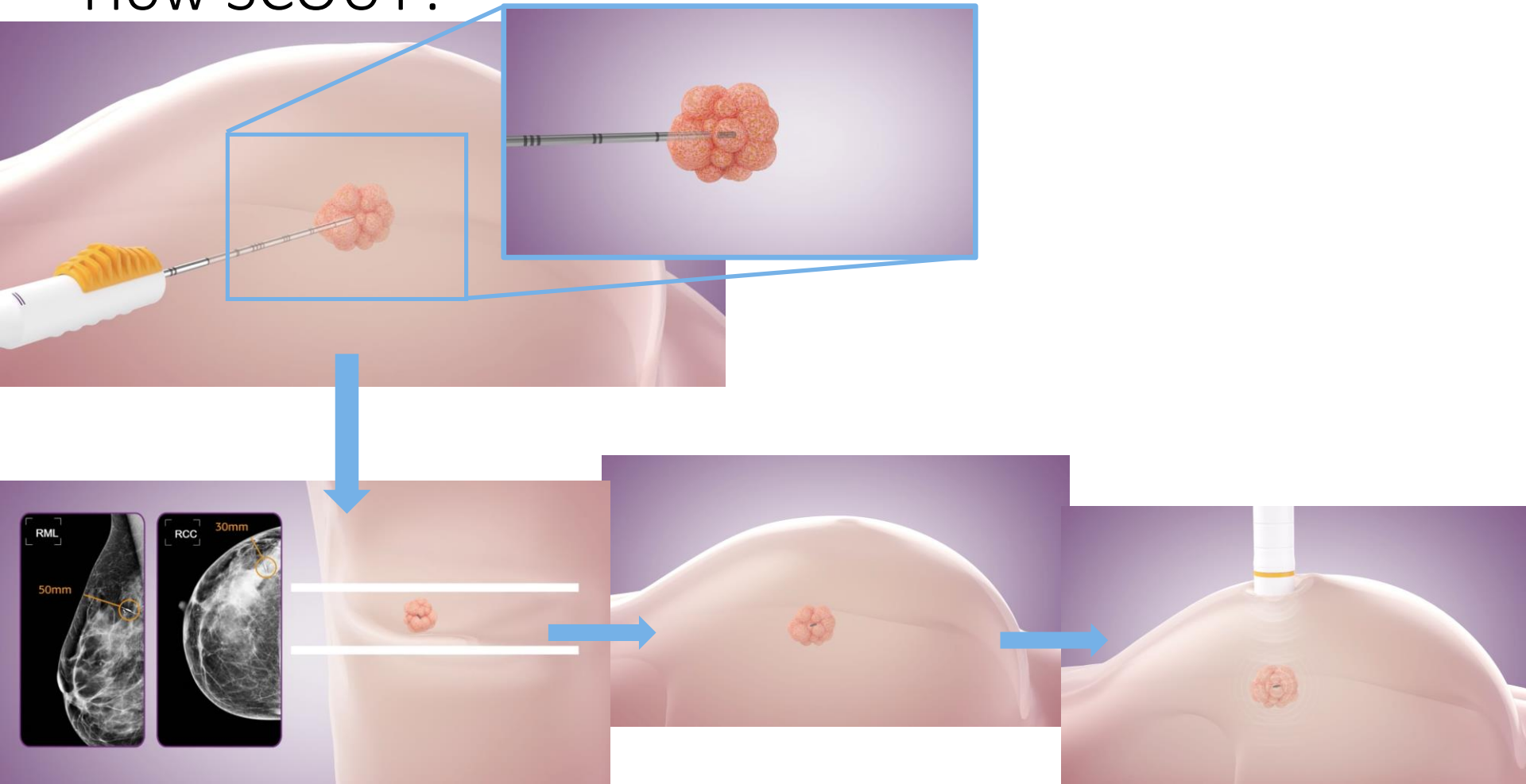

Module Outline

I. Case

II. Background

III. <u>Article Overview</u>

IV. Clinical Questions

V. Key Points

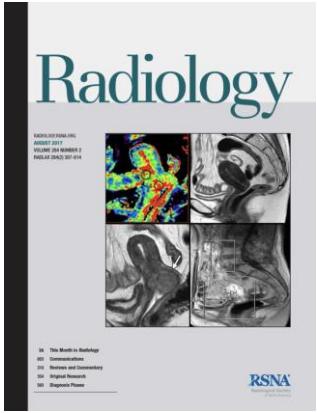

Article specifics

I. Purpose: To evaluate outcomes of Savi Scout reflector-guided localization and excision of breast lesions by analyzing reflector placement, localization, and removal, along with target excision and rates of repeat excision

II. Journal: *Radiology*, published online April 21, 2017

III. Study type: single-institution retrospective review

IV. # cases: 123 reflectors placed in 111 breast targets in 100 patients; 20 patients had 2-3 reflectors placed for either bracketing or multiple lesions

V. Data: Intraop reflector localization (y/n) and removal (y/n); target to reflector distance; reflector depth; pathologic analysis; re-excision rates

Study cohort

- 100 patients had Scout localization prior to BCT
  - June 2015 to May 2016
- Inclusion criteria:
  - Women
  - 18 years or older
  - Nonpalpable breast lesion
    - With planned surgical excision with preoperative image-guided localization with mammography or ultrasonographic (US) imaging was planned
  - Lesion depth was less than 4.5 cm
  - No nickel allergy

Materials and Methods

- Single-institution retrospective review of 100 patients Savi Scout localization from June 2015 to May 2016
- Reflectors were placed 0-8 days before surgery
  - Recorded any OR delays that caused by reflector placement
  - Placed by one of five breast radiologists via mammogram or US guidance
    - Transcutaneous detection determined in the radiology department the day of placement via a handpiece-and-console system
    - Placement confirmed by mammogram, with measurement of distance from both the reflector to the skin and from reflector to the lesion
- Reflectors removed surgically by two breast surgeons
  - Confirmed in OR via console/handpiece system and radiography
  - Distance between reflector and target specimen were recorded
  - Specimen pathology margins and target were reviewed

Example of Scout Placement

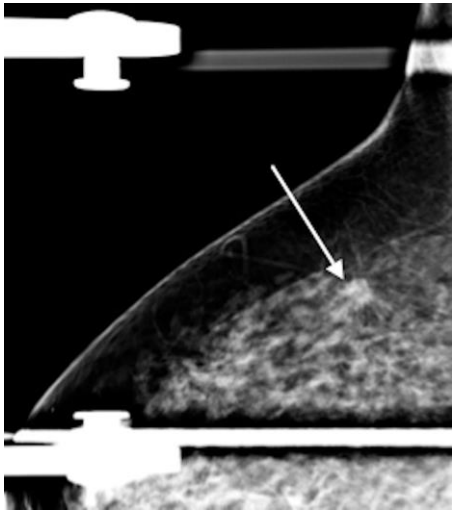

Left mediolateral oblique spot compression view of a 0.9 cm spiculated mass, biopsy revealed invasive ductal carcinoma (arrow).

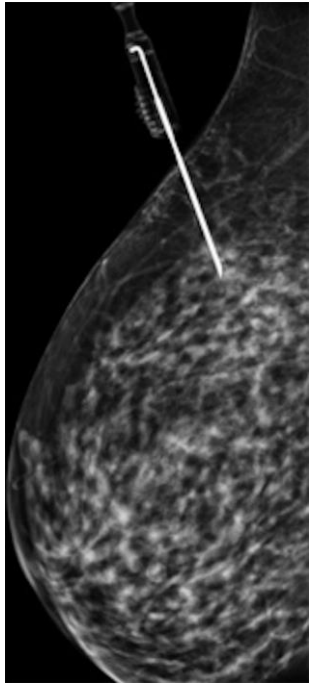

Mammography-guided localization of the mass and S-shaped clip.

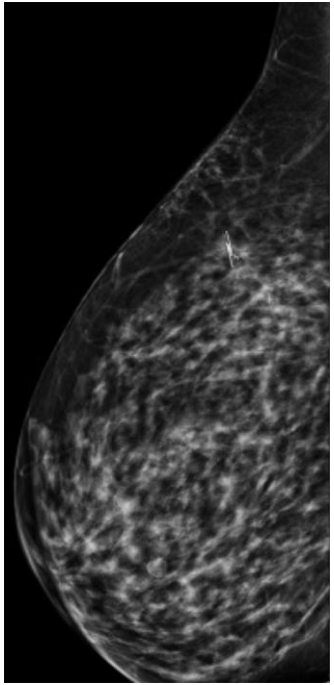

Reflector deployed within the mass, immediately adjacent to the clip.

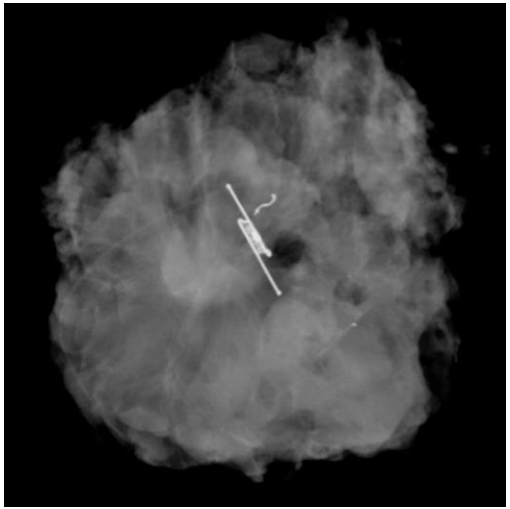

Radiograph of the specimen shows the spiculated mass, clip, and reflector.

Mango et al.

Back to Case: Post Scout Placement Mammogram

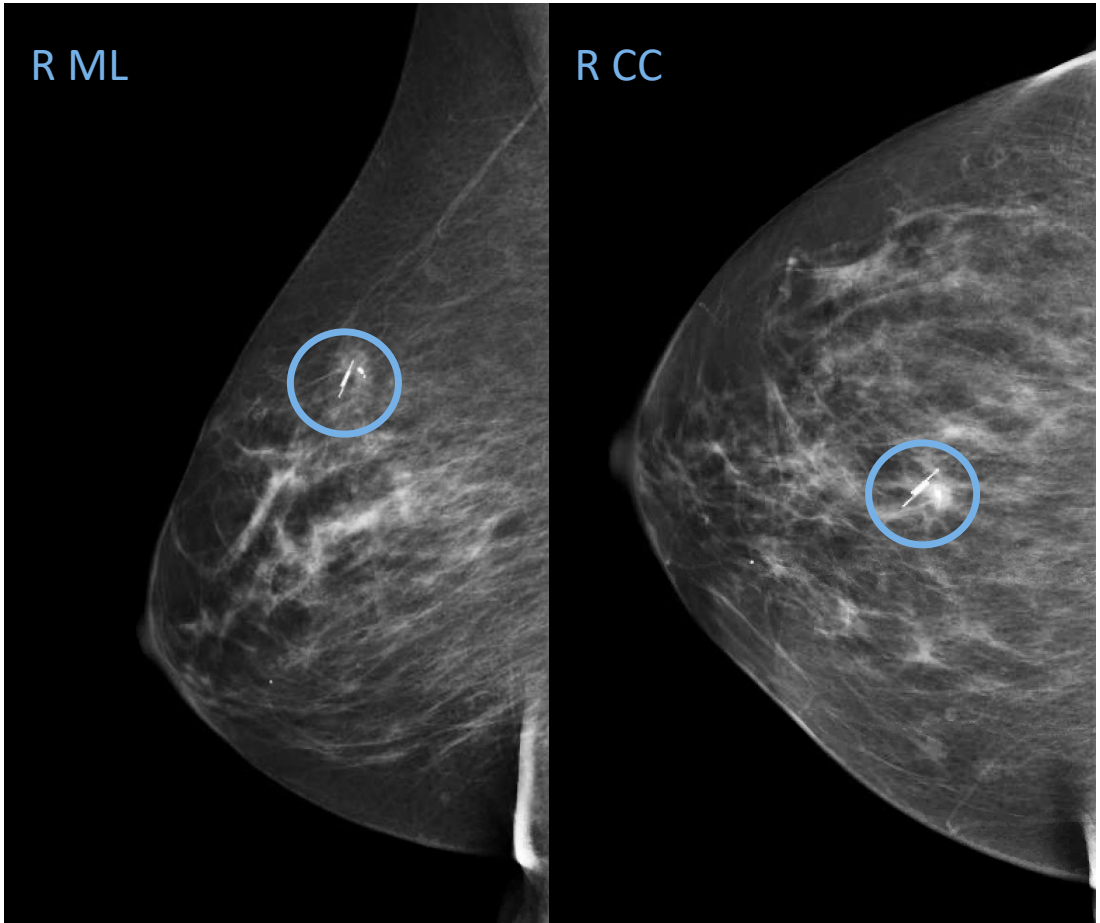

Results

- 100 women
  - Mean age, 56.4 years; age range, 24–82 years
- Reflector placement
  - Reflectors were placed on average within 0.3 cm (0–1.8 cm) of the target
  - Average placement prior to OR, 2.2 days; median, 1 day
  - Localized 111 breast lesions, with 123 reflectors placed
    - 80 patients had one reflector placed, 17 patients had two reflectors placed, and 3 patients had three reflectors placed
      - 10 patients required bracketed localization
        - >1 reflector placed, requested by the surgeon if the targeted area for excision was greater than 2 cm
    - 40 via US; 83 via mammogram

Results

- Surgical Pathologic Analysis
  - 54 of 110 malignancies
    - Average size, 1.0 cm; range, 0.1–5 cm
    - 35 invasive ductal carcinomas, 1 invasive lobular carcinoma, 17 ductal carcinomas in situ, and 1 papillary carcinoma
    - 4 of these had positive margins requiring re-excision
  - 32 of 110 high-risk lesions
  - 24 of 110 benign lesions

Results

- OR reflector findings
  - No reflector damage/transection
  - 5 of 110 radiographs of the specimen showed increased distance between the reflector and the target of more than 1.0 cm (range, 1.1–2.6 cm), compared to day-of-placement imaging
    - Hematoma was identified as the cause of migration in 3 of these 5 patients
  - On the day of the surgical procedure, the surgeon had difficulty obtaining a signal transcutaneously before incision in 3 patients
    - Following skin incision, an audible signal was detected in all cases

- No reflector-related or post-surgical complications found

Discussion

- 7.4% positive margin rate, 18.5% close margin rate (<1 mm margins)
  - Comparable to radioactive seed localization and better than reported for wire localization (with positive margins in 12%–60% of cases)
  - All bracketed cases had **clear margins**
    - Important for large lesions where patients are also likely undergoing oncoplastic mastopexy – re-excision not possible
- No OR delays
  - Uncoupled Radiology, Surgery days
- No external component
- Learning curve for radiologists and surgeons
  - Requires joint discussion on adoption

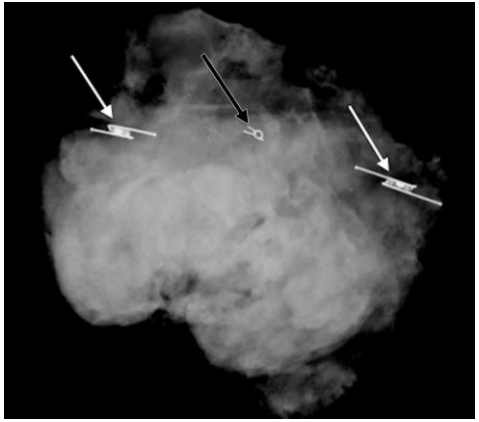

Bracketed lesion with two Scout reflectors bracketing a clip

Mango et al.

But wait . . . (Limitations)

- Single-institution study
- Selection bias possible
  - Patients were individually selected for Scout by the surgeon after consultation with the radiologist
- Studies have shown difficulty detecting Scout at lesions deeper than 4.5 cm
- Post-biopsy hematoma can potentially displace the Scout
- Inability to reposition the reflector after deployment
- More expensive than wire localization and radioactive seeds
  - Reducing OR delays may mitigate this

Case Resolution (to this point)

Negative margins

SLNBx with no carcinoma identified

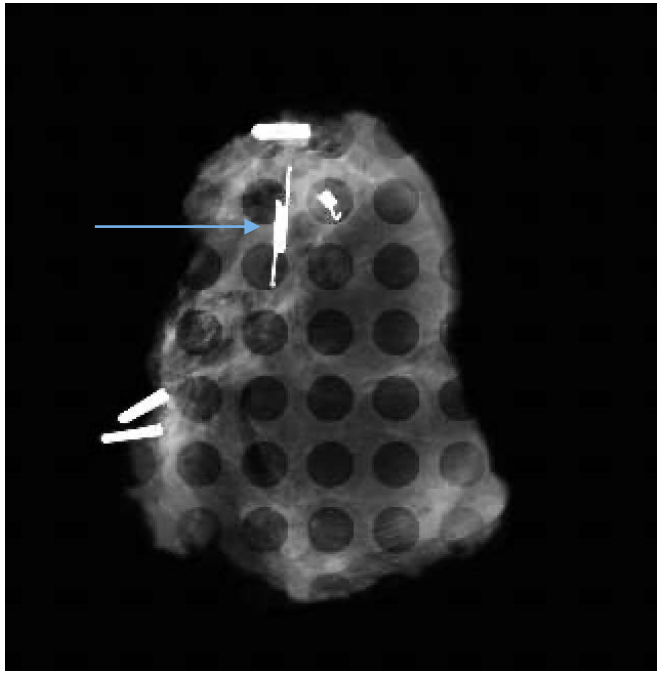

Excised surgical specimen from right breast, including pre-operatively placed Scout reflector (and previously placed coil clip)

Module Outline

I. Case

II. Background

III. Article Overview

IV. <u>Clinical Questions</u>

V. <u>Key Points</u>

Q & A Session with Author

- What methods can we employ to localize a breast mass?
  - Why SCOUT?
  - Is one method better than another?
- How does SCOUT compare to other new forms of localization?
  - Magseed, etc.

Key points

- Localization of a non-palpable lesion is important for surgical removal of the entire tumor in breast conserving therapy
  - Good localization minimizes rate of re-excision due to positive margins
  - Requires image-guidance
- Historically, wire localization has been the standard of care
  - External component, OR delays, risk of fracture, influences operative entrance
- Scout localization provides an effective alternative
  - Not radioactive, no external component, flexible insertion date

References

Anatomy of the Breast | Memorial Sloan Kettering Cancer Center. Accessed August 8, 2021. https://www.mskcc.org/cancer-care/types/breast/anatomy-breast

Mango VL, Wynn RT, Feldman S, et al. Beyond Wires and Seeds: Reflector-guided Breast Lesion Localization and Excision. *Radiology*. 2017;284(2):365-371. doi:10.1148/radiol.2017161661

BIRADS-Reference-Card_web_F.pdf. Accessed August 9, 2021. https://drive.google.com/viewerng/viewer?url=http%3A//msrads.web.unc.edu/files/2019/08/BIRADS-Reference-Card_web_F.pdf&embedded=true

Problem-Based Learning in Breast Imaging - BI-RADS® Mastery | Rise 360. Accessed August 8, 2021. https://rise.articulate.com/share/bS27LUcfiXC-qaKVmF83Cxvg5aUL2eo0#/lessons/2_4q1yHH-zwkzq0h7ATypKS-e3xdnPt3

SCOUT® Radar Localization. Merit Medical. Accessed August 8, 2021. https://www.merit.com/merit-oncology/localization/breast-soft-tissue-localization/scout-radar-localization/

References

Lyons TG. Targeted Therapies for Triple-Negative Breast Cancer. *Curr Treat Options in Oncol*. 2019;20(11):82. doi:10.1007/s11864-019-0682-x

Triple receptor negative breast cancer | Radiology Reference Article | Radiopaedia.org. Accessed August 11, 2021. https://radiopaedia.org/articles/triple-receptor-negative-breast-cancer?lang=us

Triple-Negative Breast Cancer: Overview, Treatment, and More. Breastcancer.org. Published July 29, 2021. Accessed August 11, 2021. https://www.breastcancer.org/symptoms/types/triple-negative

Themes UFO. Wire Localized Breast Biopsy. Basicmedical Key. Published July 24, 2016. Accessed August 8, 2021. https://basicmedicalkey.com/wire-localized-breast-biopsy/