ORIGINAL ARTICLE ■ *Health Services Research and Policy*

Go to page 1

Restricting Daily Chest Radiography in the Intensive Care Unit: Implementing Evidence-Based Medicine to Decrease Utilizationt

Editor's Choice

SA-CME

VISUAL ABSTRACT

Jinel Scott, MD, MBA[a], Stephen Waite, MD[b,c], Alexandra Napolitano, MD, MS[d]

Credits awarded for this enduring activity are designated "SA-CME" by the American Board of Radiology (ABR) and qualify toward fulfilling requirements for Maintenance of Certification (MOC) Part II: Lifelong Learning and Self-assessment. To access the SA-CME activity visit https://cortex.acr.org/Presenters/CaseScript/CaseView?Info=yjfDipbcANPw4V%2bKd4mEliAA74C7%2fqEsqj6dju1XLZA%253d. SA-CME credit for this article expires February 29, 2024.

Stacie Stallings, MS4

6/1/2021

Learning objectives

By the end of this journal club, participants will be able to…

1. Predict the cost of a chest radiograph in the Intensive Care Unit (ICU)

2. Understand the importance of obtaining “buy-in” with a multidisciplinary team

3. Determine what interventions require a portable chest radiography in the ICU

4. Determine ICU patient benefits from decreased chest radiography

Module outline

I. <u>Case</u>

II. Background

III. Article Overview

IV. Clinical Questions

V. Key Points

Case presentation

30yoF G3P2 at 24wks with PMH of asthma presents to the ED with cough and shortness of breath over the past two months. She states she has noticed that it's harder to take in deep breaths, she easily becomes fatigued with little activity, and she has sputum with coughing. She assumed her symptoms were due to her advancing pregnancy until she noticed blood in her sputum recently. She states that she has tried to use an albuterol inhaler, but she was unable to achieve relief. She has no recent illness, no COVID-19 exposures, no sick contacts, and no other alarming symptoms. Her pregnancy has been uneventful, she has no relevant family history, and she does not use tobacco or vaping products.

Physical Exam: She appears comfortable and breathing well. Sinus Tachycardia to the 120s, BP 120/70, RR 18, SpO2 100%, Temp 37.1. Heart is tachycardic, but regular rhythm. Lungs are CTAB, no wheezes, no rhonchi.

Notable Labs & Studies: WBC 20.1, ECG shows sinus tachycardia, new right axis deviation, and T waves present in inferior and lateral leads

Shared decision making led to obtaining a CTA Chest with contrast due to her presentation with tachycardia, dyspnea, hemoptysis, and an abnormal ECG which established a high pretest probability of a pulmonary embolism. The benefits of the study outweighed the risks to the patient and her unborn child.

Case imaging

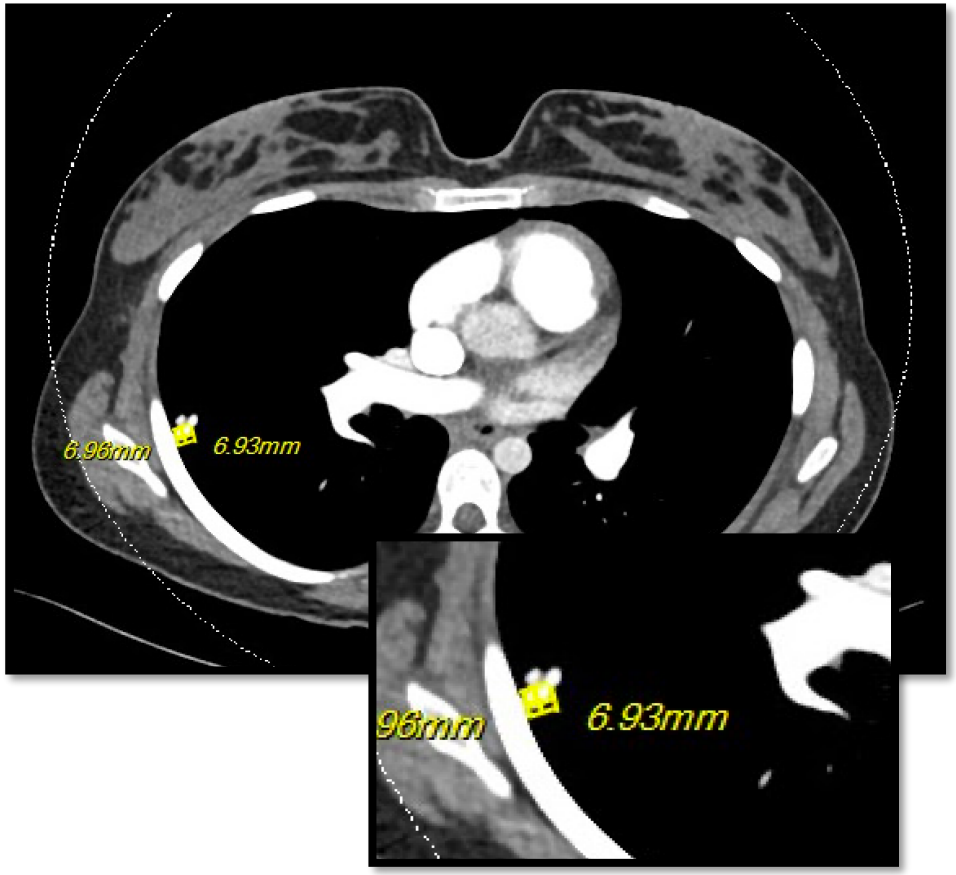

CTA Chest Pulmonary Embolism Protocol:

No evidence pulmonary embolism.

Lateral RML showed an opacified serpiginous pulmonary artery distally with a vascular nidus measuring 8 x 7 x 7mm with dilated feeding pulmonary artery and draining pulmonary vein, consistent with pulmonary arteriovenous malformation (AVM).

Case progression

- Pt admitted to MFM antepartum service and Interventional Radiology performed pulmonary angiogram and embolization with plugs and coils.
- OB, pulmonary, cardiology, and hematology teams were consulted. A TTE and right heart catheterization were performed and showed severe pulmonary hypertension with pulmonary artery systolic pressure ~75mmHg. The patient was moved to CICU for monitoring and treatment for pulmonary hypertension pending delivery. As gestation progressed, a multidisciplinary plan was established to induce labor in the CICU and to perform an assisted delivery in the operating room with cardiac surgery team standing by for possible ECMO cannulation intervention if the patient decompensated.
- At 34wks gestation, the patient was induced and delivered in the operating room. After delivery of the placenta, the patient experienced refractory hypotension and a PEA arrest which required emergent ECMO cannulation. The patient was transferred to the CTICU.
- Hospital course: POD 1 bedside chest washout, POD 2 attempted chest closure and L pleural chest tube placement, POD 4 R VA cannula replaced, CT Abd Pelvis showed free fluid mixed with hemoperitoneum and AVM in her uterus.
- Plan: POD 9 Protek Duo (RVAD) placement and attempt chest closure. Consideration for lung transplant expedited.

Case imaging






Total number of radiograph images (XR and CT) throughout 70 days since admission: 28

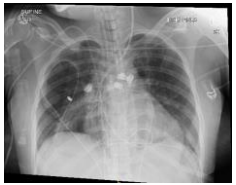


Total number of CT scans: 3





Total number of abd XR: 4

Total number of pCXR: 21





Locations:

Prior to CTICU: 4

OR suite: 2

CTICU: 15 (within 9 days ICU admit)



Case imaging

DAY	Type of Imaging	Noted Indications	Impression/Remarkable Findings
Admission	CT Chest	Diagnostic (R/O PE)	2.5cm lobulated soft tissue density structure over RML zone; no pneumothorax
Admission	CXR	Diagnostic (R/O PE)	Pulmonary AVM
Day 5	CXR		Post IR embolization
Day 43	CXR	CVC R IJ line check	Appropriate placement
Day 60	CXR	CVC L IJ line check	Appropriate placement
Perioperative	CXR	OR Incorrect surgical count protocol	No radiopaque opaque foreign object
Post-op ICU	CXR	ICU Admission	Enteric tube placement (recommend advancement), new patchy right basilar opacities
	Abd. XR	ICU Admission & enteric tube placement	Recommend tube advancement, R chest tubes and mediastinal drains in place. L CVC with tip in mid SVC, ECMO cannula with tip in R atrium, PA catheter with tip coiled at right ventricle, nonobstructive bowel gas pattern.
POD1	CXR		Increasing airspace opacities in bilateral lower lungs, concerns for infection or aspiration
POD1	CXR	Swan-Ganz catheter line check	Appropriately positioned
POD 2	CXR		Same as above regarding Swan-Ganz catheter
	CXR		Interval ECMO cannula exchanged, L apical CT placed
POD3	CXR		Increased airspace opacities in LLL, small L pleural effusion
	Abd. XR	Abdominal pain	Enteric tube should be advanced 10cm
	CXR		Lungs worsening
	Abd. XR	Enteric tube advancement check	Appropriately positioned
	Abd. XR		Same as above
POD4	CXR		Lungs worsening, pleural opacity in L hemithorax
	CXR		OR decortication, L hemithorax w/decreased opacity and L CT and mediastinal drain replacement
	CT Chest	Concerns for RP bleed	Sequela of median sternotomy with multiple tubes and lines, consolidate and ground glass opacities in bilateral lung fields, small bilateral pleural effusions, small pericardial effusion
	CT Abd	Same as above + abd distention	Prominent vascular structures within anterior wall concerning for AVM; moderate free fluid in abd/pelvis with superimposed hemoperitoneum
POD5	CXR		Moderate located left pleural effusion
POD6	CXR		Left pleural effusion increased in size
	CXR	OR Incorrect surgical count protocol	No change
POD 7	CXR		Similar/slight improved peripheral LUL consolidation, similar appearing consolidation of LLL
	CXR		No change
POD8	CXR		Slight increase opacities RML and RLL, slight improved aeration to L lung, slight improved/trace L pleural effusion
POD9	CXR		Stable lung volume, mild pulmonary edema slightly increased

Clinical question

In the Intensive Care Unit patient population, why is there a protocol for daily portable chest radiography and what would be the effects of decreased utilization?

Module outline

I. Case

II. Background

III. <u>Article Overview</u>

IV. Clinical Questions

V. Key Points

Daily Portable Chest Radiography (CXR)

- A portable digital X-ray system is moved into a patient's room, a film plate is placed under the patient and the x-ray beam comes from the anterior to the posterior (AP) approach. Often used when patients are critically ill and unable to stand.
- Average effective dose 0.1 mSv, but can range from 0.05-0.24 according to literature
- The American College of Radiology (ACR) stopped recommending daily CXR in 2008 and changed its stance to "usually not appropriate" in 2011 and 2014 after research showing no impact on preventing adverse outcomes.
- The 2020 revised edition of the ARC Appropriateness Criteria states: The strategy of ordering daily routine chest radiographs for critically ill and mechanically ventilated patients is slowly changing from daily chest radiographs to on-demand radiographs only.
- Estimated cost to perform single chest radiographic examination at the study hospital: $15.87

Module Outline

I. Case

II. Background

III. <u>Article Overview</u>

IV. Clinical Questions

V. Key Points

Article specifics

- Purpose: To use evidence-based medicine to decrease the utilization of routine chest radiography in adult intensive care units and used time-driven activity-based costing to demonstrate cost savings.
- Journal: Journal of American College of Radiology
- Study type: Performance improvement project
- # cases: All patients in the MICU and SICU of KCH from Jan – Dec 2019
- Data: Considered patient intubation status, location, number of CXRs
  - Timed process map for portable chest radiography (CXR)
  - Time-driven activity-based costing (TDABC)
  - Capacity Cost Rate and Monthly Capacity Cost rate of a Radiology Tech (RT) to establish Cost of Performing Portable CXR

Study cohort

I. All patients within the KCH MICU and SICU were monitored for the number of portable CXRs they received from January to December 2019, with the implementation taking effect in the month of June.

Materials and Methods

- Medical ICU (MICU) and surgical ICU (SICU) units within Kings County Hospital (KCH), an urban, level 1 trauma center in Brooklyn, NYC. KCH is 1 of 11 hospitals in the largest public health system in the country, NYC Health and Hospitals.
- A multidisciplinary team including radiology, nursing, medicine, and surgery team members created an educational campaign targeting residents and critical care physicians to emphasize daily CXR rarely change management and has significant disadvantages in patient care.
- The standard practice of daily CXR orders on ICU admission were discontinued. The need for CXR was determined only after examining the patient or with clinical interventions.
- The team launched a Choose Wisely campaign and changed the workflow so that CXR were only ordered after clinical determinations of necessity.
- A timed process map was created to illustrate the steps in performing a CXR.
- Time-driven activity-based costing (TDABC) was used to determine the unit of cost of performing a single portable chest radiographic examination at the institution was $15.87.

Results

- The team aimed for a 5% reduction of ICU portable CXR utilization between June and December 2019; there was a 37% decrease in the average monthly number of portable chest radiographic examinations performed (733 to 463).

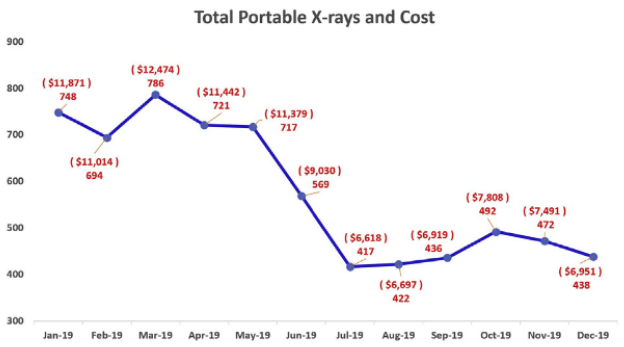

Fig 2. Total outcome measure chart. This chart illustrates the total number of chest radiographic examinations performed in the intensive care units each month with the associated cost before and after the intervention started in June. After the intervention, a sustained decrease in the number of radiographic examinations performed was observed.

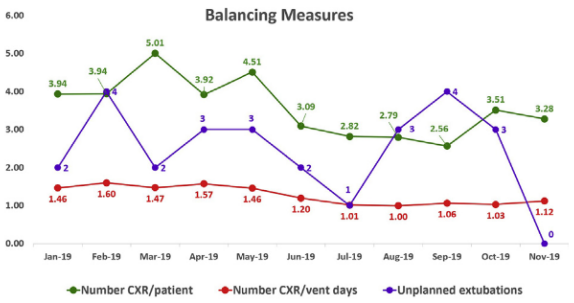

Fig 3. Balancing measure chart: number of chest radiographic examinations (CXR) per ventilator days, number per patient, and unplanned extubations. After the intervention in June, the number of chest radiographic examinations per ventilator day and the number of examinations performed per patient decreased, without an increase in the average number of unplanned extubations.

- After the implementation, there were no increases in ventilator days or unplanned extubations.

Results (cont.)

- In the MICU, CXR utilization decreased 43% with a monthly average of 370 to 177 .
- In the SICU, CXR utilization decreased 30% with a monthly average of 361 to 253.

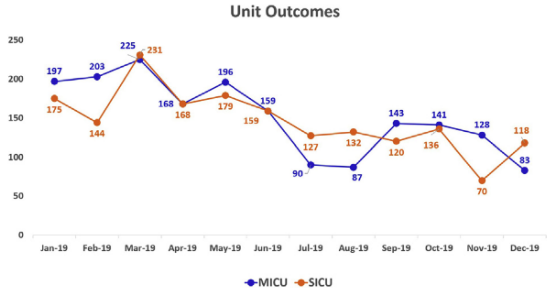

Fig 4. Unit-specific outcome measure chart. The number of chest radiographic examinations performed in the medical intensive care unit (MICU) and surgical intensive care unit (SICU) both decreased after the intervention in June.

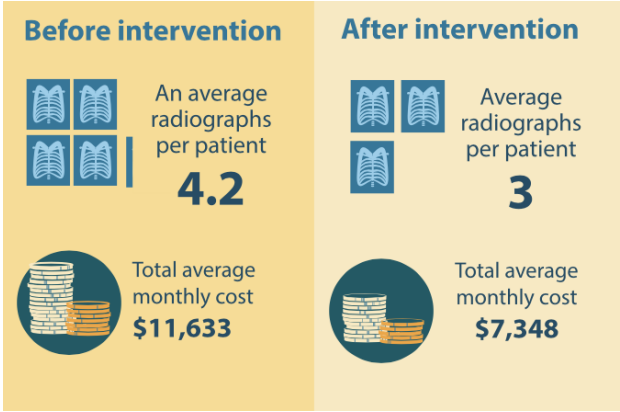

- The 37% decrease translates into a total average monthly savings of $4285 monthly.

Discussion

- A restrictive approach to ordering portable CXR in the adult ICUs decreased the utilization of portable CXR in the adult ICUs by 37% without any increase in complications or unplanned extubating.
- Decreased: radiation exposure, patient sleep disturbances, risk for tube dislodgement with positioning patients for CXR, risk of accidental device removal, and imaging studies with no influence on patient care.
- Outcomes directly related to radiology department assembling multi-disciplinary team and establishing “buy-in” from other health care providers.
- The 11 critical care faculty members participated 100%, which helped implementation. However, the EHR did not allow a change to stop the daily CXR order set from being ordered.

Discussion

- They used the TDABC to build upon previous studies which created an efficient way to express an accurate accounting of costs within the specific institution.
- Due to the success of the project, the other 10 acute care hospitals within the enterprise have updated their practice to resemble a restrictive portable CXR ordering model.
- With the model, the intuition could save $4,000 monthly, $48,000 annually, or $5 million over the next ten years.

But wait . . . limitations

- Availability of data: The data was reported every 4 to 6 weeks which decreased engagement and sustainability.
- Education vs. Workflow: The data was not collected in manner that permits differentiation of impact of education and workflow of the EHR.
- COVID-19: The increase number of patients requiring critical care led to an increase in ICU locations, new/additional staffing, and workload demand.

Module Outline

I. Case

II. Background

III. Article Overview

IV. <u>Clinical Questions</u>

V. <u>Key Points</u>

Clinical questions now . . .

I. Do all ICU patients require daily chest radiographs?

II. When is an appropriate time in training to use a restrictive approach?

III. What should determine if a patient needs a chest radiograph? And should it be standardized?

IV. Should we remove daily order sets from the EHR?

V. How can we optimize efficient, purposeful CXR orders in the ICU?

ACR Appropriatenes Criteria for ICU Patients

Variant 1: **Admission or transfer to intensive care unit. Initial imaging.**

Procedure	Appropriateness Category	Relative Radiation Level
Radiography chest portable	Usually Appropriate	☢
US chest	May Be Appropriate (Disagreement)	O

Variant 2: **Stable intensive care unit patient. No change in clinical status. Initial imaging.**

Procedure	Appropriateness Category	Relative Radiation Level
Radiography chest portable	May Be Appropriate (Disagreement)	☢
US chest	Usually Not Appropriate	O

Variant 3: **Intensive care unit patient with clinically worsening condition. Initial imaging.**

Procedure	Appropriateness Category	Relative Radiation Level
Radiography chest portable	Usually Appropriate	☢
US chest	May Be Appropriate (Disagreement)	O

Variant 4: **Intensive care unit patient following support device placement. Initial imaging.**

Procedure	Appropriateness Category	Relative Radiation Level
Radiography chest portable	Usually Appropriate	☢
US chest	May Be Appropriate (Disagreement)	O

Variant 5: **Intensive care unit patient. Post chest tube or mediastinal tube removal. Initial imaging.**

Procedure	Appropriateness Category	Relative Radiation Level
Radiography chest portable	May Be Appropriate (Disagreement)	☢
US chest	Usually Not Appropriate	O

Key points

I. Multi-disciplinary “buy-in” team-based approach is invaluable to quality improvement project implementations.

II. Institutions can safely discontinue the protocol of daily ICU CXR with proper education and evidence-based guidelines.

III. With a single CXR cost of $15.87, an institution can save $4,000 monthly, $48,000 annually, or $5 million over the next 10 years.

References

- American College of Radiology. ACR Appropriateness Criteria. Intensive Care Unit Patients. https://acsearch.acr.org/docs/69452/Narrative/ . Accessed May 27, 2021.
- American College of Radiology. Chest Radiography. https://www.acr.org/-/media/ACR/Files/Practice-Parameters/Port-Chest-Rad.pdf . Accessed May 27, 2021.
- Clec'h C, Simon P, Hamdi A, et al. Are daily routine chest radiographs useful in critically ill, mechanically ventilated patients? A randomized study. Intensive Care Med 2008;34:264-70.
- Oba Y, Zaza T. Abandoning daily routine chest radiography in the intensive care unit: meta-analysis. Radiology 2010;255:386-95.
- *Radiation risk from medical imaging*. Harvard Health. (2020, January 29). https://www.health.harvard.edu/cancer/radiation-risk-from-medical-imaging.
- Scott, J., Waite, S., & Napolitano, A. (2021). Restricting Daily Chest Radiography in the Intensive Care Unit: Implementing Evidence-Based Medicine to Decrease Utilizationt. *Journal of the American College of Radiology*, *18*(3), 354–360. https://doi.org/10.1016/j.jacr.2020.05.035