RADY 403 Case Presentation

Susana Bracewell, MS4
May 21, 2021

UNC SCHOOL OF MEDICINE Radiology

Focused History

- 9-year-old male with past medical history significant for obesity
- Presented to clinic with left hip pain over the past two months
  - Describes the pain as non-radiating, dull, and aching
  - No history of preceding trauma
- Furthermore, the patient recently began limping
- On exam, he was afebrile
- CBC, ESR, and CRP were unremarkable

Causes of Hip Pain in a Child

Infectious

- Septic arthritis
- Lyme disease
- Osteomyelitis
- Psoas abscess
- Pyomyositis
- Spinal epidural abscess
- Appendicitis
- Abdominal/pelvic abscess

Inflammatory

- Transient synovitis
- Spondyloarthropathy
- Juvenile idiopathic arthritis
- Infectious/post-infectious arthritis
- Other rheumatologic conditions (e.g., SLE, MCTD, vasculitis, dermatomyositis, CRMO, localized scleroderma, FMF)
- Arthritis associated with gastrointestinal conditions (e.g., IBD, celiac disease)
- Idiopathic chondrolysis of the hip

Mechanical or Orthopedic

- Slipped capital femoral epiphysis
- Legg-Calvé-Perthes disease
- Secondary avascular necrosis
- Femoral stress fracture
- Muscular strain
- Iliac apophysitis
- Snapping iliopsoas tendon
- Trochanteric bursitis
- Acetabular labral tear
- Femoroacetabular impingement
- Apophyseal avulsion fracture with apophysitis

Neoplastic

- Osteoid osteoma
- Leukemia
- Solid tumor (primary or metastatic)
- Pigmented villonodular synovitis

Other

- Sickle cell disease
- Gaucher disease
- Neuromuscular disorders (e.g., muscular dystrophy)

ACR Appropriateness Criteria

Scenario	Procedure	Adult RRI	Peds RRI	Appropriateness Category	
Hip pain, chronic, first study	Radiography pelvis	0.1-1mSv ☢☢	0.03-0.3 mSv [ped]..	Usually appropriate	
	Radiography hip	1-10 mSv ☢☢☢	Null	Usually appropriate	
	US hip	O	O	Usually not appropriate	
	Image-guided anesthetic +/- corticosteroid injection hip joint or sur..	Null	Null	Usually not appropriate	
	MR arthrography hip	0 mSv O	0 mSv [ped] O	Usually not appropriate	
	MRI hip without IV contrast	0 mSv O	0 mSv [ped] O	Usually not appropriate	
	MRI hip without and with IV contrast	0 mSv O	0 mSv [ped] O	Usually not appropriate	
	Bone scan hip	1-10 mSv ☢☢☢	Null	Usually not appropriate	

Scenario	Procedure	Adult RRI	Peds RRI	Appropriateness Category	
Ped <=5yo, acute limp, hip pain	Radiography hip	1-10 mSv ☢☢☢	Null	Usually appropriate	
	MRI hip without IV contrast	0 mSv O	0 mSv [ped] O	Usually not appropriate	
	US hips	0 mSv O	0 mSv [ped] O	Usually not appropriate	
	MRI hip without and with IV contrast	0 mSv O	0 mSv [ped] O	Usually not appropriate	
	CT hip with IV contrast	1-10 mSv ☢☢☢	Null	Usually not appropriate	
	CT hip without IV contrast	1-10 mSv ☢☢☢	Null	Usually not appropriate	
	CT hip without and with IV contrast	1-10 mSv ☢☢☢	Null	Usually not appropriate	
	3-phase bone scan pelvis and lower extremity	Null	3-10 mSv [ped] ☢☢☢☢	Usually not appropriate	

Therefore, two views of the pelvis were obtained.

List of Imaging Studies

- AP Radiograph of Pelvis
- Lateral Radiograph of Left Hip

AP Radiograph of Pelvis

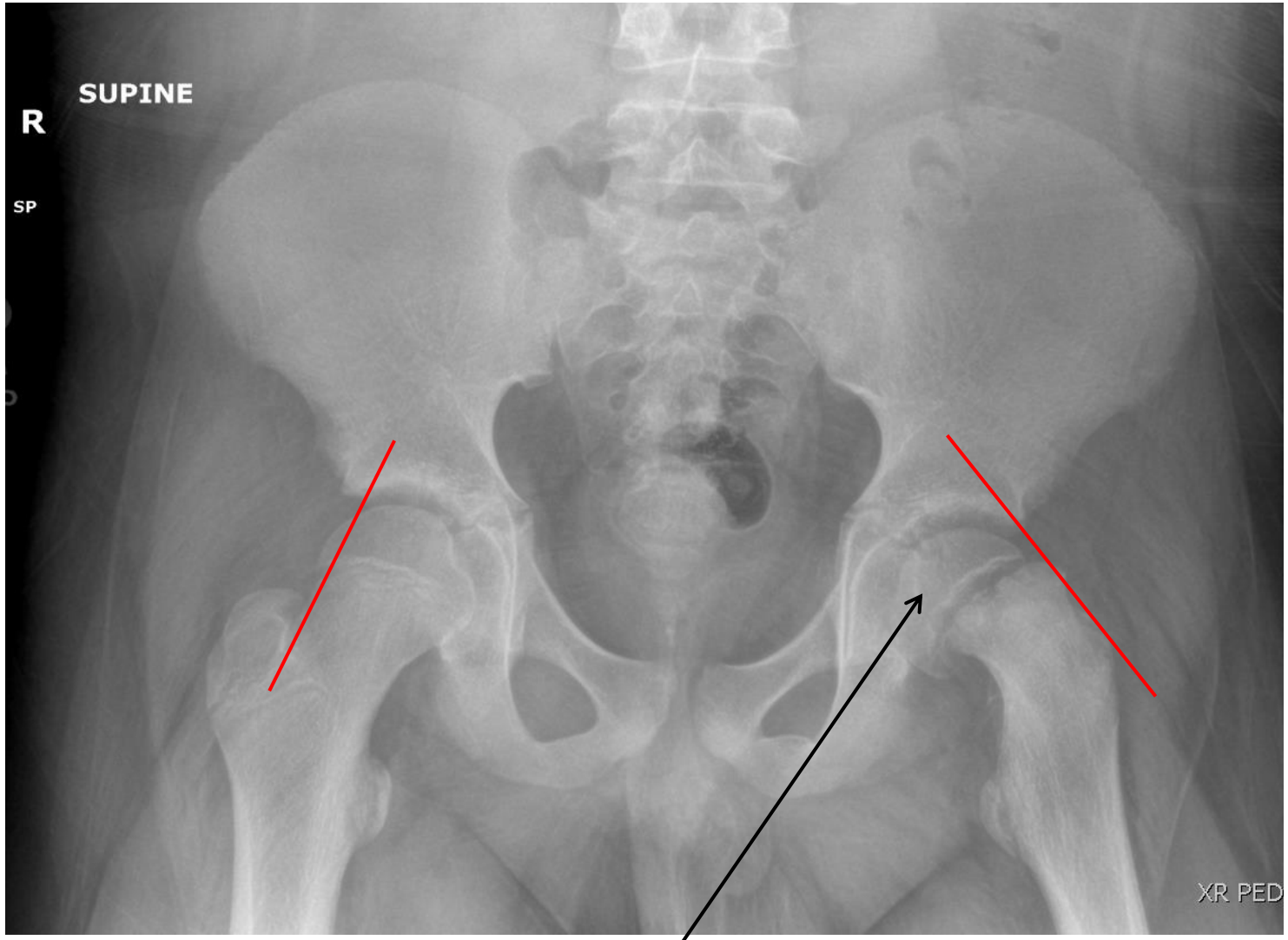

Normal Klein's line (a line along the superior edge of the neck of the femur that intersects the lateral part of the superior femoral epiphysis).

Proximal femoral capital epiphysis

Abnormal Klein's line where the epiphysis is malaligned with no intersection of the capital femoral epiphysis.

Lateral Radiograph of Left Hip

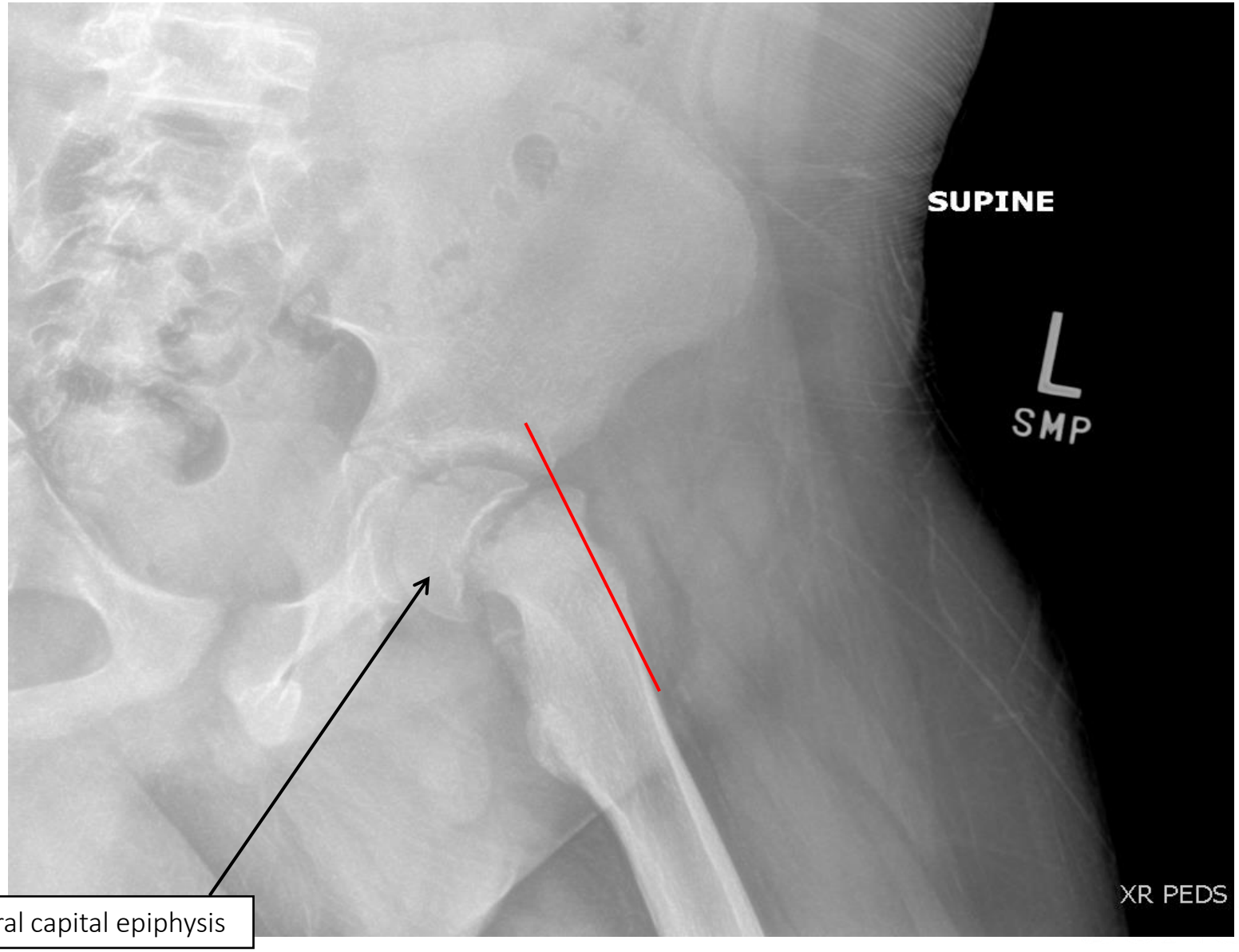

Widening and malalignment of the left capital femoral epiphysis consistent with a mild slipped capital femoral epiphysis.

Proximal femoral capital epiphysis

UNC SCHOOL OF MEDICINE Radiology

Slipped Capital Femoral Epiphysis (SCFE) – Definition

- Also called slipped upper femoral epiphysis (SUFE)
- Type I Salter-Harris fracture through the proximal femoral physis
  - Fracture that is completely contained within the physis
- Loss of structural integrity along the physis results in displacement of the femoral neck and the appearance of a posteriorly and inferiorly displaced epiphysis

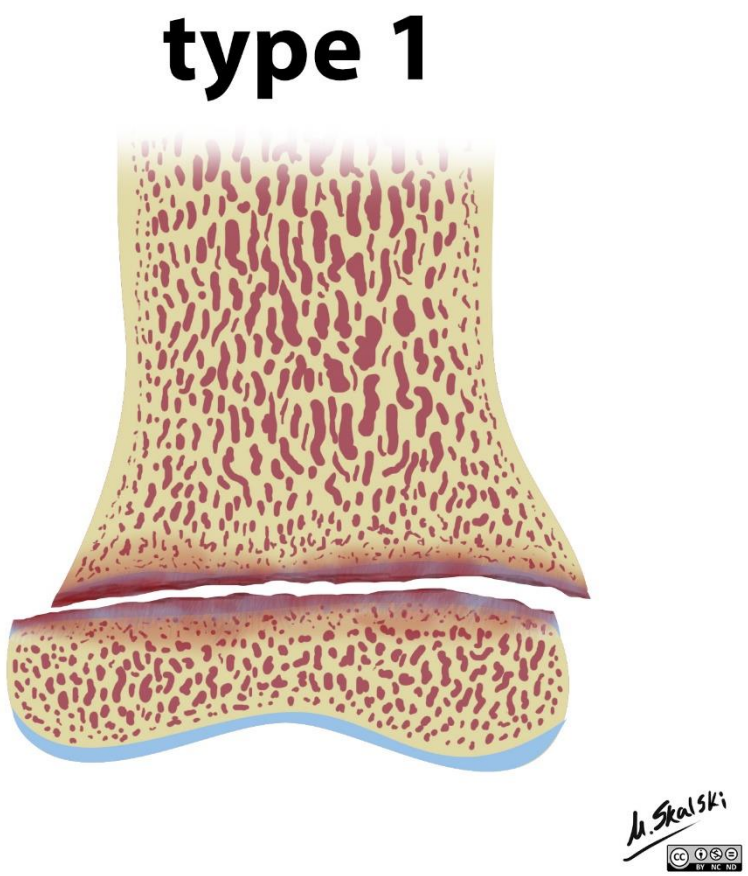

Case courtesy of Dr Matt Skalski, Radiopaedia.org, rID: 27144

Clinical Features

- Affects 1 to 6 in 20,000 patients with a 2:1 male predominance
- Bilateral in up to one third of patients
- Most common in patients 10 to 15 years of age
  - Due to the combination of increased biomechanical stress and a weakened perichondrial ring during puberty from increased growth and hormonal changes
- Risk factors include endinocrinopathies (such as hypothyroidism, renal disease, and hypogonadism), biochemical stress (such as trauma and obesity), and African or Hispanic ancestry
- Acute SCFE is associated with an unstable joint and severe pain of less than 3 weeks' duration whereas pain is mild and may subside with rest in a chronic SCFE
- In stable SCFE, the patient maintains the ability to bear weight, which is lost in unstable SCFE

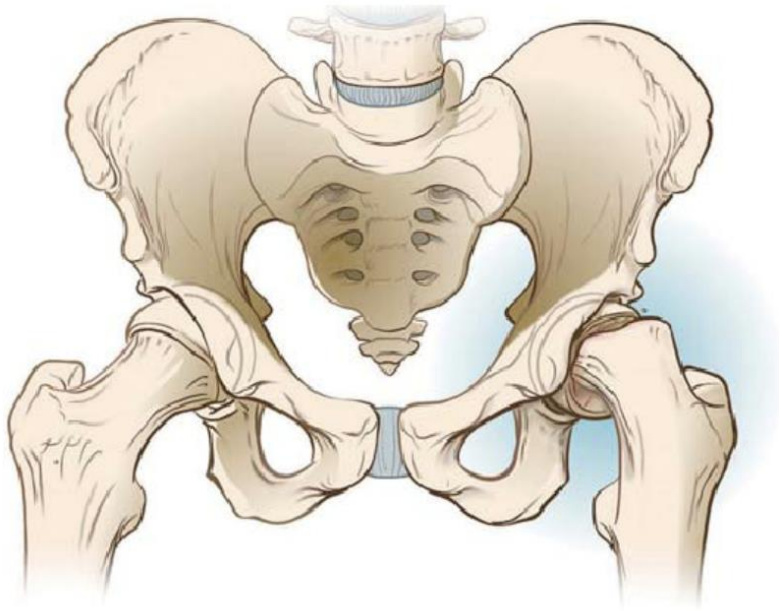

Image via Reid, J, Davros, W, Paladin, A, Lee, E, & Carrico, C (Eds.). (2014). *Pediatric radiology*. ProQuest Ebook Central https://ebookcentral-proquest-com.libproxy.lib.unc.edu

Radiographic Findings

- Widening, lucency, and irregularity of the physis
- Sclerosis of the femoral neck
- Bone remodeling
- Displacement of the epiphysis from the metaphysis anteriorly or posteriorly on lateral view
- Osteonecrosis, chrondrolysis, and osteoarthritis in the hip joint
- Klein's line does not intersect with the epiphysis on frontal view
  - In the normal AP view, a line drawn along the superior femoral neck intersects the lateral portion of the femoral head

Case courtesy of Dr Hani Makky Al Salam, Radiopaedia.org, rID: 9298

Correct interpretation of the radiographs is critical. In as many as **25 percent** of patients whose SCFEs are missed, radiographs were misinterpreted, or the diagnosis could not be established with the radiographs that were obtained.

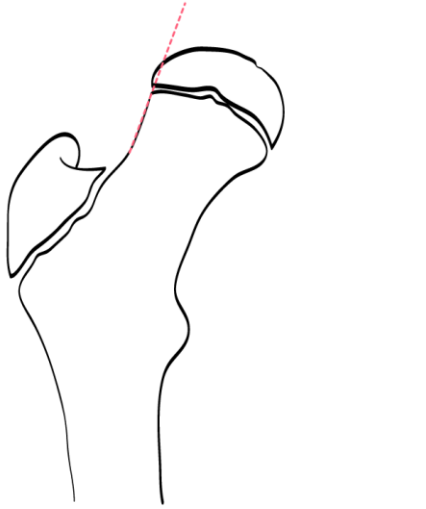

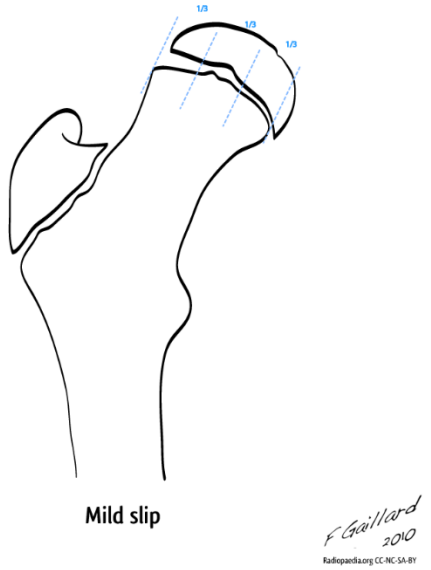

Case courtesy of Assoc Prof Frank Gaillard, Radiopaedia.org, rID: 8004

Severity Grading

Severity based upon radiographic findings determines prognosis.

- Mild: Displacement of epiphysis <1/3 of diameter of femoral neck in the AP view or <30 degrees of displacement on true lateral projection
- Moderate: Displacement of epiphysis >1/3 but <1/2 of diameter of femoral neck in AP view or 30 to 50 degrees on true lateral projection
- Severe: Displacement of epiphysis >1/2 of diameter of femoral neck on AP view or >50 degrees on true lateral projection

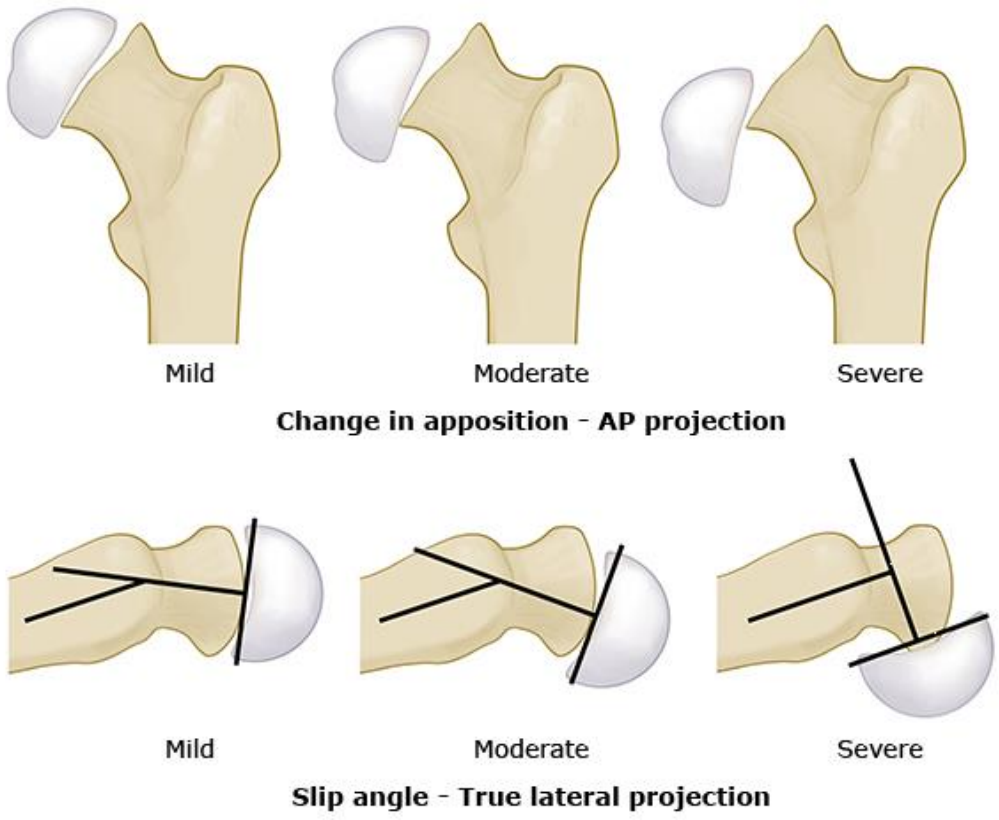

Image via Kienstra, AJ, & Macias, CG (2021). Evaluation and management of slipped capital femoral epiphysis (SCFE). Phillips, WA, & Singer, JI (Eds.), *UptoDate*. Available from https://www.uptodate.com/contents/evaluation-and-management-of-slipped-capital-femoral-epiphysis-scfe?csi=6870df90-0491-4ddf-850c-d60bb93ab3f2&source=contentShare

Management

- SCFE should be treated as an emergency upon diagnosis and confirmation by imaging
  - Children with SCFE should be made non-weightbearing and promptly referred to an orthopedic surgeon
- Surgery is the treatment of choice to prevent further slippage and promote physeal closure
  - Screw fixation is the most commonly used and widely accepted treatment
- Prophylactic pinning of the opposite hip is considered an option by some surgeons but is controversial

AP Radiograph of Pelvis

Back to our case…

Right hip is normally aligned.

Interval pinning of left hip. Fully threaded screw transversing the left femoral neck.

Lateral Radiograph of Left Hip

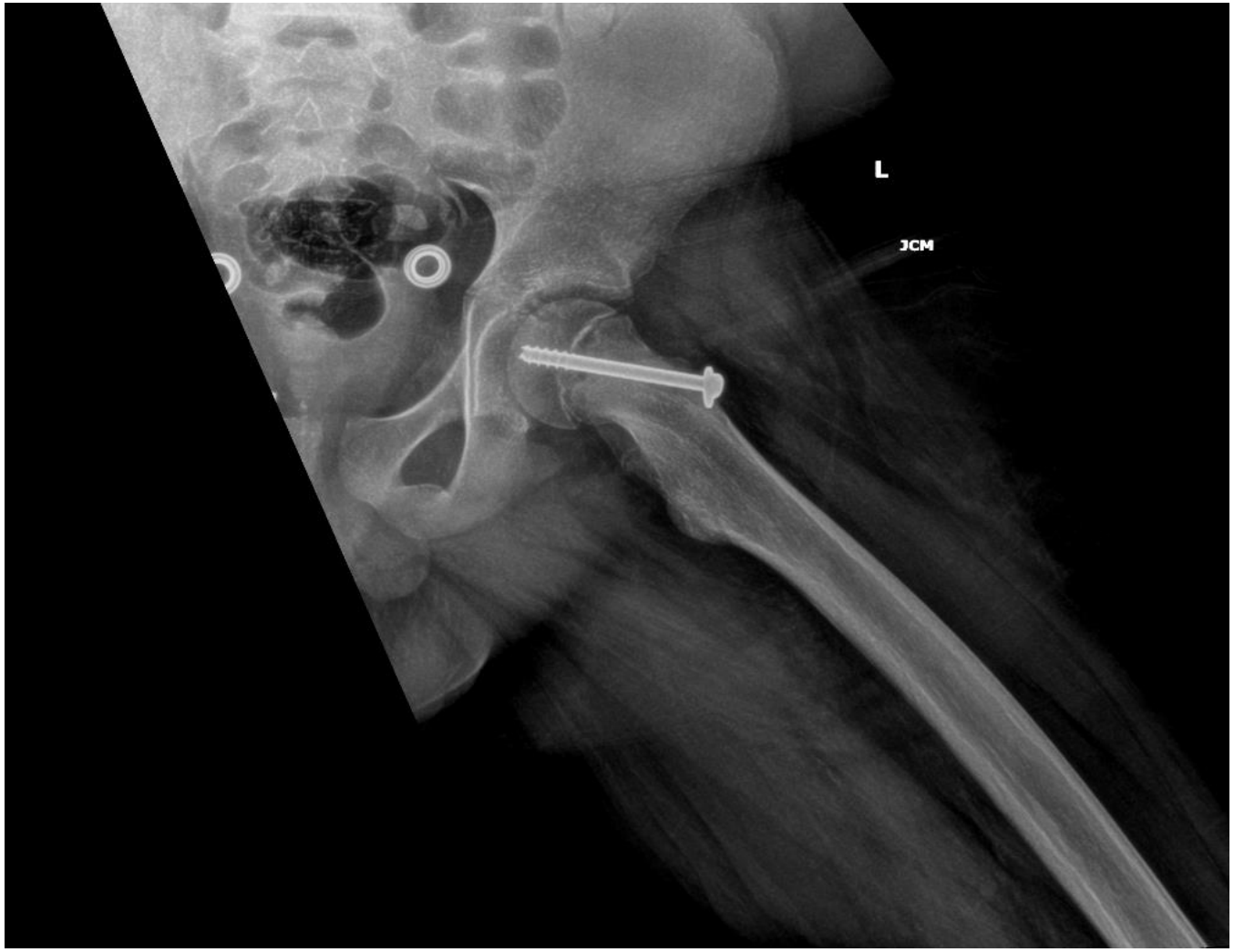

No adverse hardware features of left hip.

AP Radiograph of Pelvis

Two years later…

Patient has since developed right-sided SCFE. Interval pinning of right hip.

Fully threaded screw transversing the right femoral neck.

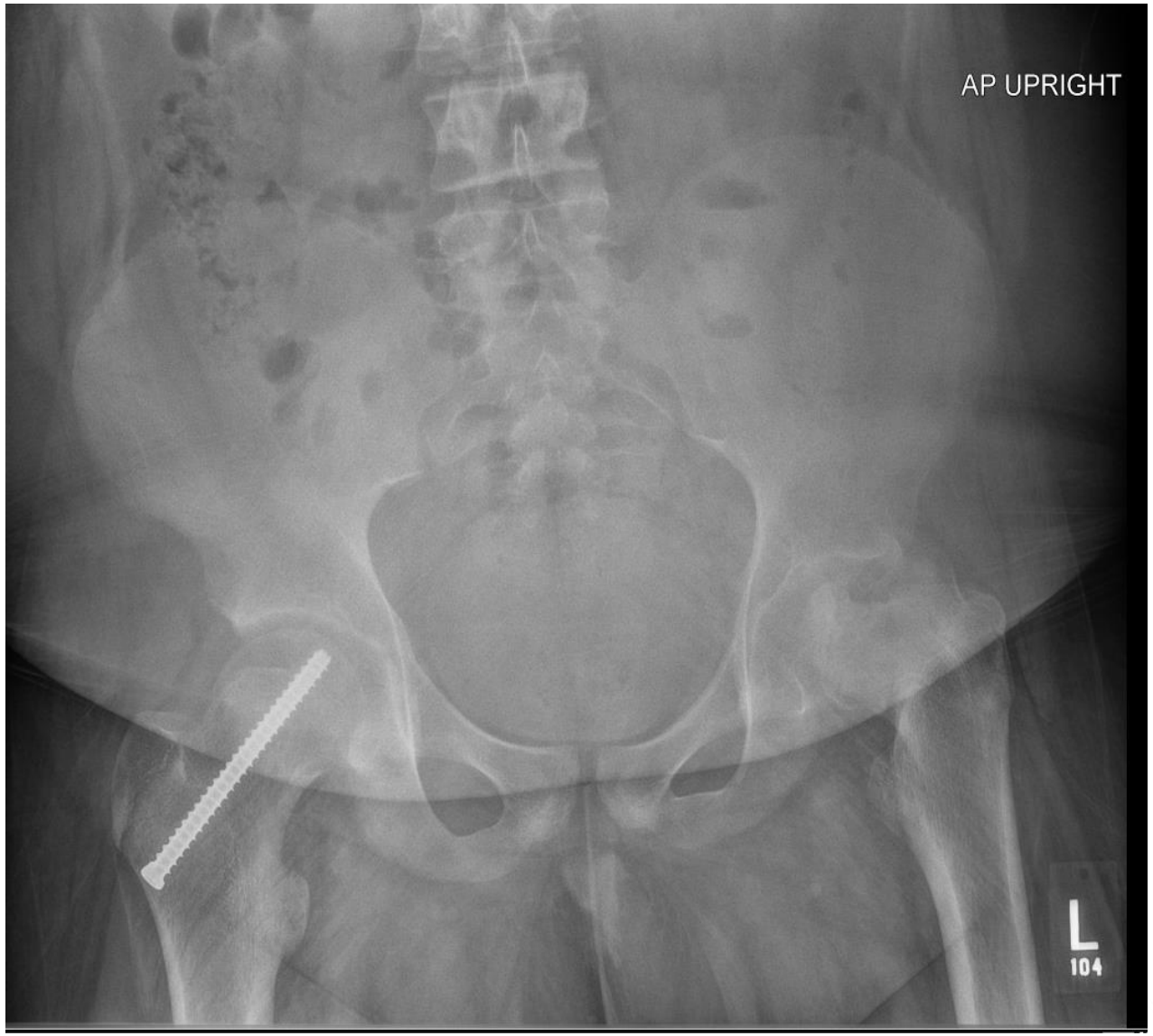

Interval removal of pin in left hip due to fixation failure.

Fragmentation and sclerosis of left proximal femoral epiphysis.

Lateral Radiograph of Hips

No adverse features of right hip.

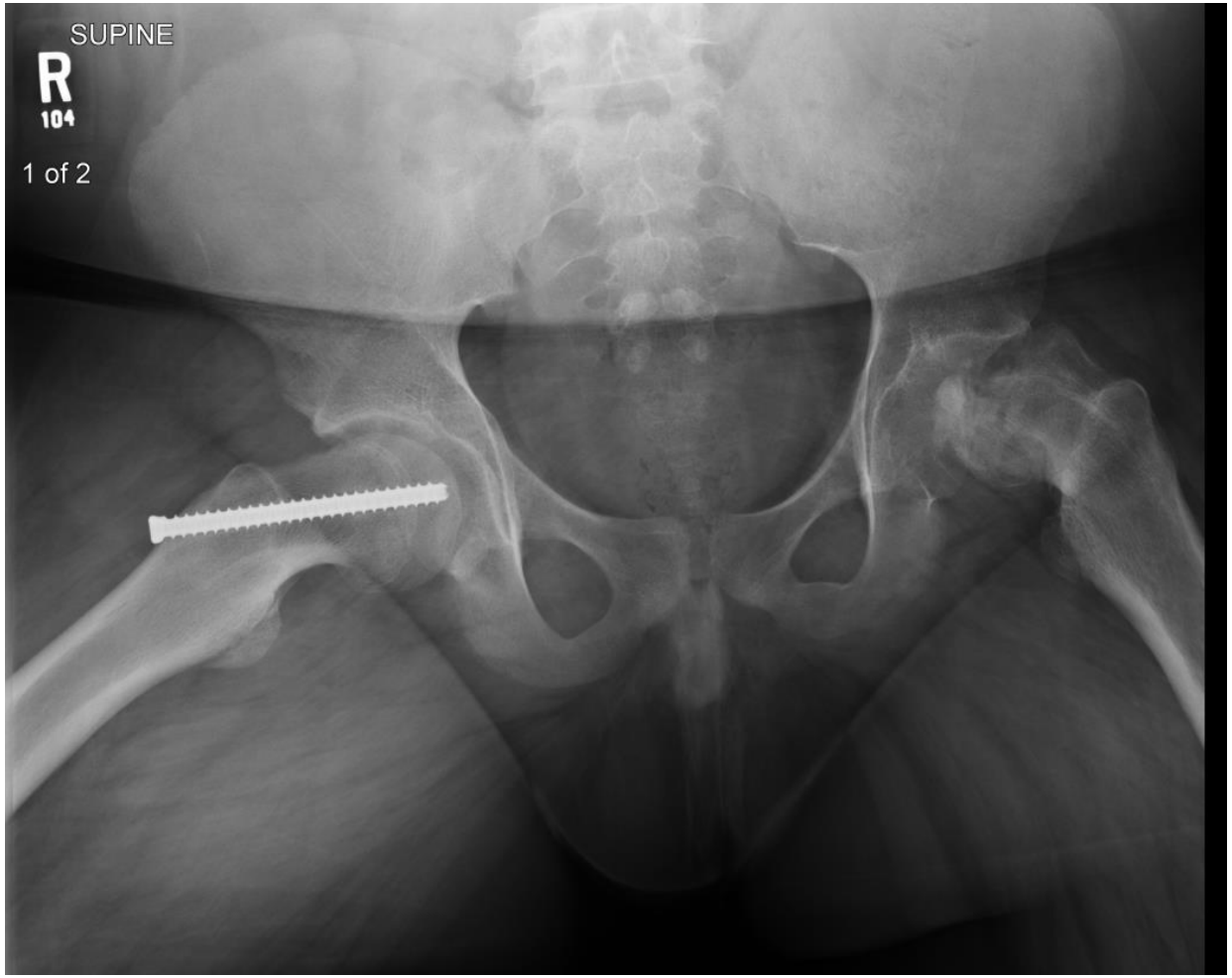

Stable alignment of left hip with elements of healing avascular necrosis.

Complications

- Avascular necrosis
  - The most serious complication and has the worst prognosis
  - May be a complication from an acute slip or surgical fixation
- Chondrolysis
  - Defined as narrowing of the joint space and loss of articular cartilage
- Femoroacetabular impingement
  - Abnormal contact between the proximal femoral metaphysis and the acetabular rim
- Osteoarthritis

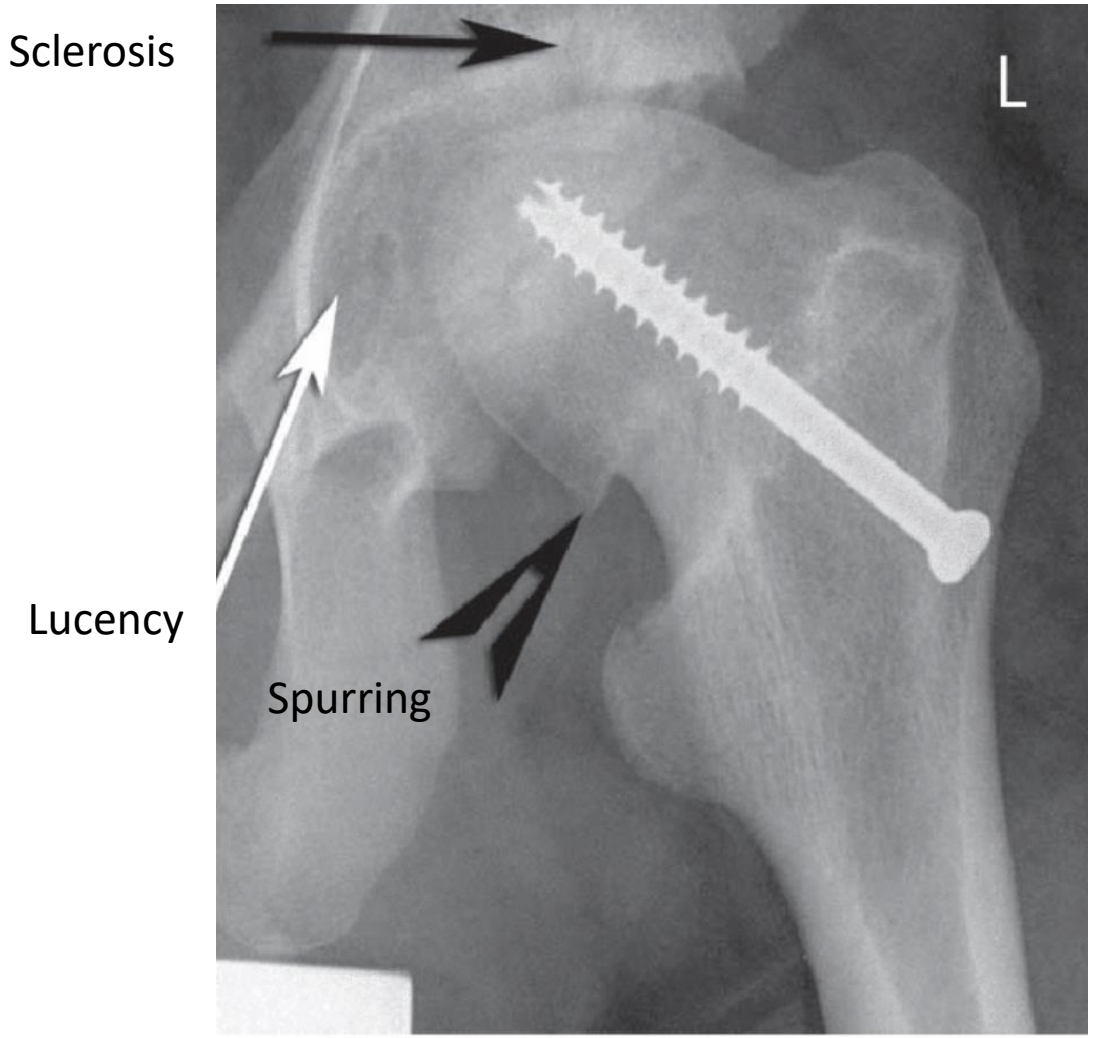

Image via Reid, J, Davros, W, Paladin, A, Lee, E, & Carrico, C (Eds.). (2014). *Pediatric radiology*. ProQuest Ebook Central https://ebookcentral-proquest-com.libproxy.lib.unc.edu

Key Points

- Approximately 2:1 male predominance
- Type I Salter-Harris fracture through physis
- Displacement of the metaphysis while the epiphysis remains within the acetabulum
- Risk factors include obesity, trauma, and endincrinopathies
- Common complications include avascular necrosis, chrondrolysis, and osteoarthritis
- Always obtain both AP and lateral views of the hips when suspicious for SCPE

References

- Nigrovic, PA. (2019). Approach to hip pain in childhood. JE Drutz, WA Phillips, & SC Li (Eds.), *UptoDate*. Available from https://www.uptodate.com/contents/approach-to-hip-pain-in-childhood?csi=b26d3ae2-95b3-4753-b567-2e8743048219&source=contentShare
- ACR Appropriateness Criteria. (2021). Retrieved May 18, 2021, from https://www.acr.org/Clinical-Resources/ACR-Appropriateness-Criteria
- Kienstra, AJ, & Macias, CG (2021). Evaluation and management of slipped capital femoral epiphysis (SCFE). Phillips, WA, & Singer, JI (Eds.), *UptoDate*. Available from https://www.uptodate.com/contents/evaluation-and-management-of-slipped-capital-femoral-epiphysis-scfe?csi=6870df90-0491-4ddf-850c-d60bb93ab3f2&source=contentShare
- Reid, J, Davros, W, Paladin, A, Lee, E, & Carrico, C (Eds.). (2014). *Pediatric radiology*. ProQuest Ebook Central https://ebookcentral-proquest-com.libproxy.lib.unc.edu