ELSEVIER

Journal of Vascular and Interventional Radiology

Available online 13 April 2021

In Press, Journal Pre-proof

Clinical Study

Response To Celiac Plexus Block Confirms Neurogenic Etiology of Median Arcuate Ligament Syndrome

Dennis A. Barbon MD [1], Richard Hsu MD, PhD [2], Josef Noga MD [2], Bryan Lazzara MD [2], Todd Miller MD [2], Brian F. Stainken MD

Show more

Eyad Atieh

April 20th, 2021

UNC SCHOOL OF MEDICINE Radiology

Learning objectives

By the end of this journal club, participants will be able to:

1. Develop a differential for chronic post-prandial abd pain
2. Define Median Arcuate Ligament Syndrome and identify a possible presentation.
3. Identify radiologic features of mesenteric vasculature on CT

Module Outline

I. <u>Case</u>

II. Background

III. Article Overview

IV. Clinical Questions

V. Key Points

Case presentation

26 yo F patient with a PMH of Ehlers-Danlos comes to your office with a 3-year history of intermittent epigastric pain that tends to occur after meals. She also notes an associated weight loss of 20 lbs over the past 3 years. Her pain is associated with nausea, NBNB emesis, and bloating. The pain is worse with fatty foods and relieved with bowel rest. The nausea is worse with any oral intake. She denies any diarrhea, hematochezia, or blood in her stool. She also denies smoking, illicit drug use. She drinks 1-2 drinks on the weekends with her friends.

Differential Diagnosis?

Differential Diagnosis

- Chronic pancreatitis
- Cholelithiasis
- Gastric outlet obstruction
- Gastroparesis
- Chronic intestinal ischemia

What do we want to know?

PMH, PSH, PE, Labs

- No significant PMH w/ exception of Ehlers-Danlos. No past surgical history.
- Physical exam was significant for mild epigastric tenderness but otherwise within normal limits.
- CBC, BMP, LFT's, Amylase, Lipase, ESR all WNL.
- Serum H. Pylori titer negative

Perhaps some imaging and more studies?

Imaging Studies and Results

- RUQ US showed insignificant liver hemangioma, no evidence of cholelithiasis.
- Gastric emptying showed minimal delay.
- Hepatobiliary scan showed minimal evidence of biliary dyskinesia w/ EF of 25% (normal >35%).
- EGD showed small hiatal hernia and erosive gastropathy, biopsy showed no abnormalities.
- Colonoscopy showed no abnormalities

Outside the Box Imaging

- Mesenteric ultrasound shows elevated celiac expiratory velocity of 323 cm/s in supine position, indicative of celiac stenosis.
- To confirm, a CTA was done showing celiac stenosis during the expiratory phase.

Abdominal Duplex Ultrasound

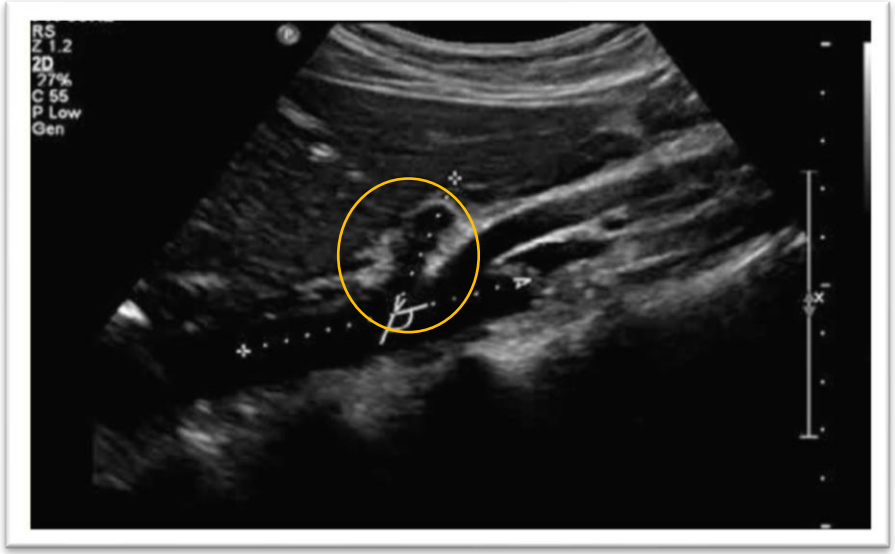

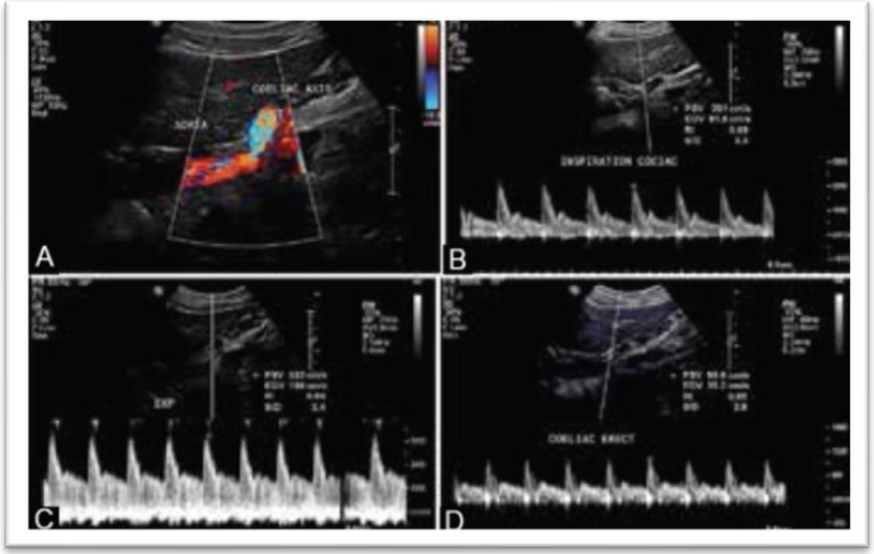

(A) Color Doppler USG shows an aliasing artifact. Spectral Doppler USG taken on (B) inspiration and (C) expiration. Significantly elevated peak systolic velocity is seen on expiration. Spectral Doppler measurements in erect position (D) show normal peak systolic and end-diastolic velocities

Case imaging

Figure 1a: Abdominal CTA, sagittal reformat, arterial phase during inspiratory phase demonstrates <50% stenosis of the celiac trunk.

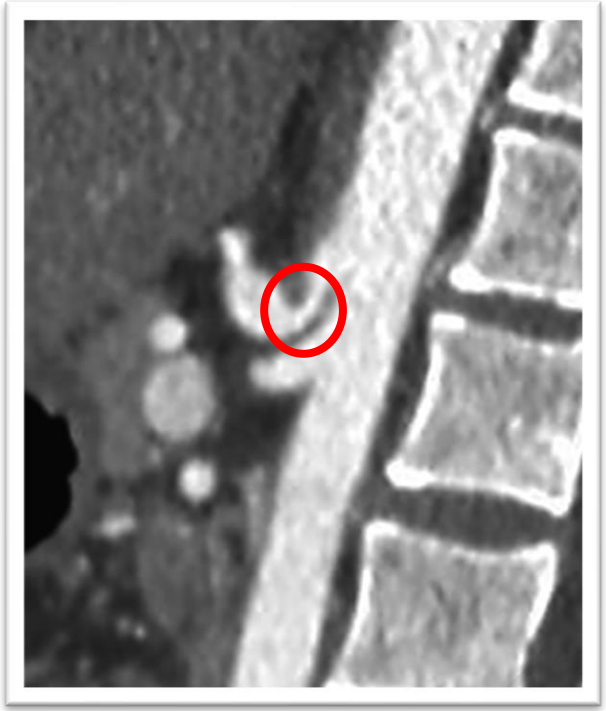

Figure 1b: Abdominal CTA, sagittal reformat, arterial phase during expiratory phase demonstrates MALS findings: respiratory variability accentuating a focal eccentric celiac artery stenosis attributed to impingement by the median arcuate ligament and celiac trunk hook-shape configuration.

Questions to consider: How do we confirm this is MALS? Will it respond to treatment?

It was initially assumed that the symptoms of MALS are a form of ischemic pain associated with celiac artery compression by the median arcuate ligament. However, an article in 2016 in the *Annals of Vascular Surgery* written by Weber et. al hypothesizes that MALS is a neurogenic phenomenon attributed to compression of the celiac plexus.

Module Outline

I. Case

II. **Background**

III. Article Overview

IV. Clinical Questions

V. Key Points

Median Arcuate Ligament Syndrome

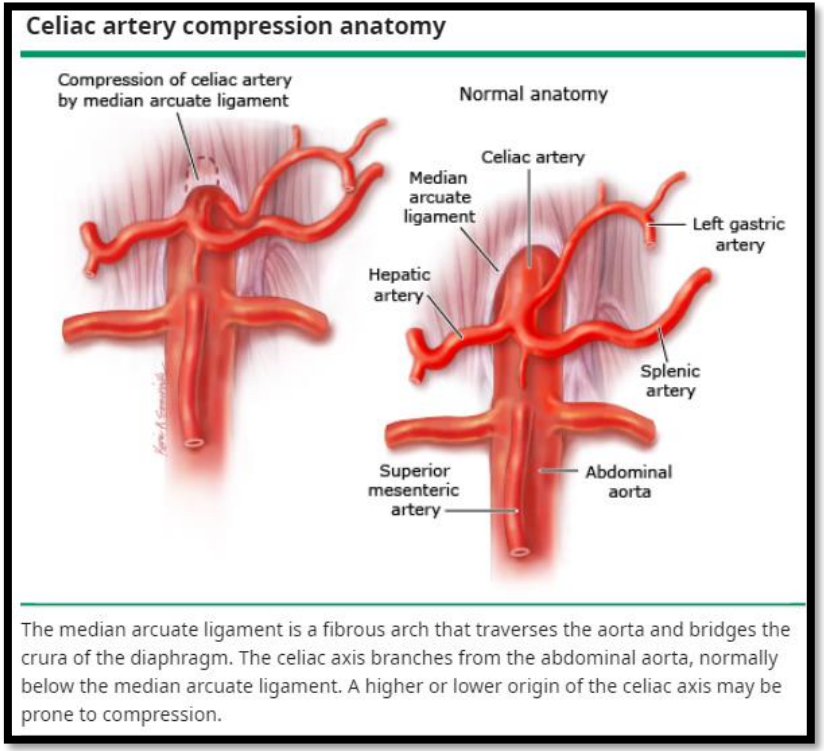

Image source: *Kim EN, Lamb K, Relles D, et al. Median arcuate ligament syndrome—Review of this rare disease. JAMA Surg 2016; 151:471. via UpToDate.*

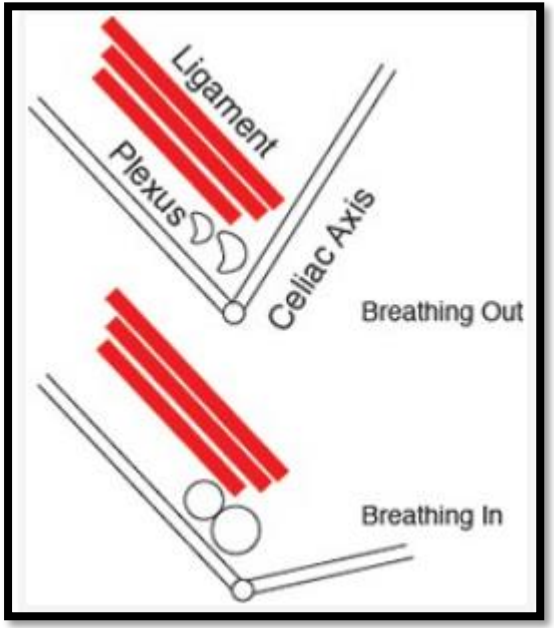

Image Source: Cleveland Clinic
https://my.clevelandclinic.org/health/diseases/16635-median-arcuate-ligament-syndrome-mals

MALS (cont'd)

- Clinical Features:
  - Fairly non-specific
  - Chronic post-prandial pain
  - Unintentional weight loss
  - N/V/D
  - ± Epigastric tenderness
  - ± Abdominal bruit
- Diagnostic Approach:
  - Absence of other explanation.
  - Duplex Ultrasound showing increased velocity in the celiac artery.
  - Duplex US showing increase in velocity with expiration.
  - Gastric Tonometry
  - Celiac Plexus Block
  - CTA showing stenosis
- Treatment:
  - Surgery (MAL release, decompression of celiac artery).
  - Long term neural ablation with ethanol is alternative
  - Ganglionectomy for refractory cases

Celiac Plexus Block

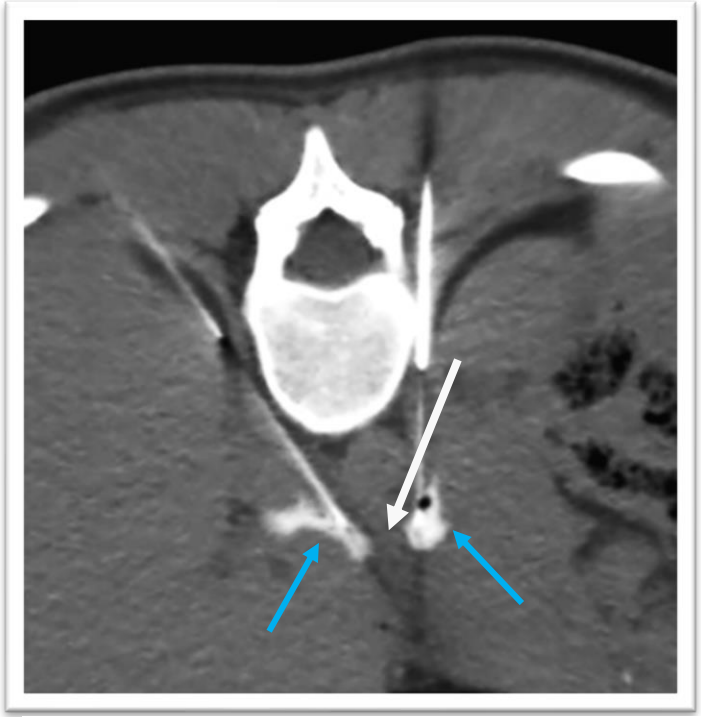

White arrows = celiac artery
Blue arrows = celiac plexus

Figure 2b: Prone, CT without IV contrast, axial image demonstrating co-axial, bilateral, posterior CPB with contrast injection dispersing in bilateral antecrural spaces.

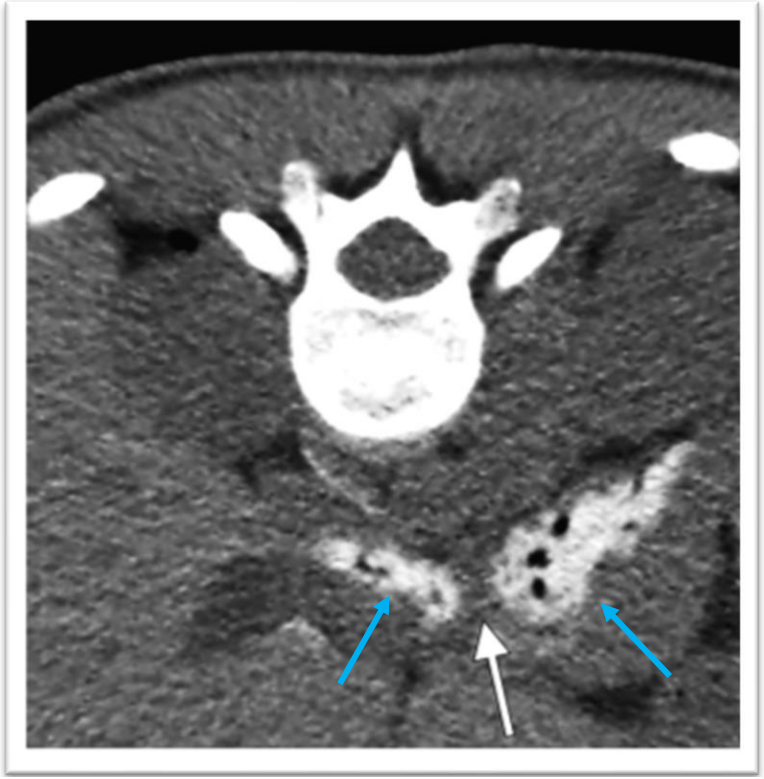

Figure 2c: Prone, CT without IV contrast, axial image demonstrating post-CPB contrast dispersal around the celiac artery (arrows).

Module Outline

I. Case

II. Background

III. <u>Article Overview</u>

IV. Clinical Questions

V. Key Points

ELSEVIER

Journal of Vascular and Interventional Radiology

Available online 13 April 2021

In Press, Journal Pre-proof

Clinical Study

Response To Celiac Plexus Block Confirms Neurogenic Etiology of Median Arcuate Ligament Syndrome

Dennis A. Barbon MD [1], Richard Hsu MD, PhD [2], Josef Noga MD [2], Bryan Lazzara MD [2], Todd Miller MD [2], Brian F. Stainken MD

Show more

Purpose: "To evaluate the response of Median Arcuate Ligament Syndrome (MALS) symptoms, including postprandial pain, nausea, and vomiting to celiac plexus block (CPB) and to correlate response with arterial anatomy."

Journal: Journal of Vascular and Interventional Radiology, 2021

Study Type: Retrospective Cohort Study

Study Cohort

Single institution, retrospective cohort of 96 patients with clinically diagnosed MALS that underwent 103 CT guided percutaneous CPB procedures.

Variables	Count (%)	Mean ± SD
Sex		
Male	21 (21%)	-
Female	75 (78%)	-
Age	-	26.7 ± 16.1 years
Pre-CPB Weight	-	60.8 ± 17.3 kg
Height	-	165 ± 10.2 cm
Pre-CPB BMI	-	22.2 ± 5.85 kg/m^2

Past Medical History		
Asthma	19 (19.8%)	-
Celiac Disease	6 (6.3%)	-
COPD	0 (0%)	-
Ehlers-Danlos	12 (12.5%)	-
Gastritis	10 (10.4%)	-
GERD	10 (10.4%)	-
Gastroparesis	9 (9.4%)	-
Hiatal Hernia	7 (7.3%)	-
Mast Cell Activation Syndrome	9 (9.4%)	-
POTS	27 (28.1%)	-
Past Surgical History		
Prior CPB	12 (12.5%)	-
Central Venous Catheter	6 (6.3%)	-
Cholecystectomy	8 (8.3%)	-
Diagnostic Laparoscopy	3 (3.1%)	-

Materials and Methods

- Study in Stamford, CT over 3 years from Jan 1, 2017 – April 3, 2020
- Exclusion criteria: patients with chronic abdominal pain with identifiable etiologies such as chronic mesenteric ischemia and gastric outlet obstruction.
- CPB procedure defined as weight-adjusted injection mixture of contrast medium, 1% lidocaine, 0.25% bupivacaine, and betamethasone. First 55% had mixture of anesthetics only, second 45% had mixture with steroid.
- Approach was either bilateral posterior (58%), unilateral posterior (40%), or anterior (2%).
- There were 3 possible distributions of anesthetic settling: all 4 quadrants (64%), bilateral lower quadrants (73%), and bilateral upper quadrants (74%).
- Completed CPB was considered contrast visualized in 2 or more quadrants.
- 5% of patients underwent general anesthesia, 39% received monitored anesthesia care, 56% received moderate sedation.

Materials and Methods

- Data collection was done through EMR review.
- Exposure variable for this cohort study was the presence of MALS anatomy on pre-CPB block CT, defined as one of the following:
  - Focal eccentric celiac artery stenosis
  - Celiac trunk arterial stenosis
  - Inferiorly displaced celiac trunk
  - Celiac trunk hook configuration
  - Celiac vessel collateralization
  - Celiac stenosis with respiratory variability
- 27% of patients were found to have at least one of these anatomical variants. 73% had normal vascular anatomy.

Materials and Methods

- Outcomes:
  - Pre- and Post-CPB self-reported linear pain score (NRS-11), ranging from 1-10. Post-CPB scoring was done immediately after recovering from sedation and ingesting foods known to elicit symptoms.
  - Change in self-reported pain score
  - Presence of post-CPB nausea and objective vomiting
  - Change in N/V symptoms
  - Technical success
- There were 7 repeat CPB procedures included in the statistical analysis.
- ANOVA was used to correlate pain score changes with anesthetic dispersal.
- Two-tailed t-test used to correlate pain score changes before and after CPB.
- 95% of patients were referred to vascular surgery for possible MAL neurolysis, and subsequently a two-tailed t-test was used to compare scores between surgery and no surgery groups.
- p-value set at 0.05.

Results

- Technical Success: 99% of CPB blocks were successful in dispersing anesthetic in proper area.
  - Technical complications: 4% minor adverse events, 1% moderate adverse events.
- Decrease in post-prandial pain reported in 90% of patients, and in 83% of CPB cases.
- Mean pre-CPB pain was 6.3 ± 3.0 points, mean post-CPB pain score was 0.9 ± 2.2 points, with **$p<0.001$.**
- Pre-CPB post-prandial nausea prevalence was 37.9%, while post-CPB post-prandial nausea was 11.6%, with a **$p<0.001$.**
- Pre-CPB post-prandial vomiting prevalence was 15.5%, decreasing to 4.9% after CPB, with **$p=0.019$**.
- 82% of patients with normal anatomy reported pain relief, while 88% of patients with MALS anatomy reported pain relief, with a **$p = 0.745$.**
- Pain score of group that eventually elected to have surgery had a post-CPB pain score of 0.4 ± 1.3, while those who did not eventually elect to have surgery had a post-CPB pain score of 1.3 ± 2.6, with **$p=0.043$.**
- Pain score change showed no significant difference based on which quadrants achieved contrast distribution.

Results

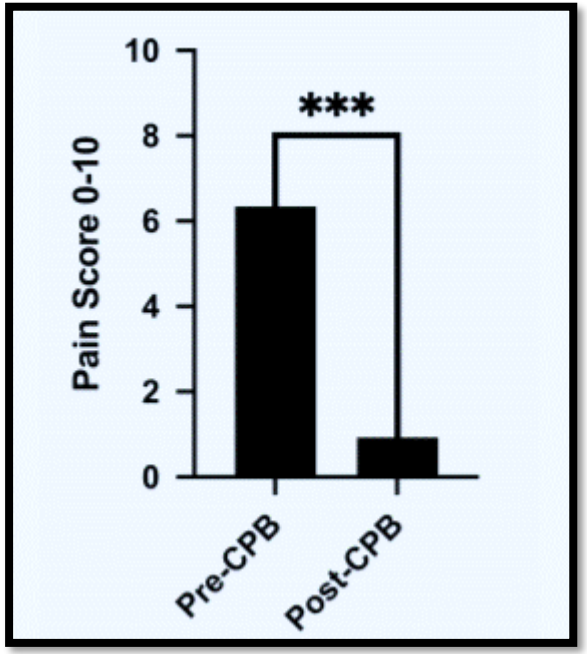

Figure 3. Mean pre-CPB pain was 6.3 ± 3.0 points, mean post-CPB pain score was 0.9 ± 2.2 points, with **p<0.001.**

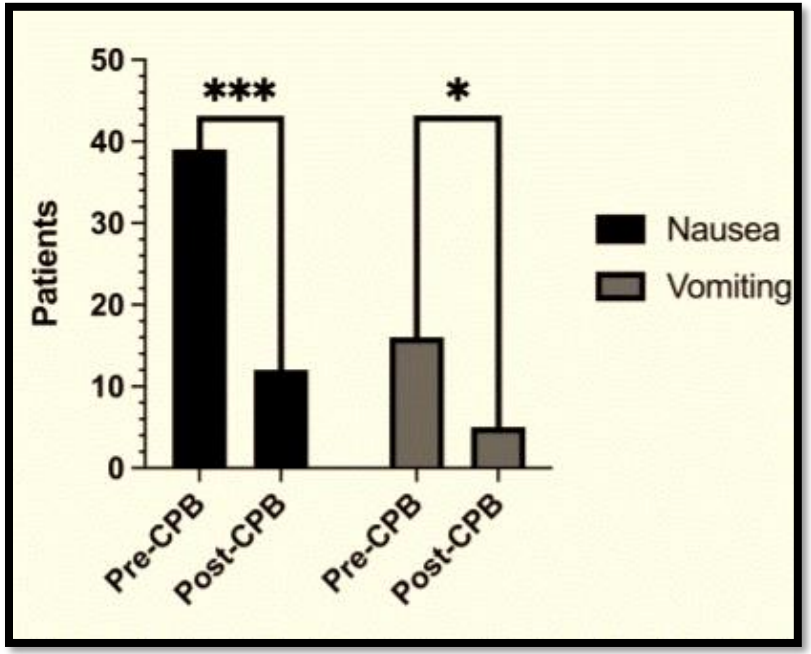

Figure 4. Pre-CPB post-prandial nausea prevalence was 37.9%, while post-CPB post-prandial nausea was 11.6%, with a **p<0.001.** Pre-CPB post-prandial vomiting prevalence was 15.5%, decreasing to 4.9% after CPB, with **p=0.019**

Results

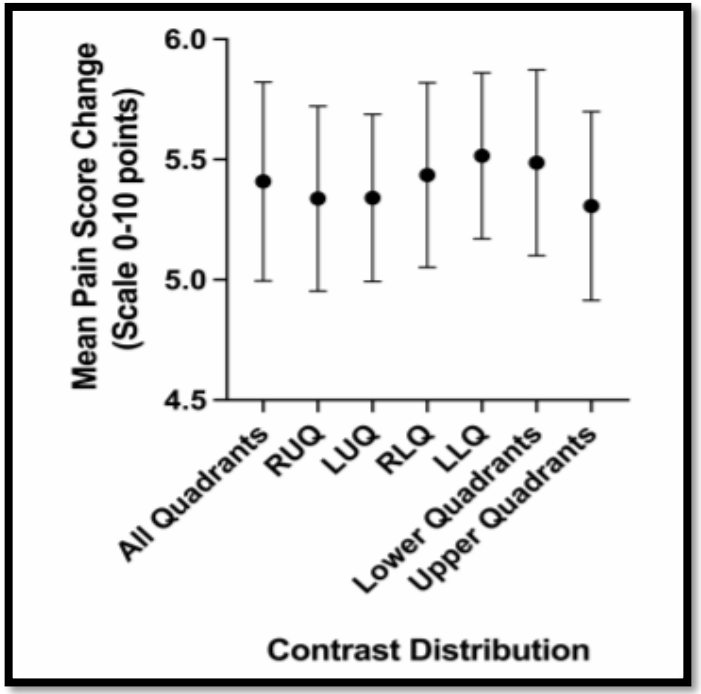

Figure 5: Pain score change showed no significant difference based on which quadrants achieved contrast distribution

Discussion

- No significant difference in response to CPB in patients with MALS anatomy vs. those with normal vascular anatomy. This suggests primary etiology of MALS is neurogenic.
- Dispersal pattern of anesthetic did not have a significant effect on how effective the CPB was.
- A link between Ehler's Danlos and POTS was noted in the study, should be further investigated.
- Results indicate presence of celiac stenosis does not correlate with post-prandial symptoms
- Results also indicate absence of stenosis/celiac displacement does not exclude patient from being diagnosed with MALS.

But wait . . . (Limitations)

- Retrospective Cohort study, no placebo, only 96 patients.
- Given self-reporting, there is room for confirmation bias, as well as recall bias depending on when pain score was taken exactly.
- Mean age was 27 ± 16 years, with minimum age being 18, indicating right/positive skew (curve shifted to left). Makes this less generalizable given median age of MALS diagnosis is between 40-60 yo.
- Confounding bias:
  - Anesthesia/sedation – not likely
  - Difference in anesthetic composition, with first 55% getting w/o dexamethasone – unlikely, but no comparison provided.
  - Previous history of gastroparesis noted in table – possible, but low probability given only 10% of patients
  - Only 84% of patients imaged via CT prior to CPB – possible especially if clinical diagnosis did not include Duplex US.
  - Only 11% of patients had inspiratory/expiratory CTA study pre-CPB.

Things that may help improve quality of study

- Quantify decrease in pain (i.e. how much of a drop is it, normal pain scale is usually a decrease in 3 points).
- Did not measure relative risk
- Clarify how patients were diagnosed with MALS

Module Outline

I. Case

II. Background

III. Article Overview

IV. <u>Clinical Questions</u>

V. <u>Key Points</u>

Clinical questions- What does this mean for future practice given what we know?

- Can we use CPB as the gold standard for diagnosing MALS in a compatible clinical scenario?
  - While the evidence certainly does point towards it being an effective indicator, there need to be further studies comparing results to a placebo.
- Should we continue to utilize Duplex US and CTA for diagnosing celiac stenosis/other anatomical variants if there is no correlation to benefit in treatment?

Key points

I. MALS is a syndrome of post-prandial pain associated with compression of the celiac plexus.

II. The absence of celiac stenosis on CT or US does not exclude the diagnosis of MALS.

III. The use of CT-guided CPB may become the new gold standard for diagnosing MALS with further studies such as RCT's.

IV. Patients who had a greater change in pain scores were more likely to eventually choose surgery.

References

1. Barbon, D. A., Hsu, R., Noga, J., Lazzara, B., Miller, T., & Stainken, B. F. (2021). Response To Celiac Plexus Block Confirms Neurogenic Etiology of Median Arcuate Ligament Syndrome. *Journal of Vascular and Interventional Radiology*.
2. Weber, J. M., Boules, M., Fong, K., Abraham, B., Bena, J., El-Hayek, K., ... & Park, W. M. (2016). Median arcuate ligament syndrome is not a vascular disease. *Annals of Vascular Surgery*, *30*, 22-27.
3. Lainez, R. A., & Richardson, W. S. (2013). Median arcuate ligament syndrome: a case report. *Ochsner Journal*, *13*(4), 561-564.
4. Tembey, R. A., Bajaj, A. S., Wagle, P. K., & Ansari, A. S. (2015). Real-time ultrasound: Key factor in identifying celiac artery compression syndrome. *The Indian journal of radiology & imaging*, *25*(2), 202.
5. Scovell, et. al. “Celiac Artery Compressio Syndrome”. *UpToDate*. 2021.