RADY 401 Case Presentation:
Spontaneous Perinephric Hematoma

Megan Gurjar, MS4
8/17/20

UNC SCHOOL OF MEDICINE
Radiology

History of Present Illness

- 49 yo F presented 2 mo ago to OSH with L-sided flank pain, found to have 11cm L-sided renal hematoma on CT A/P; followed by local urologist outpatient
- Presented to UNC from OSH due to worsening flank pain, decreased appetite, 40lb weight loss, subjective low-grade fevers

Past Medical History

- T2DM, HTN, recurrent UTI, atrophic right renal unit, and right duplex collecting system s/p open ureteroureterostomy (1984)

Vitals

HR 103 | BP 136/79 | Temp 36.9 °C | SpO2 97%

Pertinent Physical Exam

Cardiac: Mild tachycardia.

Abdomen: Soft, nontender, nondistended.

GU: Left CVA tenderness.

Pertinent Labs

WBC 11.7

H&H 9.9/31.4

Cr 0.66

Imaging Workup During Hospital Course

1. CT A/P with and without contrast (at OSH)
2. CT angiogram - abdomen
3. MRI abdomen
4. MAG-3 Lasix renal scan

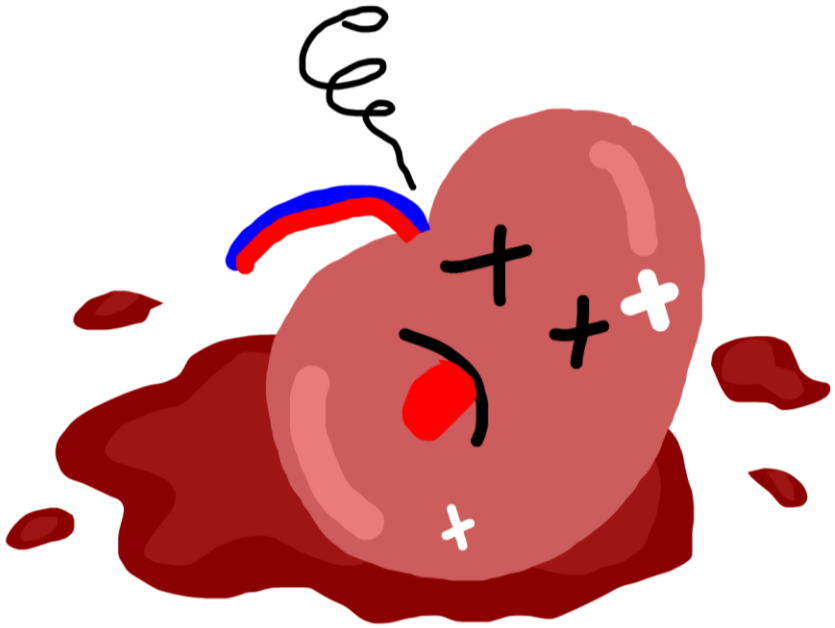

Initial CT A/P

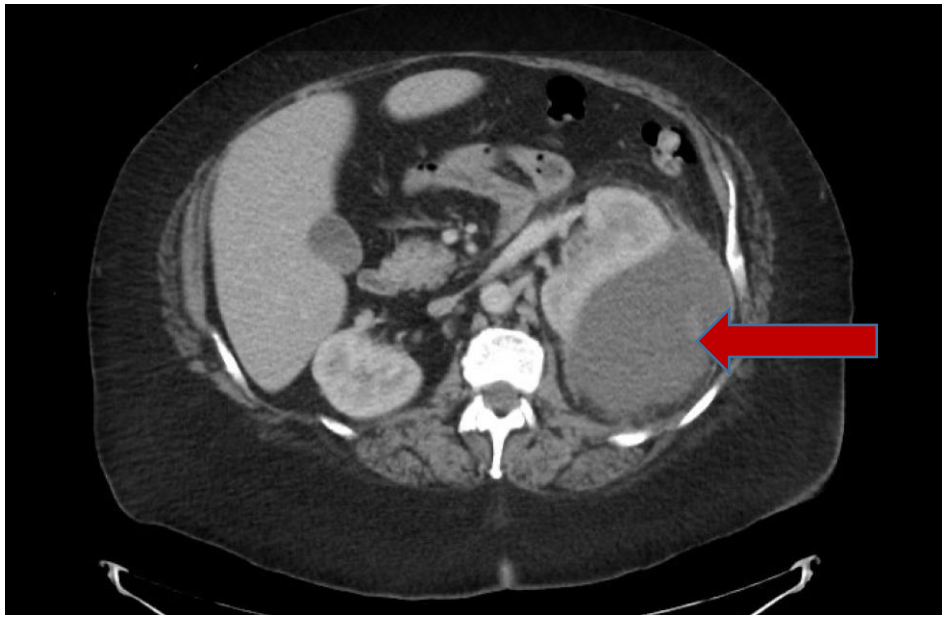

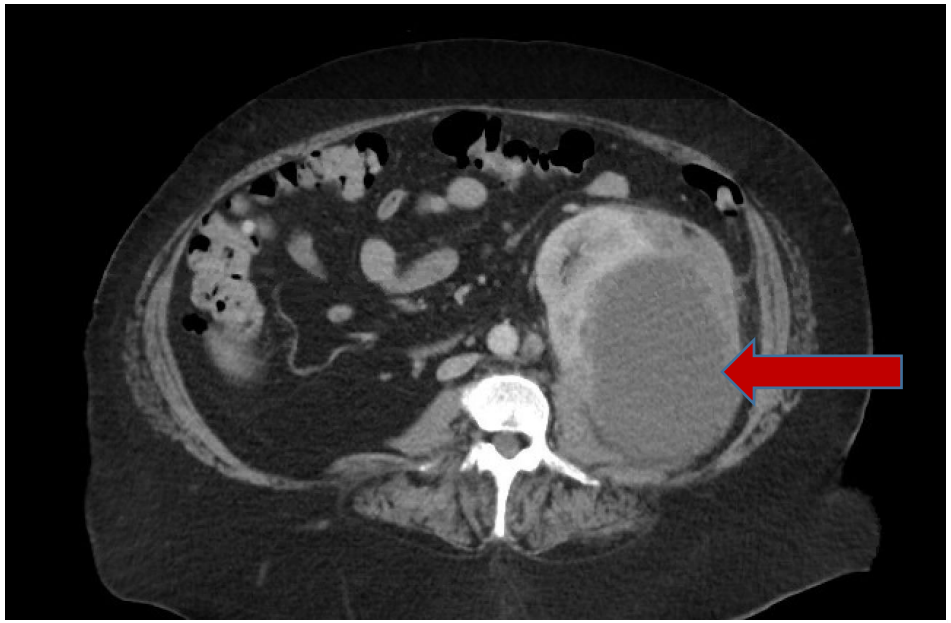

- Left perinephric hematoma 15.3cm of unknown etiology

CTA Abdomen – 2 days later

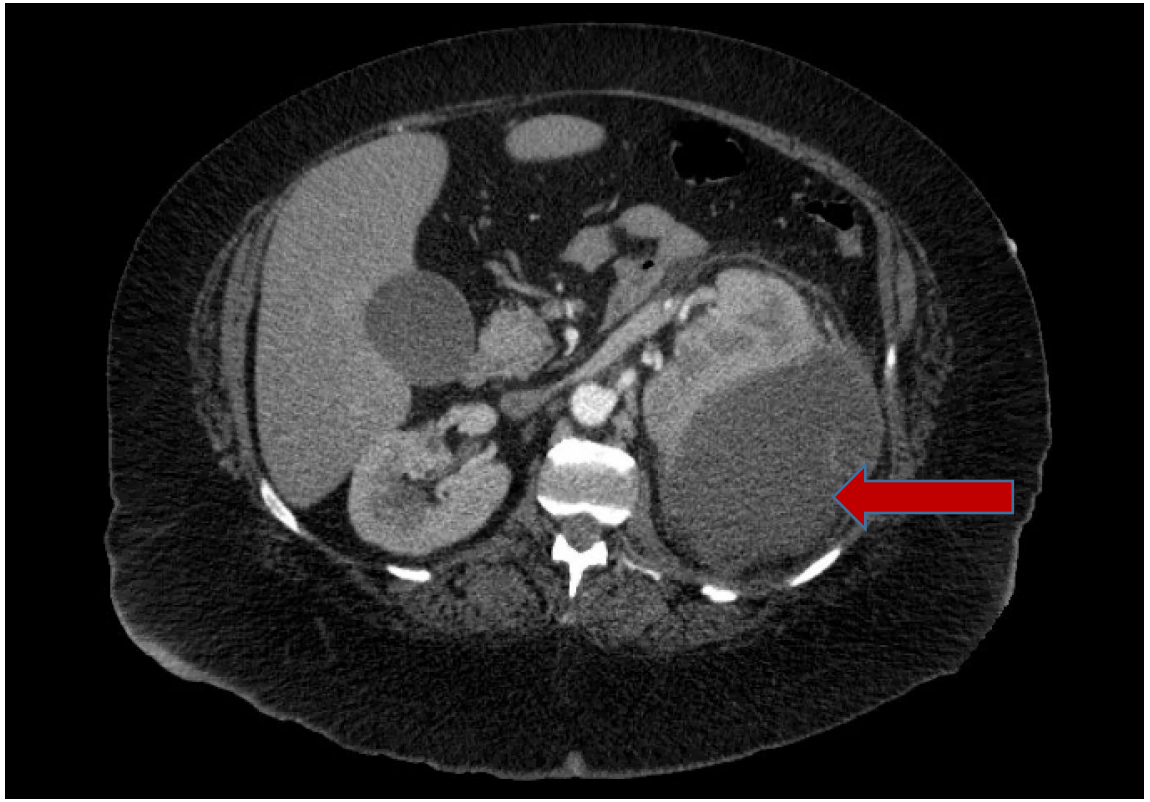

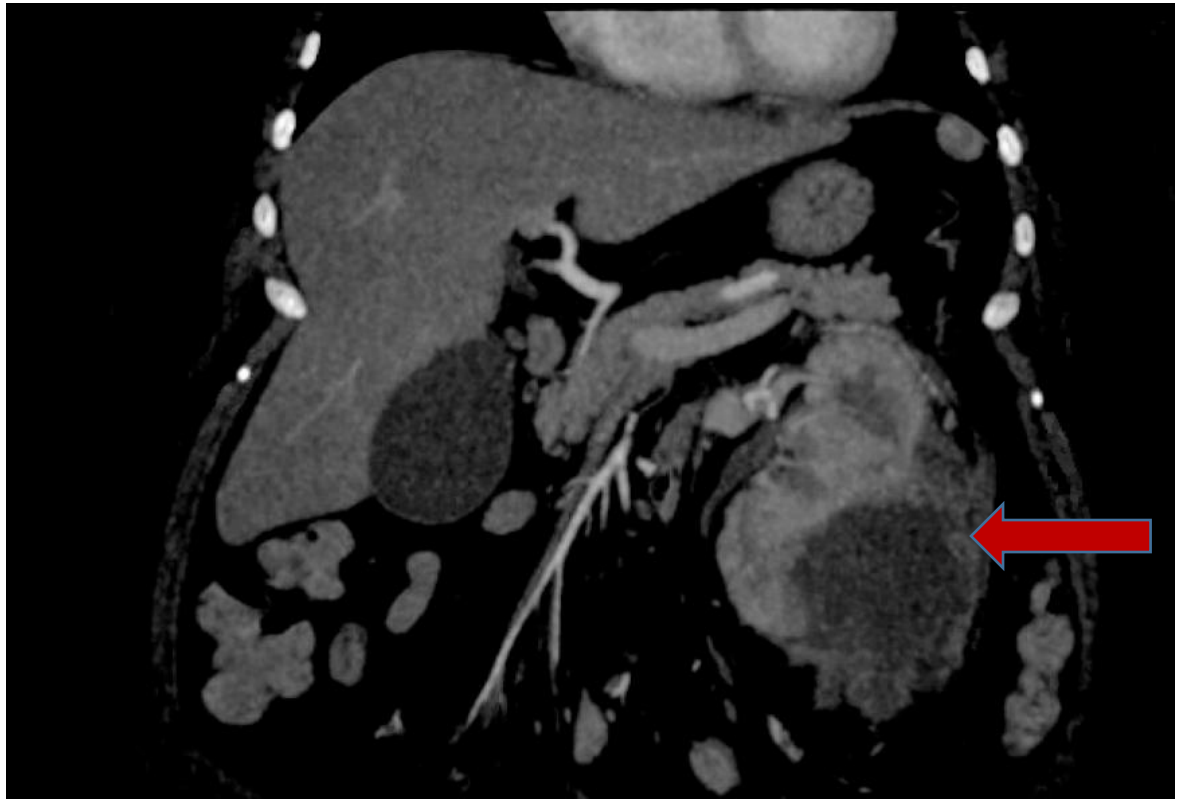

- Interval enlargement of fluid collection to 15.7cm
- No foci of active extravasation

MRI Abdomen

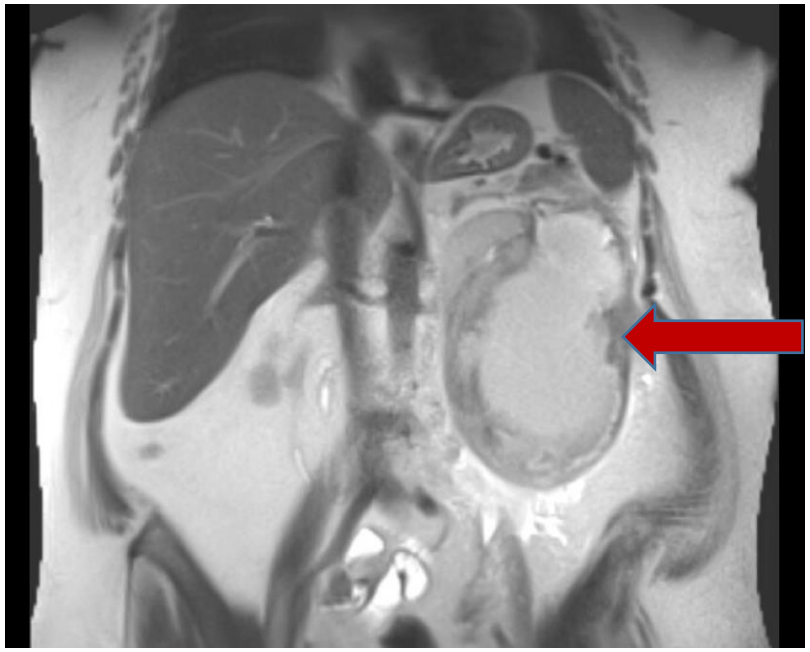

- Following CT findings, IR consulted for evaluation and drainage; requested MRI for further characterization
- T1 hypointense, T2 hyperintense heterogeneous mass with enhancing internal septations
- Concern for possible cystic malignancy; features less typical of subcapsular/perinephric hematoma

Lasix Renal Scan

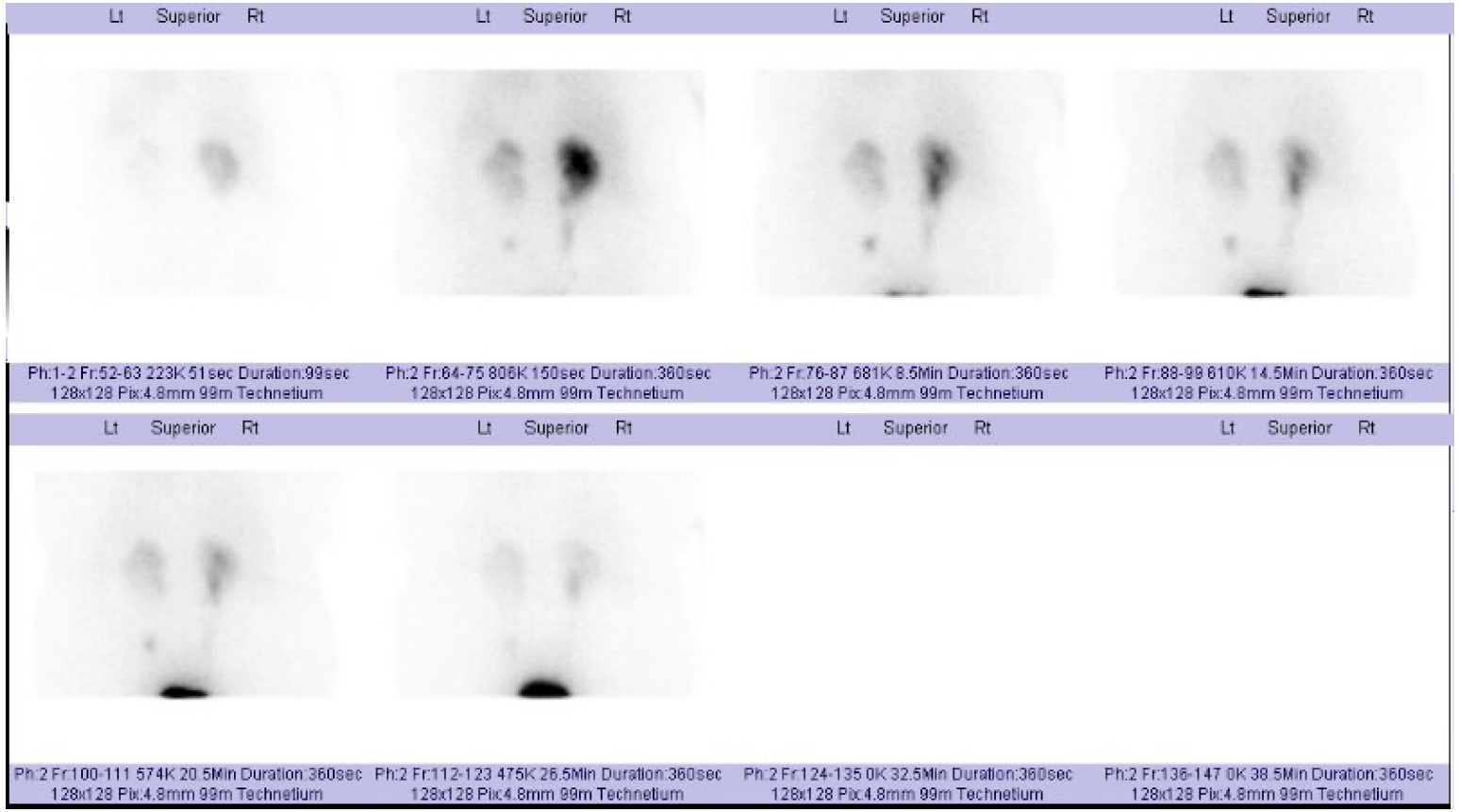

- Reason for exam: history of atrophic R renal unit and consideration surgical intervention for L kidney
- Split function
  - 77.3% R kidney
  - 22.7% L kidney

Patient Outcome

- IR completed bx and aspiration → specimen did not survive processing, but fluid grew Klebsiella
- Given pain, weight loss, and uneven split function, decision made to undergo radical nephrectomy instead of conservative measures or washout
- Intraop, mass was consistent with perinephric abscess confirmed by U/S, needle aspiration, and Gram stain → abscess unroofed and JP drain placed
  - Surgical pathology negative for malignancy
- Postop course uncomplicated
  - Pain controlled, diet advanced, intraop culture consistent with preop culture (discharged on abx x10d), discharged with JP drain and 1 week follow-up

Spontaneous Renal Hemorrhage (Wunderlich Syndrome)

- Rare condition (~552 known published cases from 1933 to 2016)[1]
- Classically presents as Lenk's triad: 1) acute onset flank pain, 2) palpable abdominal mass, 3) hypovolemic shock
- Many cases in the literature report non-specific symptoms
  - Nausea, vomiting, headache, fever, weight loss, anemia and macroscopic hematuria
- <u>Etiologies</u>: renal neoplasm, vascular, infection, other[1,2]

Preferred Imaging of Renal Hematoma

- **Ultrasound** found to have 56% sensitivity for identifying spontaneous hemorrhage compared to **CT** with 100% sensitivity[2]
  - Etiology correctly identified with sensitivity and specificity of 11% and 33% for ultrasound and 57% and 82% for CT, respectively
- **CT angiography** recommended if initial CT scan fails to reveal the underlying cause, especially given likelihood of vascular etiology[3]
- **MRI** may have advantage over CT for diagnosing small tumors[4]

Classic CT Findings of Perinephric Hematoma

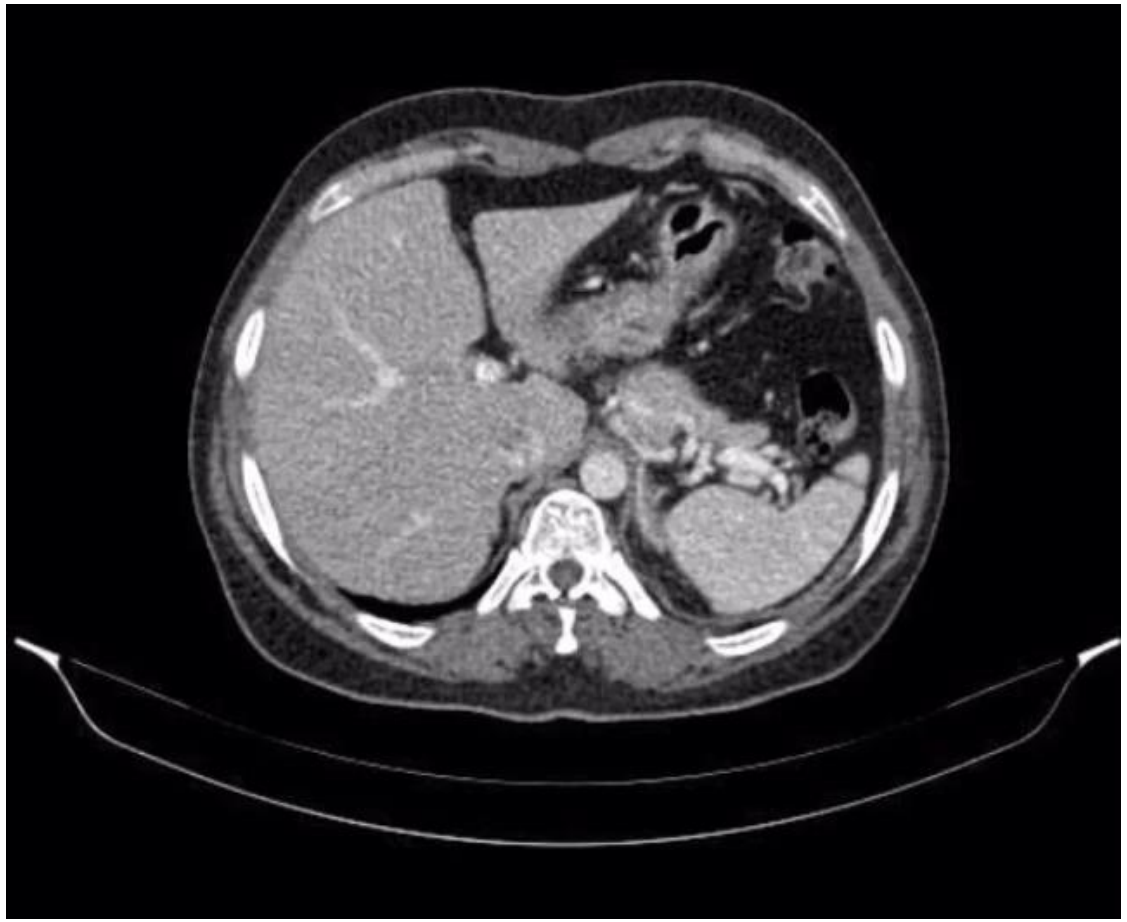

Video scan clip case courtesy of Dr Mohammad Taghi Niknejad, Radiopaedia.org, rID: 20509

https://radiopaedia.org/cases/renal-haematoma-in-a-patient-with-angiomyolipoma-wunderlich-syndrome?lang=us

Imaging Costs & Relevant Radiation Concerns

1. CT A/P with and without contrast at OSH
   - $3208 at UNC[5]
   - ~20 mSv (7 years of background radiation)[6]
2. CT angiogram abdomen
   - $3,322 at UNC[5]
   - ~10 mSv (3 years of background radiation)[6]
3. MRI abdomen
   - $3,520 at UNC[5]
4. MAG-3 Lasix renal scan
   - $2,984 at UNC[5]

Management of Perinephric Hematoma

Top 3 Take Home Points

- CT is the most appropriate imaging tool for identifying spontaneous renal hemorrhage and associated etiology.
- Interventional radiology's expertise is highly valued in management of patients with suspected renal bleeds.
- Imaging may not give the whole story.

Photo by Megan Gurjar

References

1. Ahn T, Roberts MJ, Navaratnam A, Chung E, Wood S. Changing etiology and management patterns for spontaneous renal hemorrhage: a systematic review of contemporary series. International Urology and Nephrology. 2017 Nov 1;49(11):1897-905.
2. Zhang JQ, Fielding JR, Zou KH. Etiology of spontaneous perirenal hemorrhage: a meta-analysis. *J Urol*. 2002;167(4):1593-1596.
3. Brkovic D, Moehring K, Doersam J, et al. Aetiology, diagnosis and management of spontaneous perirenal haematomas. *Eur Urol*. 1996;29(3):302-307.
4. Kendall AR, Senay BA, Coll ME. Spontaneous subcapsular renal hematoma: diagnosis and management. *J Urol*. 1988;139(2):246-250.
5. UNC Chargemaster. https://www.unchealthcare.org/about-us/billing-and-financial-assistance/chargemaster/
6. American College of Radiology. Radiation Dose to Adults From Common Imaging Examinations.
7. Baishya RK, Dhawan DR, Sabnis RB, Desai MR. Spontaneous subcapsular renal hematoma: a case report and review of literature. Urology annals. 2011 Jan;3(1):44.