RADY 403 Case Presentation: Osteomyelitis

Calvin Blocker July 2020

Focused patient history and OSH workup

Patient is a 13 y.o M w/ no significant PMHx history who presents c/o joint pain and fevers x 4 days. Prior to sx onset, he was in his normal state of health w/no recent illness. On day 1 of illness he developed right knee pain and fevers. These sxs persisted as he developed r. hip pain and r. chest pain (knee > chest > hip). Tylenol and Motrin provided minimal effect on fever or pain. His walking was limited by pain and swelling (currently has a limp), located mainly in the superior aspect of the r. joint/distal femur. . The pt was seen at an OSH 1 day prior to admission and was sent home w/o prescriptions. Of note, OSH reports +BCx with gram positive cocci in clusters.

Focused patient history and workup

Pertinent Exam Findings

- VS: T39.5, P120, RR24, BP106/60, Wt 64kg
- General: lying in bed in obvious discomfort; wash cloth on forehead and ice packs on chest
- Lungs: CTAB, w/o wheezes/crackles/rhonchi. Chest TTP on right mainly along the midline
- Skin: no apparent rash; scar developing on left knee; warm and diaphoretic

MSK:

- Left side: normal Right side: knee with swelling, TTP mainly at distal femur/superior joint, and pain with passive flexion beyond 45 degrees; hip with minimal discomfort with active motion even against resistance; no upper extremity findings

Differential Diagnosis

- Osteomyelitis
- Septic arthritis
- Osteosarcoma
- Disseminated gonococcal arthritis
- Septic emboli
- Pleuritis
- Pneumonitis
- Bacteremia

-> What imaging studies should be considered?

American College of Radiology Appropriateness Criteria

Clinical Condition: **Suspected Osteomyelitis, Septic Arthritis, or Soft Tissue Infection (Excluding Spine and Diabetic Foot)**

Variant 1: **Suspected osteomyelitis, septic arthritis, or soft-tissue infection (excluding spine and diabetic foot). First study.**

Radiologic Procedure	Rating	Comments	RRL*
X-ray area of interest	9		Varies
CT area of interest with IV contrast	1		Varies
CT area of interest without IV contrast	1		Varies
CT area of interest without and with IV contrast	1		Varies
MRI area of interest without IV contrast	1		O
MRI area of interest without and with IV contrast	1		O
US area of interest	1		O
Rating Scale: 1,2,3 Usually not appropriate; 4,5,6 May be appropriate; 7,8,9 Usually appropriate			*Relative Radiation Level

American College of Radiology Appropriateness Criteria

For Suspected Osteomyelitis, Septic Arthritis, or Soft Tissue Infection

(Excluding Spine and Diabetic Foot)

Differentiating soft tissue from osseous infection often determines the appropriate clinical therapeutic course.

Radiographs are the recommended initial imaging examination, and although often not diagnostic in acute osteomyelitis, can provide anatomic evaluation and alternative diagnoses influencing subsequent imaging selection and interpretation.

MRI with contrast is the examination of choice for the evaluation of suspected osteomyelitis, and MRI, CT, and ultrasound can all be useful in the diagnosis of soft tissue infection.

CT or a labeled leukocyte scan and sulfur colloid marrow scan combination are alternative options if MRI is contraindicated or extensive artifact from metal is present.

List of imaging studies

Initial studies:

- Supine AP and frog leg film of hip
- AP and lateral film of r. knee

Subsequent studies:

- MRI of r. lower extremity (w/wo contrast)
- Portable CXR
- Chest CT w/ contrast

Imaging Study: AP and lateral view of r. knee

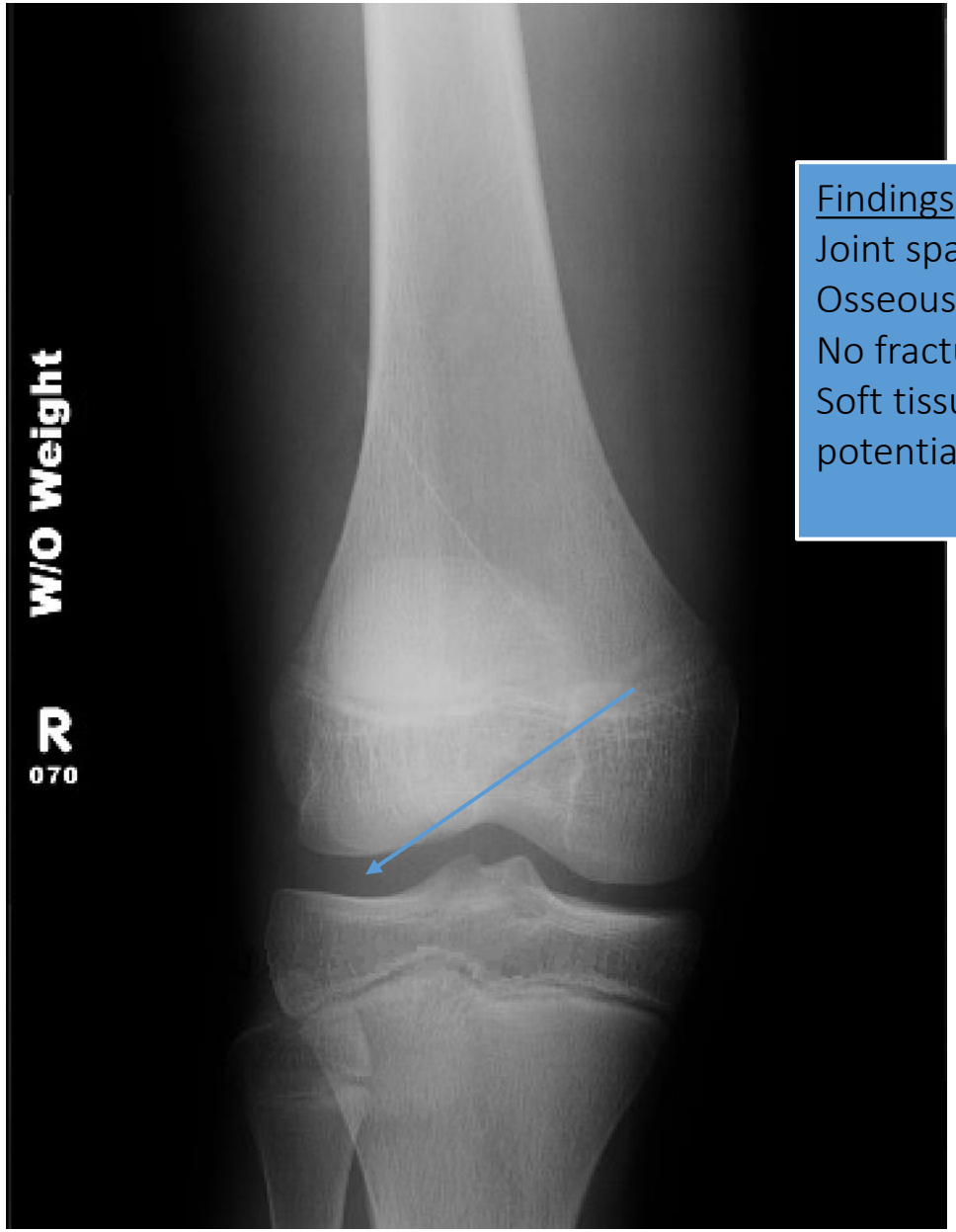

Findings:
Joint spaces preserved.
Osseous density is normal.
No fracture or dislocation.
Soft tissue swelling and potential small joint effusion.

Imaging Study: Supine AP and frog leg view of hips

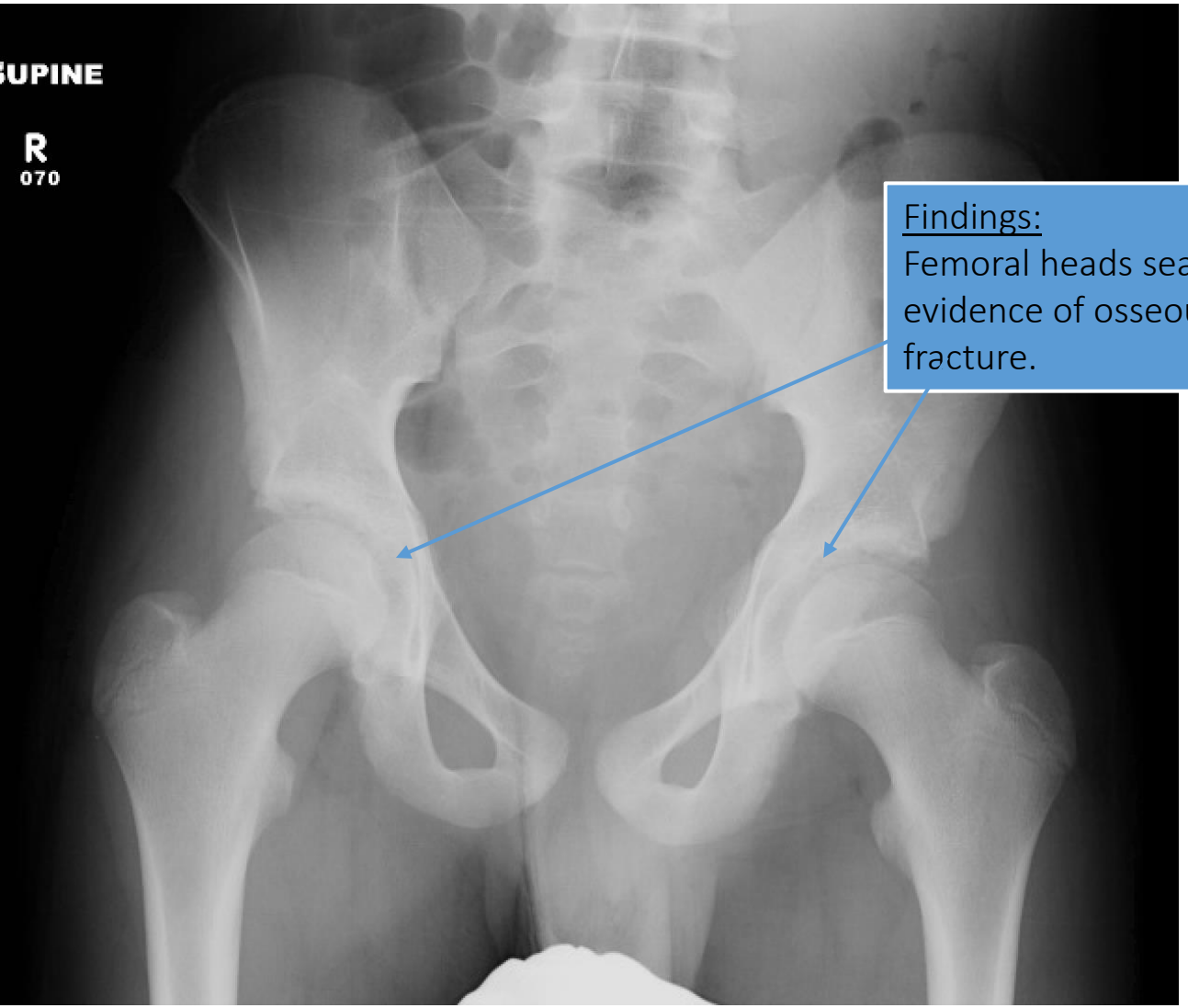

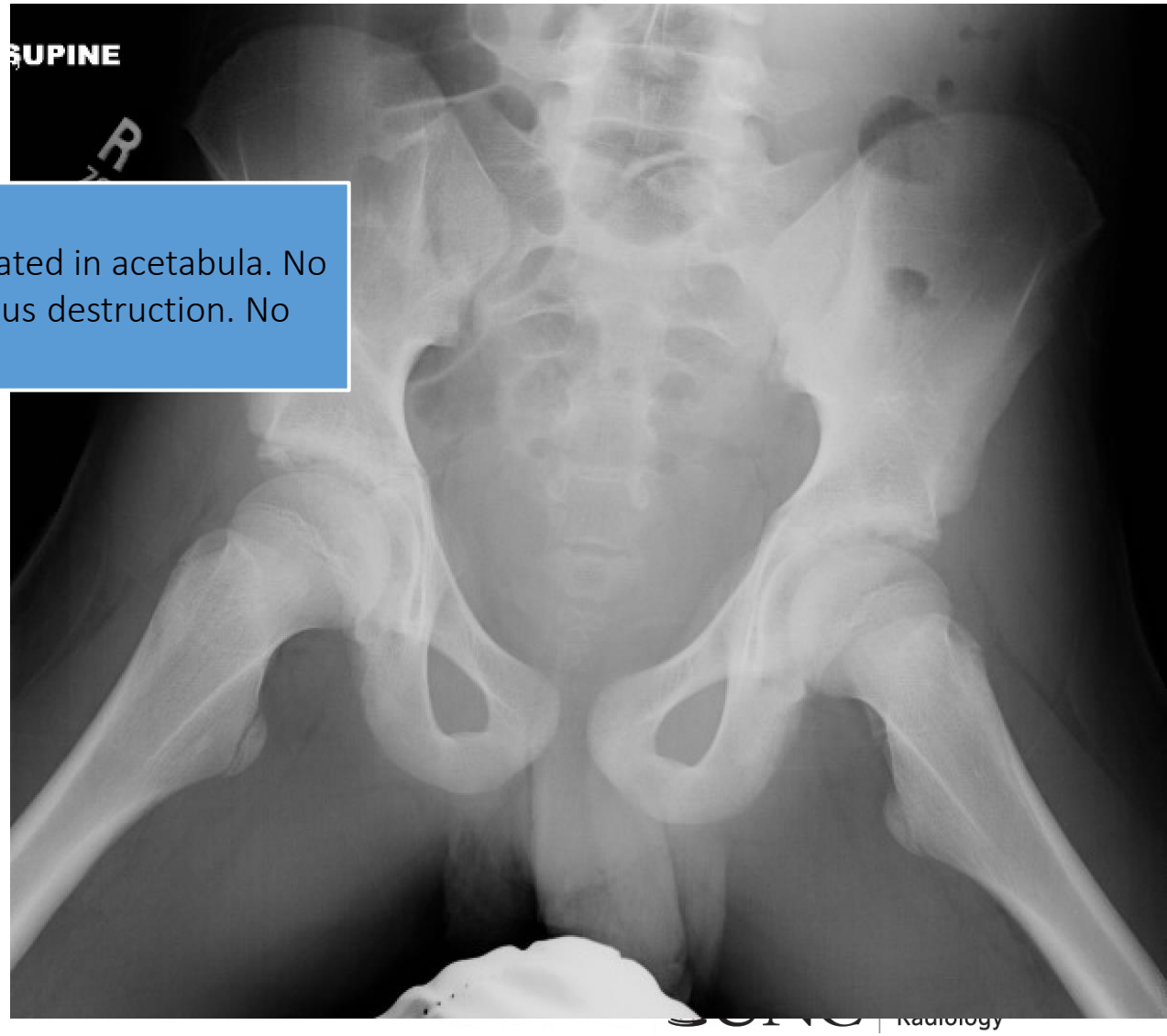

Findings:
Femoral heads seated in acetabula. No evidence of osseous destruction. No fracture.

Imaging Study: MRI of r. lower extremity, sagittal and axial view

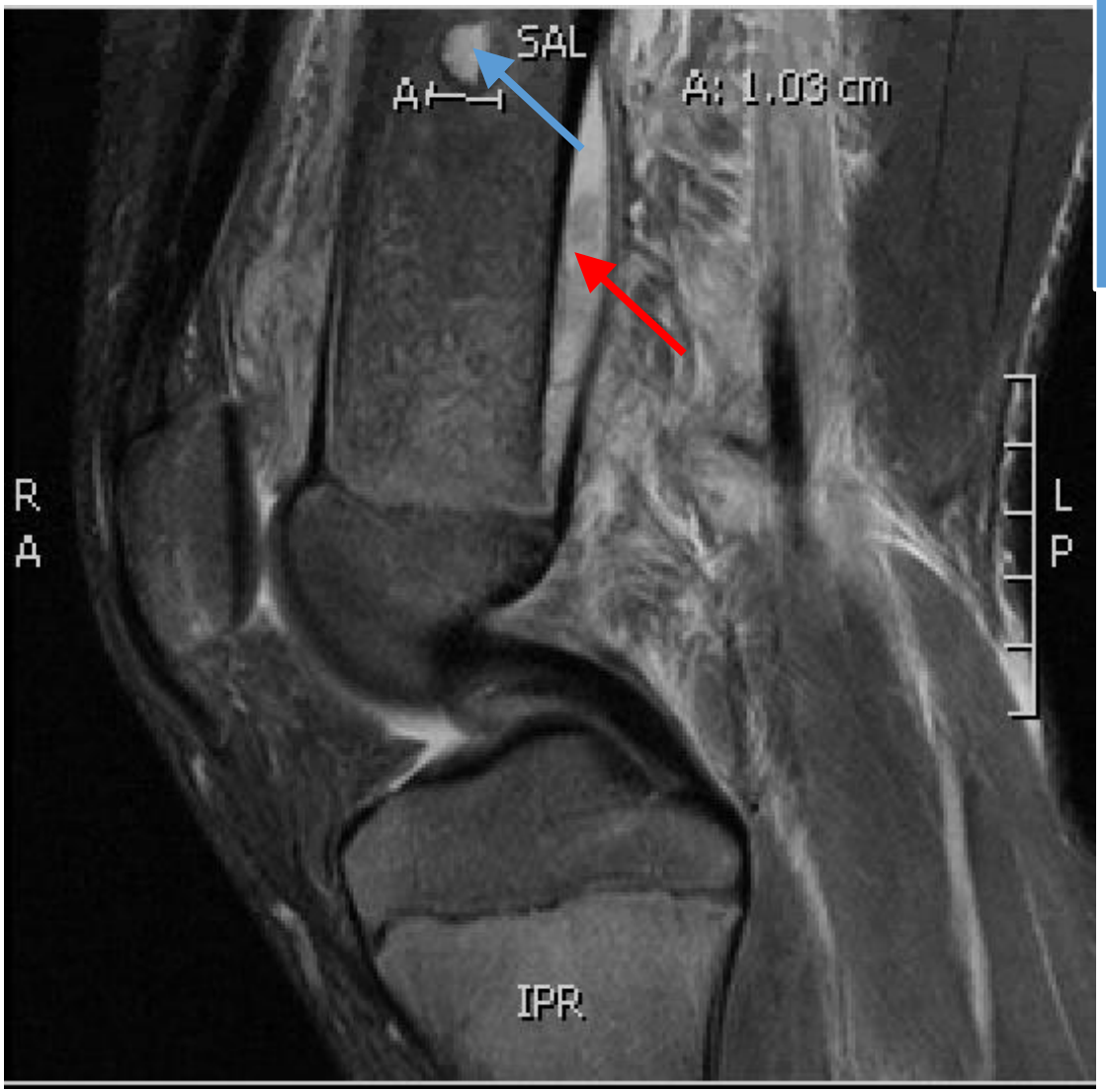

Findings:

Small joint effusion

Complex fluid collection (6 x 1 cm) abuts the posterior, distal periosteum of the femur **"Brodie's abscess"**

Subperiosteal abscess

Diffuse enhancement of the anterior and posterior distal thigh musculature.

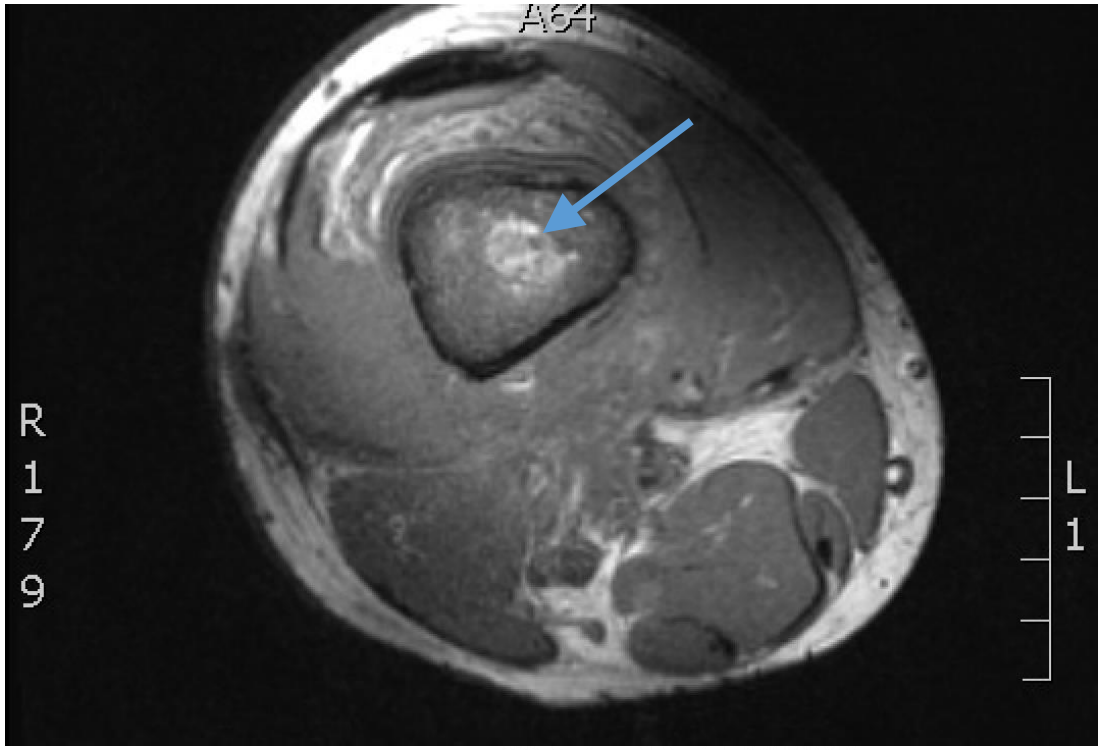

Imaging Study: CXR

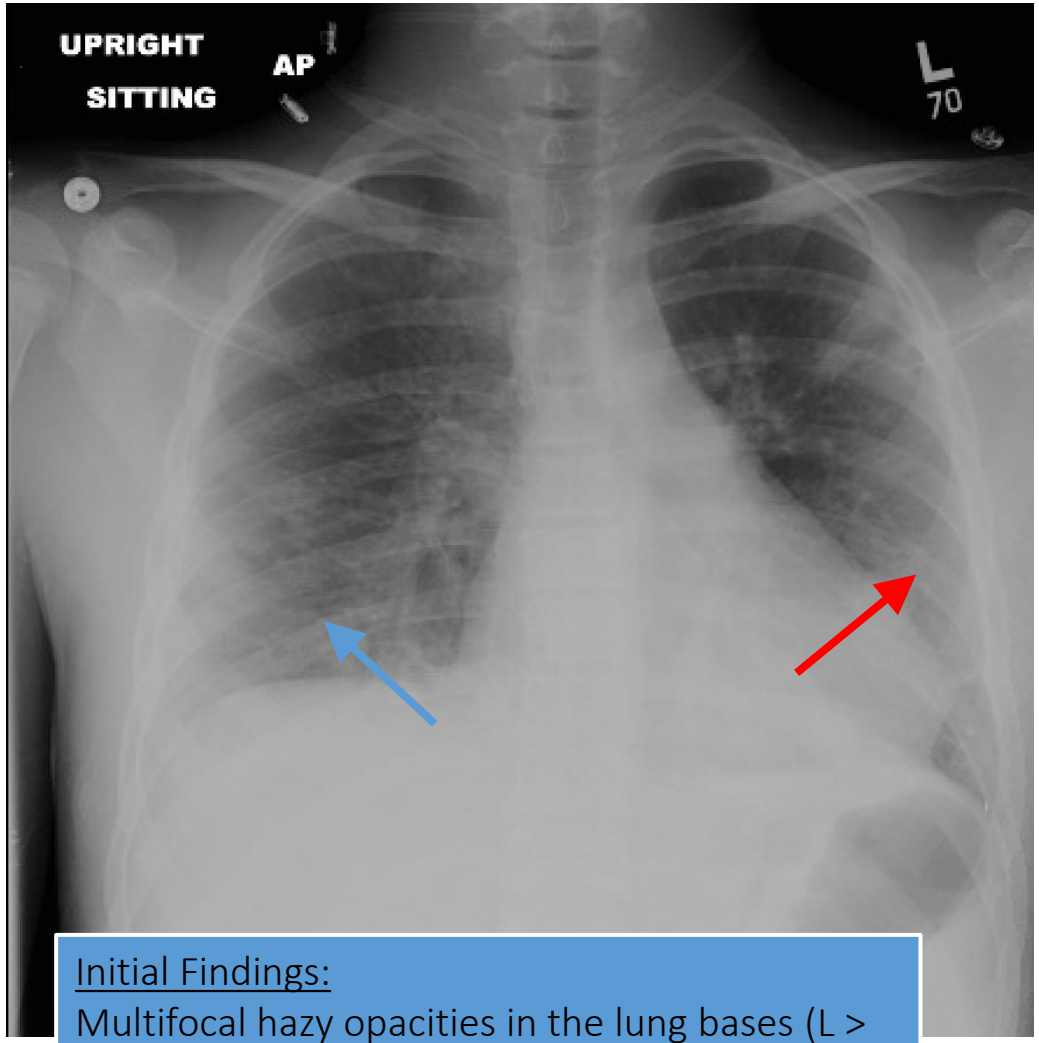

Initial Findings:
Multifocal hazy opacities in the lung bases (L > R). Volume loss in the left lower lobe.
Thickening of the left major fissure.
Concerning for pneumonitis

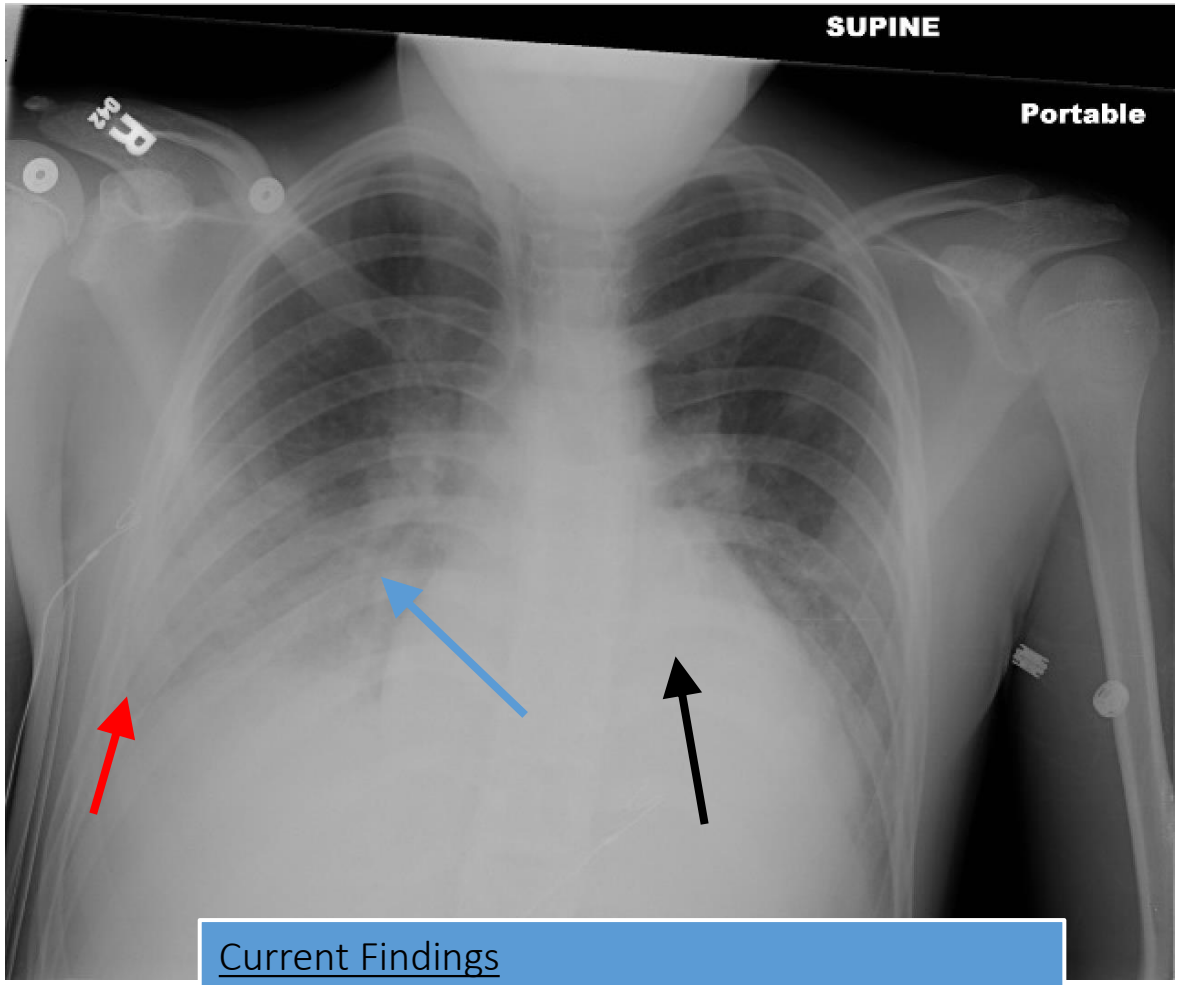

Current Findings
Interval increase in bibasilar alveolar opacities. Heart size is enlarged as before. Small right pleural effusion. Smaller inspiratory lung volumes

Imaging Study: Chest CT w/ contrast

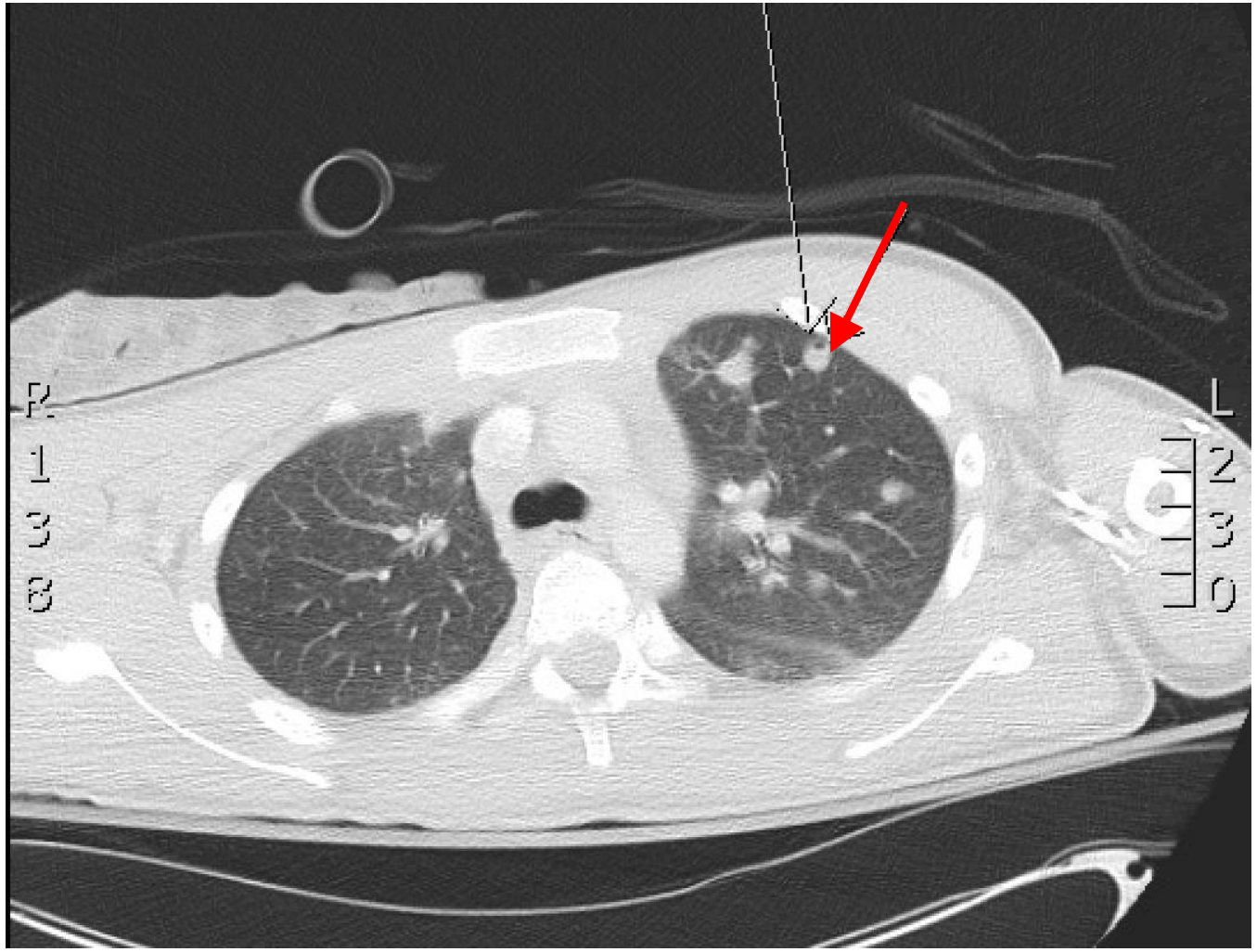

Findings:
Innumerable nodular opacities seen in the lungs bilaterally,
Most nodules are peripherally located
Several of the nodules demonstrate **cavitation** (concerning for septic emboli)

Remainder of CT unremarkable

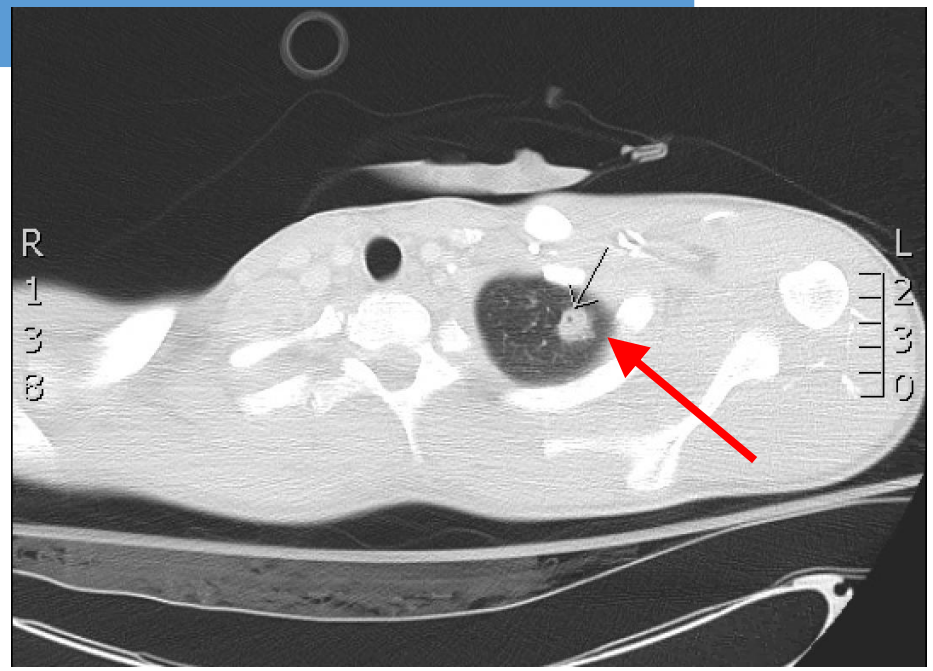

Patient treatment and outcome

- LOS of 9 days (11/10- 11/19). 1 day in the PICU 2/2 to worsening respiratory function.
- Ortho placed a drain (in place for 48 hours) to resolve Brodie abscess.
- ID coverage for Osteomyelitis/bacteremia consisted of Vanc x 9 days, oxacillin x 1 day (11/10), ceftriaxone x 2 days (11/10-11/11), and gent x 2 days.
- A series of blood cultures were collected with the first negative cx on 11/13.
- Patient was discharged on 11/19 on IV clinda x 3 weeks with the goal to switch to oral clinda post-ID f/u. Ortho and ID f/u scheduled for 11/27 11/28 respectively.
- 11/27 Patient continues to have pain. Xrays concerning for progression of osteomyelitis >
- 12/27 READMITTED for series of irrigation and debridement procedures.
- Discharged on 1/4 with 3 weeks of IV Vanc 1600 mg, IV clinda 500 mg, PO rifampin 300 mg for 3 weeks

Discussion: Osteomyelitis

<u>Osteomyelitis</u>: an infection localized to the bone

- It is usually caused by microorganisms (predominantly bacteria) that enter the bone hematogenously.
- Other pathogenic mechanisms include direct inoculation (usually traumatic, but also surgical) or local invasion from a contiguous infection (eg, sinusitis, decubitus ulcers, deep wound infections, periodontal disease).
- Risk factors for non-hematogenous osteomyelitis include open fractures that require surgical reduction, implanted orthopedic hardware (such as pins or screws), and puncture wounds.

<u>Etiology</u>: etiology of acute hematogenous osteomyelitis is not understood completely.

- Bacteremia in childhood occurs frequently, if not daily; thus, the presence of bacteria alone may not explain why infection begins.
- Recent trauma coincidental with a bacteremia has been postulated.
- The presence of an intercurrent illness (ie, chicken pox) or infection may introduce a larger number of organisms or different pathogenic bacteria into the system or alter the immune system, making the host more susceptible.
- The most common pathogen involved is Staphylococcus aureus (although no organism is identified in roughly 50% of pediatric cases)

Discussion: Osteomyelitis

Epidemiology:

- Worldwide incidence ranges between 1/1000 to 1/20,000 population, with 50% of cases occurring in children younger than 5 years of age.

Treatment Paradigm: Patients are typically followed by ID and Ortho

- Abx coverage usually consists of IV Vanc or Clinda empirically. May be pathogen directed once cultures are grown.
- No definitive time-table for IV medications, however patients are typically switched to oral meds once the following criteria are met:
  - Lack of fever for ≥48 hours
  - Decreased pain, erythema, or swelling
  - Normalization of WBC count
  - Consistent decrease in CRP
- Series of blood cultures to determine efficacy of treatment
- I&D of abscess, drain placement, serial debridements are often part of the patient's course in SEVERE cases

Discussion: Brodie Abscess

Brodie Abscess: An intraosseous abscess related to a focus of subacute pyogenic osteomyelitis. It takes on variety of radiographic appearances and can occur at any location and in a patient of any age. It might or might not be expansile, have a sclerotic or nonsclerotic border, or have associated periostitis.

Epidemiology: Typically these present in children with unfused epiphyseal plates, more frequently in boys.

Etiology: S. aureus (most common); cultures often negative

Location: It has a predilection for metaphysis of tubular bones (most commonly tibia) but can also affect carpal and tarsal bones

Discussion: Brodie Abscess

XR: lytic lesion often in an oval configuration that is oriented along the long axis of the bone

- surrounded by a thick dense rim of reactive sclerosis that fades imperceptibly into surrounding bone
- lucent tortuous channel extending toward growth plate prior to physeal closure (pathognomonic)
- periosteal new-bone formation +/- adjacent soft-tissue swelling
- may persist for many months

CT: central intramedullary hypodense cystic lesion with thick rim ossification

- extensive thick well-circumscribed periosteal reaction and bone sclerosis around the lesion could be seen

MRI: The "penumbra sign" on magnetic resonance (MR) imaging is useful for discriminating subacute osteomyelitis from other bone lesions.

- penumbra sign is a rim lining of an abscess cavity with higher signal intensity than that of the main abscess on T1-weighted images
- strong and rapid enhancement after contrast

Differential diagnosis: In some situations consider osteoid osteoma

UNC Top Three

- Osteomyelitis is a very common disorder in the pediatric population with 50% of world-wide cases occurring in pediatric patients.
- Treatment usually consists of IV abx (vanc, ctx, gent) covering localized bone infection and the concomitant bacteremia.
- Patients typically followed by ID and Ortho

References

1.Kaplan SL. Osteomyelitis in children. Infect Dis Clin North Am 2005; 19:787.

2.Syrogiannopoulos GA, Nelson JD. Duration of antimicrobial therapy for acute suppurative osteoarticular infections. Lancet 1988; 1:37.

3.Scott RJ, Christofersen MR, Robertson WW Jr, et al. Acute osteomyelitis in children: a review of 116 cases. J Pediatr Orthop 1990; 10:649.

4.Faust SN, Clark J, Pallett A, Clarke NM. Managing bone and joint infection in children. Arch Dis Child 2012; 97:545.

5.McNeil JC, Forbes AR, Vallejo JG, et al. Role of Operative or Interventional Radiology-Guided Cultures for Osteomyelitis. Pediatrics 2016; 137.

6.Zhorne DJ, Altobelli ME, Cruz AT. Impact of antibiotic pretreatment on bone biopsy yield for children with acute hematogenous osteomyelitis. Hosp Pediatr 2015; 5:337.

7.Le Saux N, Howard A, Barrowman NJ, et al. Shorter courses of parenteral antibiotic therapy do not appear to influence response rates for children with acute hematogenous osteomyelitis: a systematic review. BMC Infect Dis 2002; 2:16.

8.Lazzarini L, Lipsky BA, Mader JT. Antibiotic treatment of osteomyelitis: what have we learned from 30 years of clinical trials? Int J Infect Dis 2005; 9:127.