ORIGINAL ARTICLE

Intensity of pituitary adenoma on T2-weighted magnetic resonance imaging predicts the response to octreotide treatment in newly diagnosed acromegaly

Ansgar Heck*,‡‡, Geir Ringstad†, Stine L. Fougner*,‡,‡‡, Olivera Casar-Borota§,¶,**,‡‡, Terje Nome†, Jon Ramm-Pettersen†† and Jens Bollerslev*,‡‡

*Section of Specialized Endocrinology, Oslo University Hospital, Rikshospitalet, †Department of Radiology, Oslo University Hospital, Rikshospitalet, Oslo, Norway, ‡Department of Medicine, St. Olavs Hospital, Trondheim University Hospital, Trondheim, Norway, §Division of Pathology, Oslo University Hospital, Rikshospitalet, Oslo, Norway, ¶Department of Medical Biosciences, Umeå University, Umeå, **Department of Clinical Pathology and Cytology, Uppsala University Hospital, Uppsala, Sweden, ††Department of Neurosurgery, Oslo University Hospital and ‡‡University of Oslo, Faculty of Medicine, Oslo, Norway

Allie Harbert, MS4

Journal Club 6/16/20

UNC SCHOOL OF MEDICINE Radiology

Learning Objectives

By the end of this journal club, participants will be able to:

1. Know the epidemiology, presentation, and treatment of pituitary adenomas.
2. Understand differences in symptoms and treatment for functional pituitary adenomas.
3. Identify important imaging features of pituitary adenomas and their clinical significance.

Module Outline

I. **Case**

II. Background

III. Article Overview

IV. Clinical Questions

V. Key Points

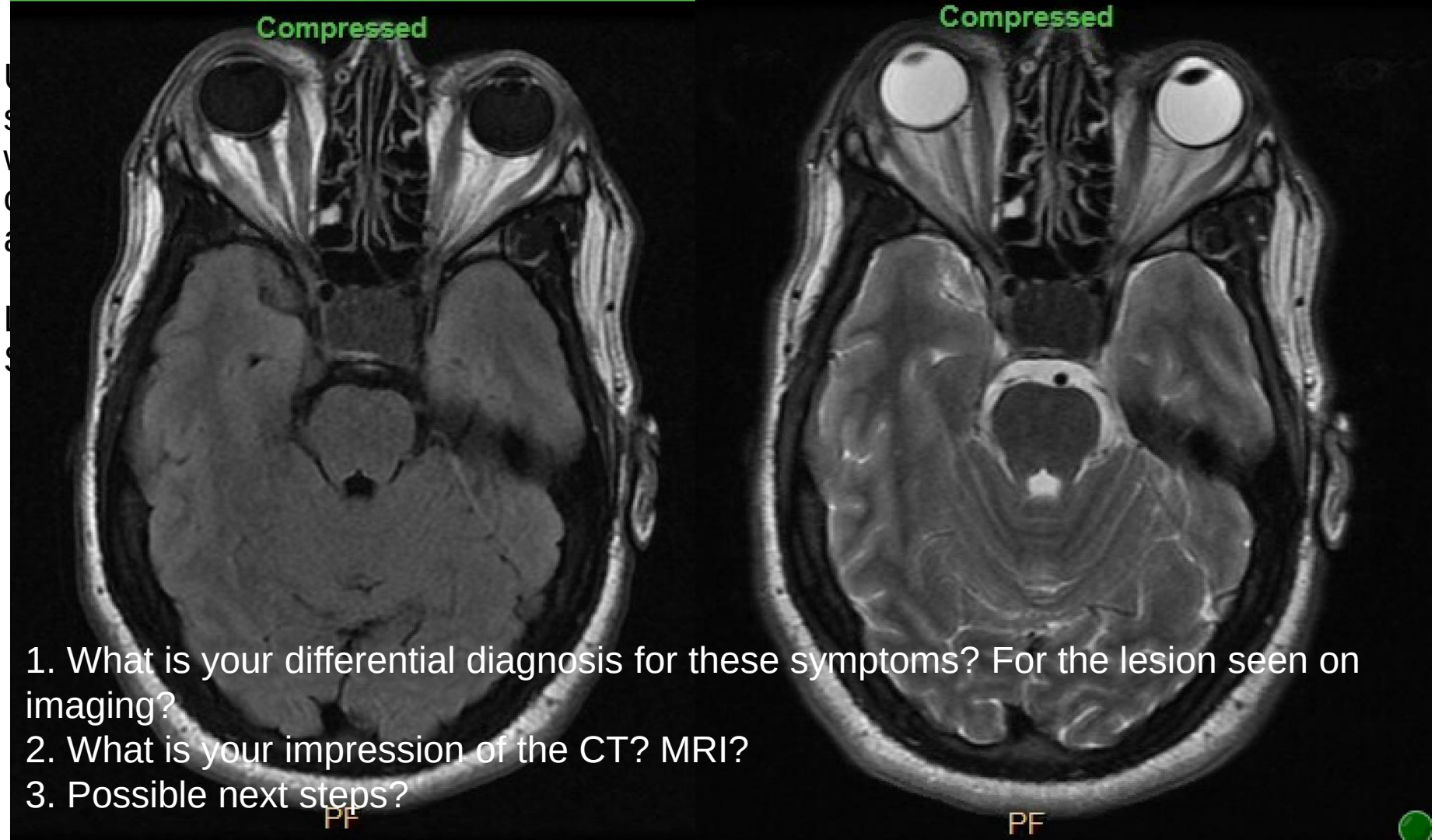

1. What is your differential diagnosis for these symptoms? For the lesion seen on imaging?
2. What is your impression of the CT? MRI?
3. Possible next steps?

Case: Pathology Report

- Underwent endonasal endoscopic transellar resection
- Diagnosis**: Pituitary adenoma**
- Microscopic examination demonstrates a densely granulated hypercellular pituitary neoplasm consisting of deeply eosinophilic tumor cells with nuclei showing mild to moderate nuclear atypia with granular chromatin and frequent prominent nucleoli. Tumor cells are arranged in loose nests and form frequent rosette–-like structures.
- Immunohistochemical stains demonstrate the tumor cells are diffusely positive for CAM 5.2 in a perinuclear pattern, synaptophysin and human growth hormone. The tumor cells are negative for prolactin and ACTH. Overall the findings are consistent with a diagnosis of pituitary adenoma.

Case: Postoperative Considerations

- Evaluate and monitor for adrenal insufficiency, central hypothyroidism, hypogonadotropic hypogonadism
- Repeat GH and IGF-1 3 months post op, repeat imaging
- Further treatment options include repeat surgery and medical management if biochemical control not adequate

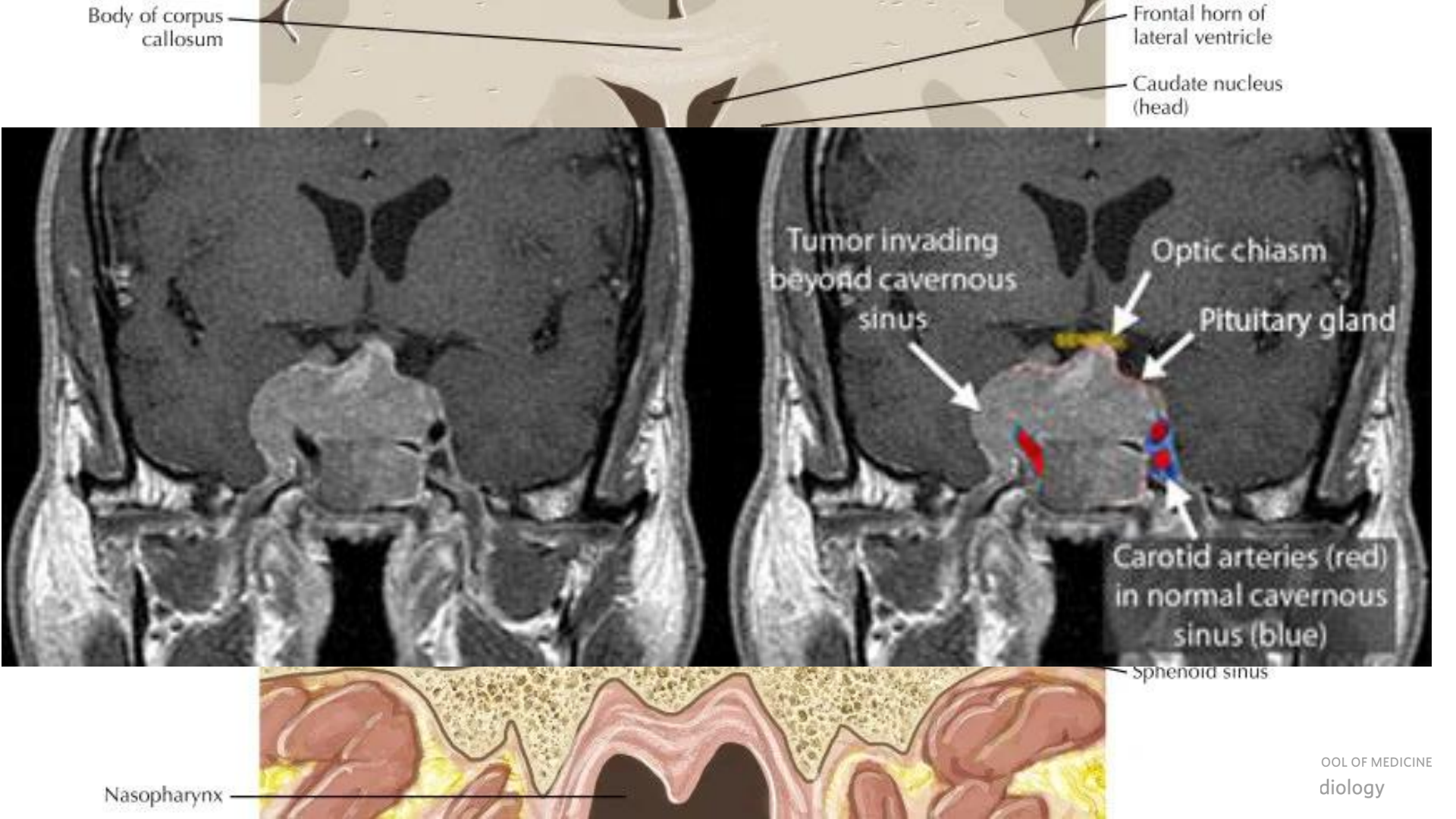

Module Outline

I. Case

II. Background

III. Article Overview

IV. Clinical Questions

V. Key Points

Ba

- Preva
  findir
- Size
  giant
- Path
  - <5
- Symp
  - Hy
  - Bi

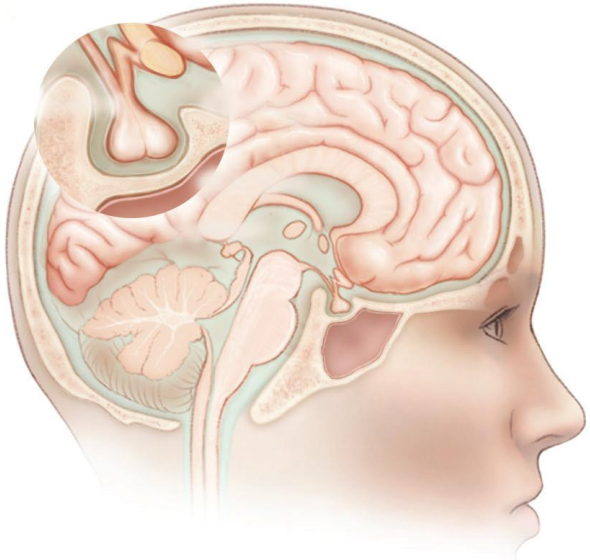

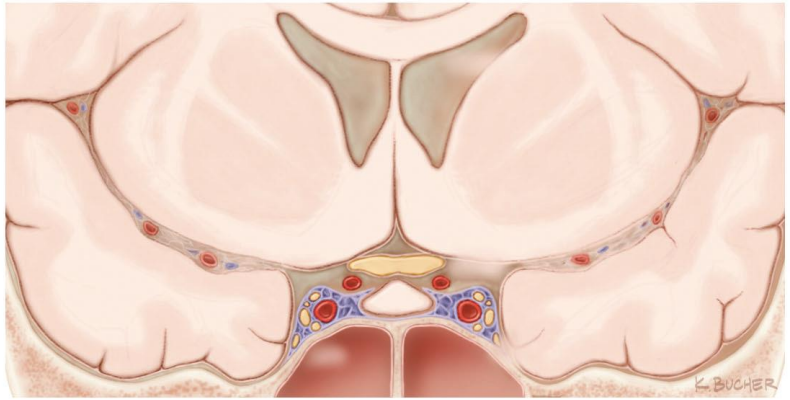

m),

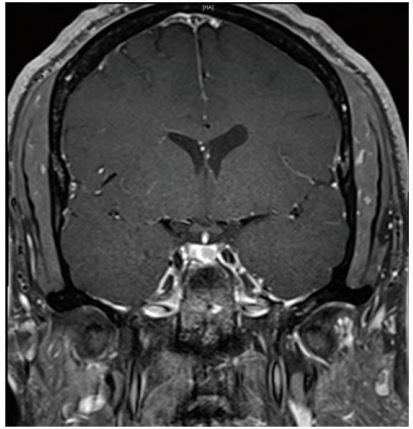

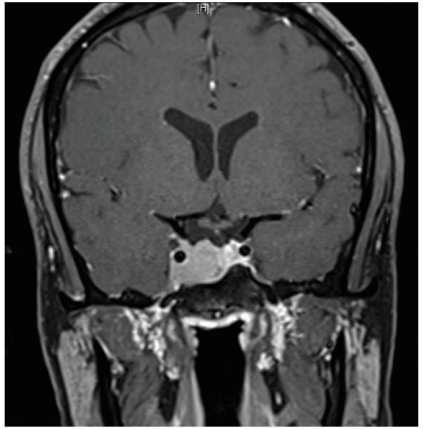

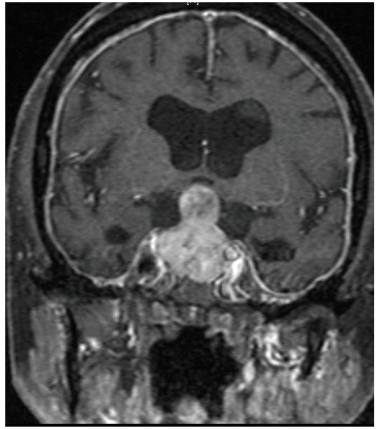

UNC

Types of Pituitary Adenomas

- Growth-hormone secreting tumor (acromegaly)
  - 8-16% pituitary adenomas, causes >95% of acromegaly
  - Presentation: DM, HTN, OSA, arthritis, carpal tunnel syndrome, enlargement of hands and feet, changes in facial features
  - Workup: history, physical, IGF-1 and GH level, MRI
- Prolactinomas
  - 32-66% pituitary adenomas, most common in women age 20-50
  - Presentation: loss of libido, infertility, and osteoporosis in both sexes, oligomenorrhea or amenorrhea and galactorrhea in women and erectile dysfunction in men.
  - Workup: history, physical, MRI, and labs (prolactin level, Cr, thyropropin)

Types of Pituitary Adenomas Cont.

- ACTH-secreting tumor (Cushing's disease)
  - 2-6% of pituitary adenomas, 65-70% of Cushing's disease
  - Presentation: weight gain, redistribution of fat, facial rounding, violaceous skin striae and ecchymoses, DM, HTN, mood disorders, and osteoporosis
  - Workup: late night salivary cortisol, overnight dexamethasone suppression test, ACTH, MRI
- Non-functioning Adenomas
  - 14-54% of pituitary adenomas
  - Presentation: either found incidentally or patient has mass effect symptoms
  - Workup: lab work to evaluate for hormone over secretion or hypopituitarism and visual field testing if near the optic chiasm

Treatment

- Transsphenoidal resection
  - First line treatment other than for prolactinomas (dopamine agonist)
  - Indicated for nonfunctioning adenomas that are symptomatic from size or are growing
  - Recommended for GH-secreting and ACTH-secreting tumors
  - Primary or preoperative medical treatment indicated in certain scenarios for biochemical control

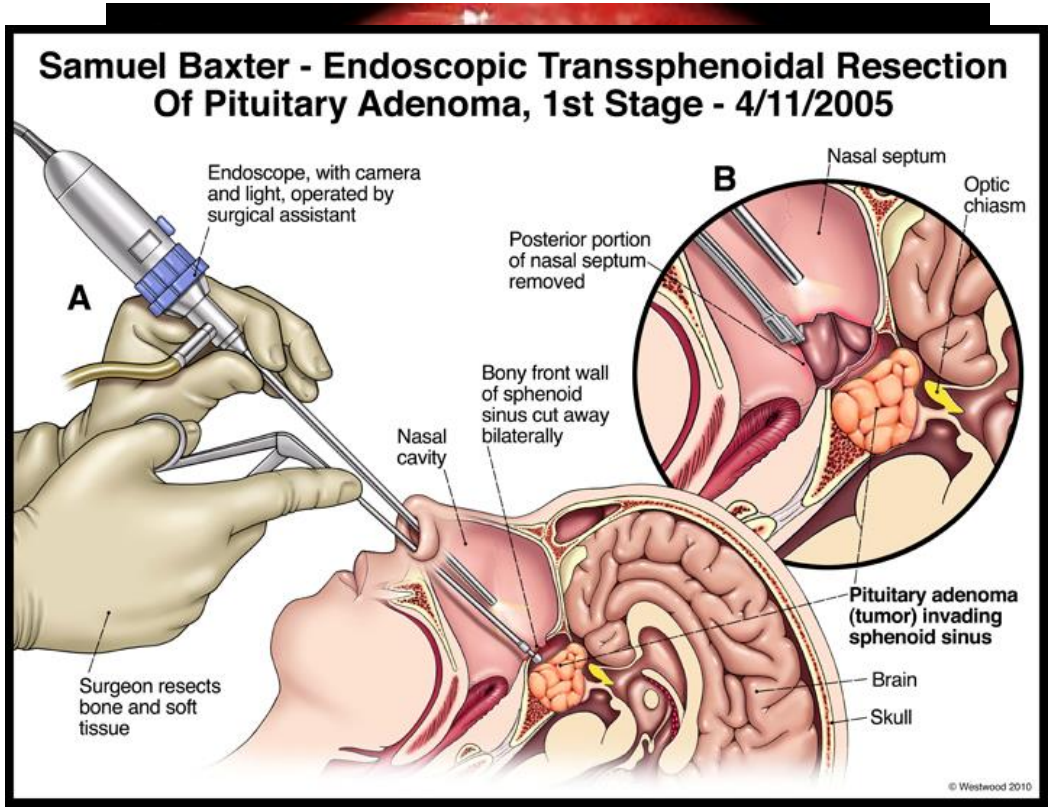

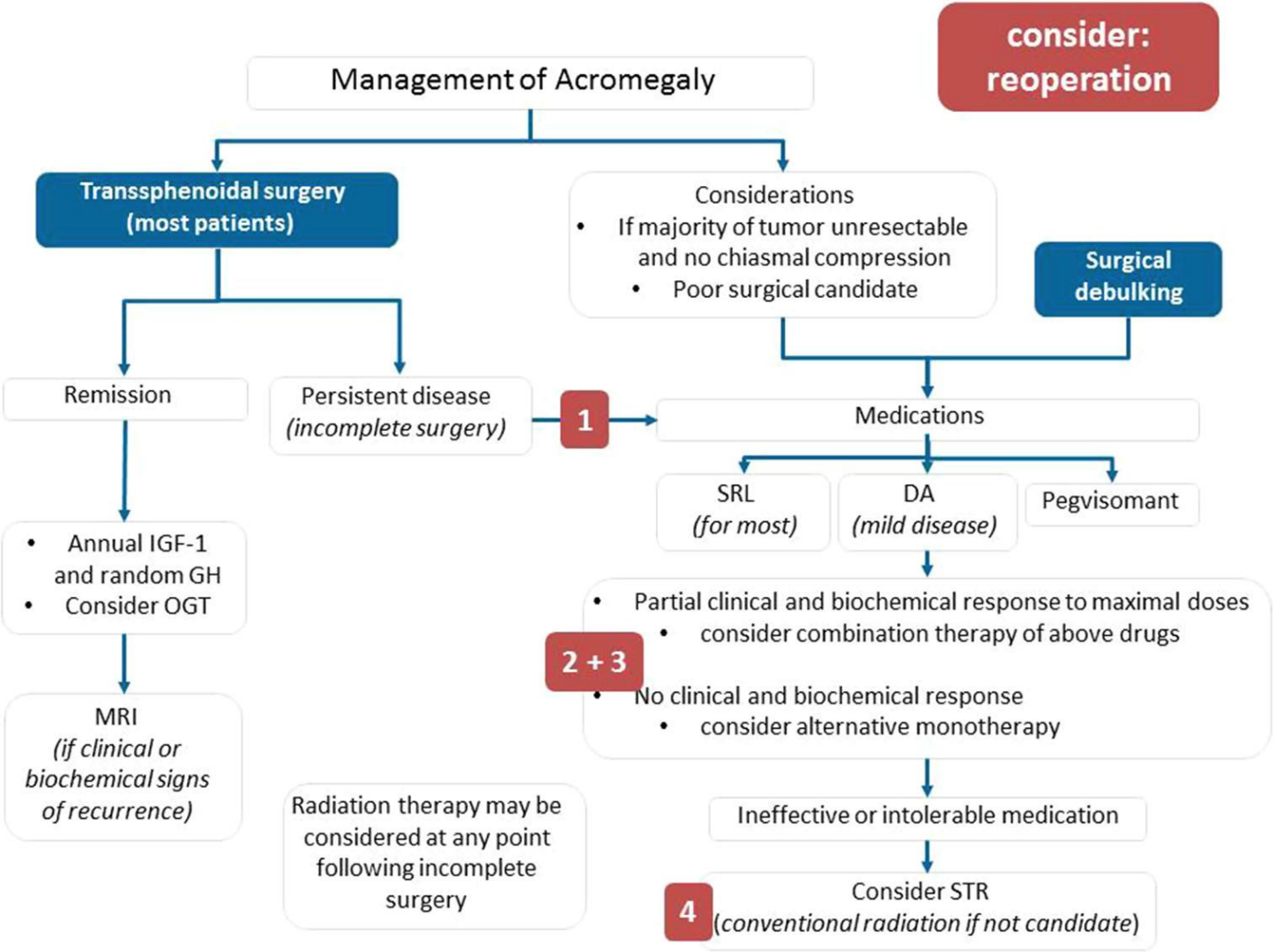
consider: reoperation
Management of Acromegaly
Transsphenoidal surgery (most patients)
Considerations
• If majority of tumor unresectable and no chiasmal compression
• Poor surgical candidate
Surgical debulking
Remission
Persistent disease (incomplete surgery)
1
Medications
SRL (for most)
DA (mild disease)
Pegvisomant
• Annual IGF-1 and random GH
• Consider OGT
• Partial clinical and biochemical response to maximal doses
• consider combination therapy of above drugs
2 + 3
• No clinical and biochemical response
• consider alternative monotherapy
MRI (if clinical or biochemical signs of recurrence)
Radiation therapy may be considered at any point following incomplete surgery
Ineffective or intolerable medication
4
Consider STR (conventional radiation if not candidate)

T1 vs T2 MRI

- T2 reflects the length of time it takes for the MR signal to decay in the transverse plane. A short T2 means that the signal decays rapidly. So substances with short T2's have smaller signals and appear darker than substances with longer T2 values.

In T1 (A) and T2 (B) weighted sagittal MRI of brain, normal pituitary gland is seen.

UNC SCHOOL OF MEDICINE Radiology

Module Outline

I. Case

II. Background

III. Article Overview

IV. Clinical Questions

V. Key Points

Article Nuts and Bolts

Purpose: assess whether T2 signal intensity could determine long-term response to first-line SA treatment and to assess clinical and biochemical baseline characteristics, as well as histological subtype in relation to the MRI

Journal: Clinical Endocrinology. 2012

Study Type: Retrospective observational study of cases at the Oslo Hospital between 2003 – 2010

Number of Cases: 45 patients for analysis of biochemical and clinical baseline variables, 25/45 patients treated with long acting SA, 34/45 cases for immunohistochemical granulation pattern assessment

Data: GH and IGF-1 levels, MRIs reviewed by 2 neuroradiologists, granulation status determined by pathologist

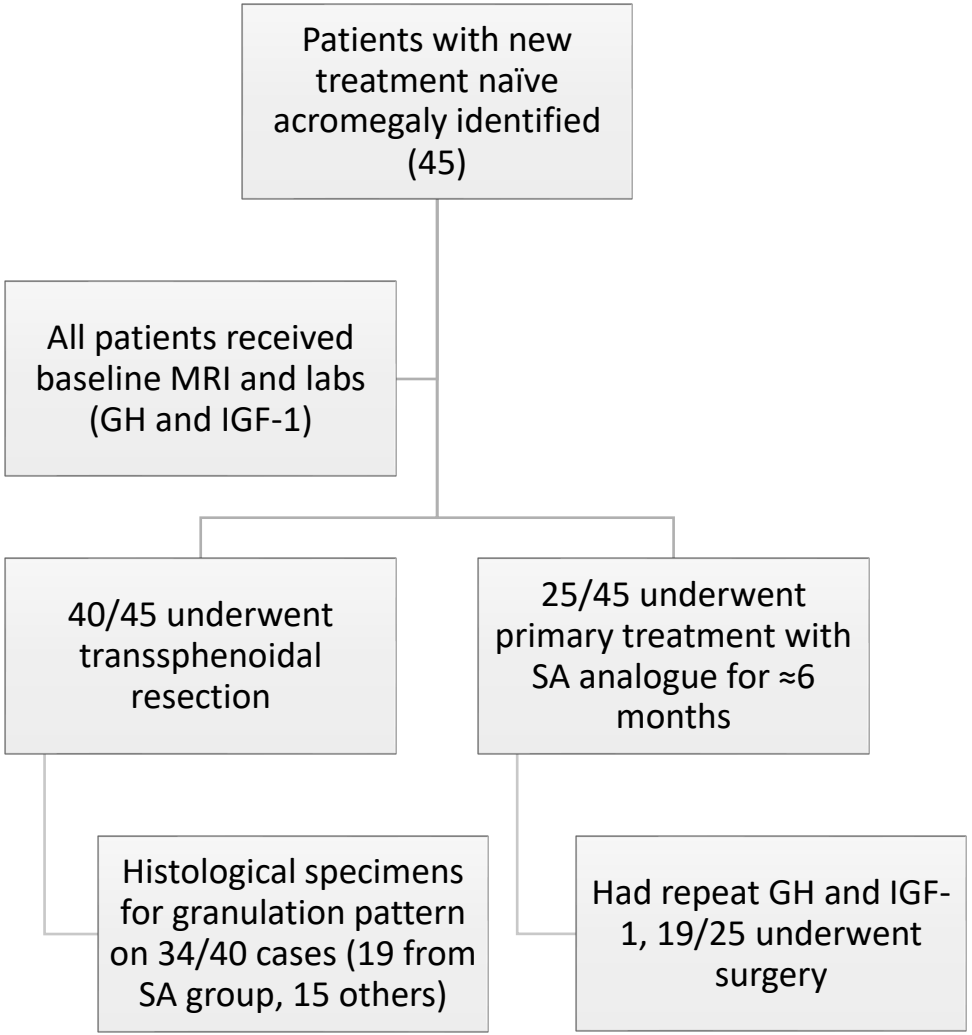

Material and Methods Cont.

- Prior to treatment, patients GH response to octreotide was measured
- IGF-1 expressed as measured value/age adjusted ULN
- All MRIs evaluated by 2 blinded neuroradiologists
- T2 signal of solid portion of mass compared to adjacent temporal lobe grey and white matter
  - Equal or less than white matter = hypointense
  - Equal or greater than grey matter = hyperintense
  - Between white and grey matter = isointense
- Tumors classified histologically as densely, transitional, or sparsely granulated based on CAM5.2 staining

T2 intensity

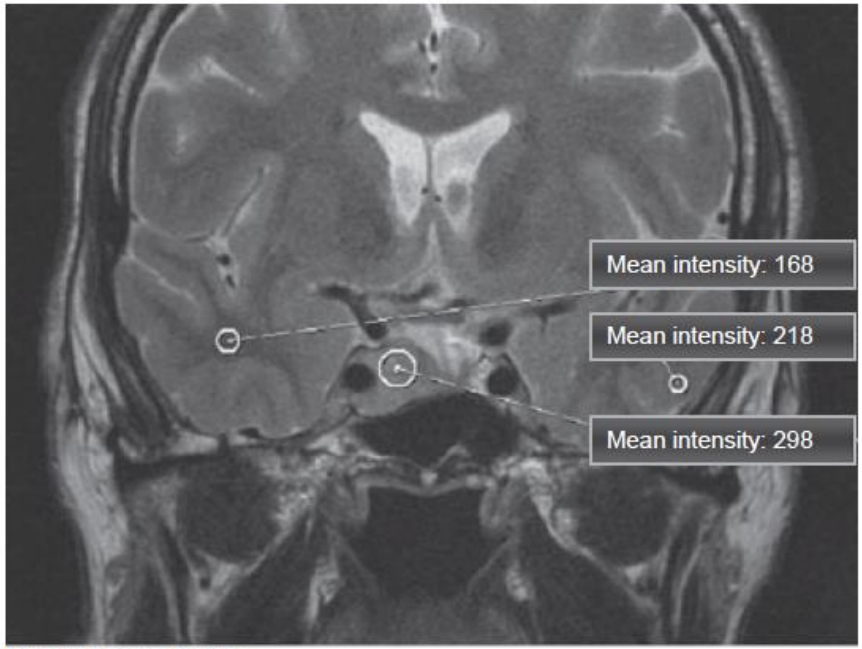

Hyperintense adenoma

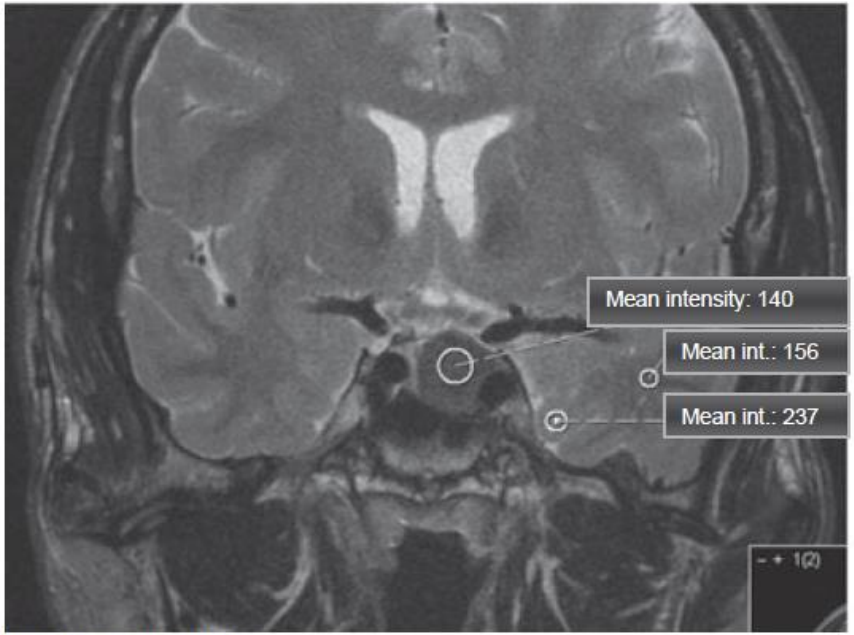

Hypointense adenoma

Results

Table 1. Demographic data and baseline characteristics; median (interquartile range)

Groups, baseline	Hypointense	Isointense	Hyperintense	*P*
n (*n* = 45)	12	15	18	
Age at diagnosis (years)	54·5 (44·5–63)	46 (37–60)	46·5 (30·5–56·5)	0·20
Women/men	5/7	7/8	9/9	0·90
Serum GH (μg/l)*	17·5 (6·1–35)	9·3 (6·0–32·5)	4·1 (1·5–8·3)	0·025
IGF-1 (mmol/l)	137 (76–148)	125 (89–125)	81 (65–104)	0·053
IGF-1 (Ratio IGF-1/ULN)*	3·5 (2·3–4·9)	2·9 (2·6–3·8)	1·9 (1·3–2·6)	0·006
Tumour volume (cm^3)	1·53 (0·33–3·27)	1·01 (0·50–2·19)	2·01 (0·78 –6·13)	0·26
Short octreotide test (*n* = 41)	10	15	16	
Acute GH reduction (%)*	86 (80–90)	87 (66–94)	60 (8–74)	0·002
Nadir (μg/l)	1·1 (0·5–3·1)	0·8 (0·5–4·0)	1·4 (0·7–3·3)	0·64

*$P < 0·05$; Kruskal–Wallis test.

Results: response to SA treatment

Table 2. Response to primary medical treatment with somatostatin analogues (SA); median (interquartile range)

Groups	Hypointense	Isointense	Hyperintense	*P*
Preoperative SA treatment; $n = 25$	7	9	9	
Time to evaluation (days)	174 (160–180)	172 (159–178)	160 (104–188)	0·82
IGF-1 below ULN (no. of patients)	4 of 7	2 of 9	1 of 9	0·059**
IGF-1 reduction (%)*	51 (49–70)	36 (19–74)	13 (1–42)	0·031
GH reduction (%)*	86 (72–94)	78 (62–85)	46 (1–70)	0·015

ULN: upper limit of normal.
*$P < 0·05$; Kruskal–Wallis test; **Fisher's exact test for comparison between hypointense *vs* joint iso- and hyperintense Group.

Results: granulation pattern

Table 4. T2 weighted MRI signal intensity and granulation pattern; $P < 0.001$ (Fisher's exact test)

Groups	Hypointense	Isointense	Hyperintense
Densely granulated (DG; $n = 12$)	5	6	1
Transitional group (TG; $n = 14$)	5	5	4
Sparsely granulated (SG; $n = 8$)	0	0	8
Total, $n = 34$	10	11	13

Discussion

- At baseline, hyperintense adenomas had lower GH and IGF-1 levels despite younger age and larger tumors
  - Possible that different subgroups of GH secreting pituitary adenomas exist or that the hyperintense adenomas have some “silent” features
- T2 intensity predictive of SA response
  - model performed best when combined with octreotide test
- Increased SA response rate in T2 hypointense adenomas
  - Less than other studies

Discussion Cont.

- Sparsely granulated adenomas associated with T2 hyperintensity
  - Has been shown that sparsely granulated adenomas respond poorly to octreotide treatment
  - This study links all three variables together in analysis

Hold On!

- Retrospective
  - Varying lengths of SA treatment (not significant)
  - GH and IGF-1 measurement technique varied over time
  - Octreotide dosage not standard, although most patients received the same dose
  - MRI scanner and protocol not consistent
- Non randomized, patients chosen for SA treatment based on clinical judgement
  - Not a representative sample, limited external validity
- Histological specimens after SA treatment

Module Outline

I. Case

II. Background

III. Article Overview

IV. Clinical Questions

V. Key Points

Clinical Questions

- At UNC – is preoperative/primary medical treatment ever used in acromegaly patients? If so how is it decided whether a patient is a good candidate?
- Is T2 intensity standardly evaluated in pituitary adenomas?

Module Outline

I. Case

II. Background

III. Article Overview

IV. Clinical Questions

V. Key Points

Key Points

- T2 intensity is correlated with GH and IGF-1 level, granulation pattern, and response to SA treatment
- The goal of GH-secreting pituitary adenoma treatment is biochemical control
- Transphenoidal surgery is the primary treatment modality, however medical management is indicated in certain cases
- T2 intensity is a useful factor in evaluating someone as a candidate for SA trial in treating acromegaly

References

- Heck, Ansgar, et al. "Intensity of pituitary adenoma on T2-weighted magnetic resonance imaging predicts the response to octreotide treatment in newly diagnosed acromegaly." Clinical endocrinology 77.1 (2012): 72-78.
- Molitch, Mark E. "Diagnosis and treatment of pituitary adenomas: a review." Jama 317.5 (2017): 516-524.
- Zahr, Roula, and Maria Fleseriu. "Updates in diagnosis and treatment of acromegaly." European endocrinology 14.2 (2018): 57.
- Katznelson, Laurence, et al. "Acromegaly: an endocrine society clinical practice guideline." The Journal of Clinical Endocrinology & Metabolism 99.11 (2014): 3933-3951.
- Buchfelder, Michael, and Sven-Martin Schlaffer. "The surgical treatment of acromegaly." Pituitary 20.1 (2017): 76-83.