Localizing Mammographic Lesions

Kelsey Williamson, MS4

January 2020

UNC SCHOOL OF MEDICINE
Radiology

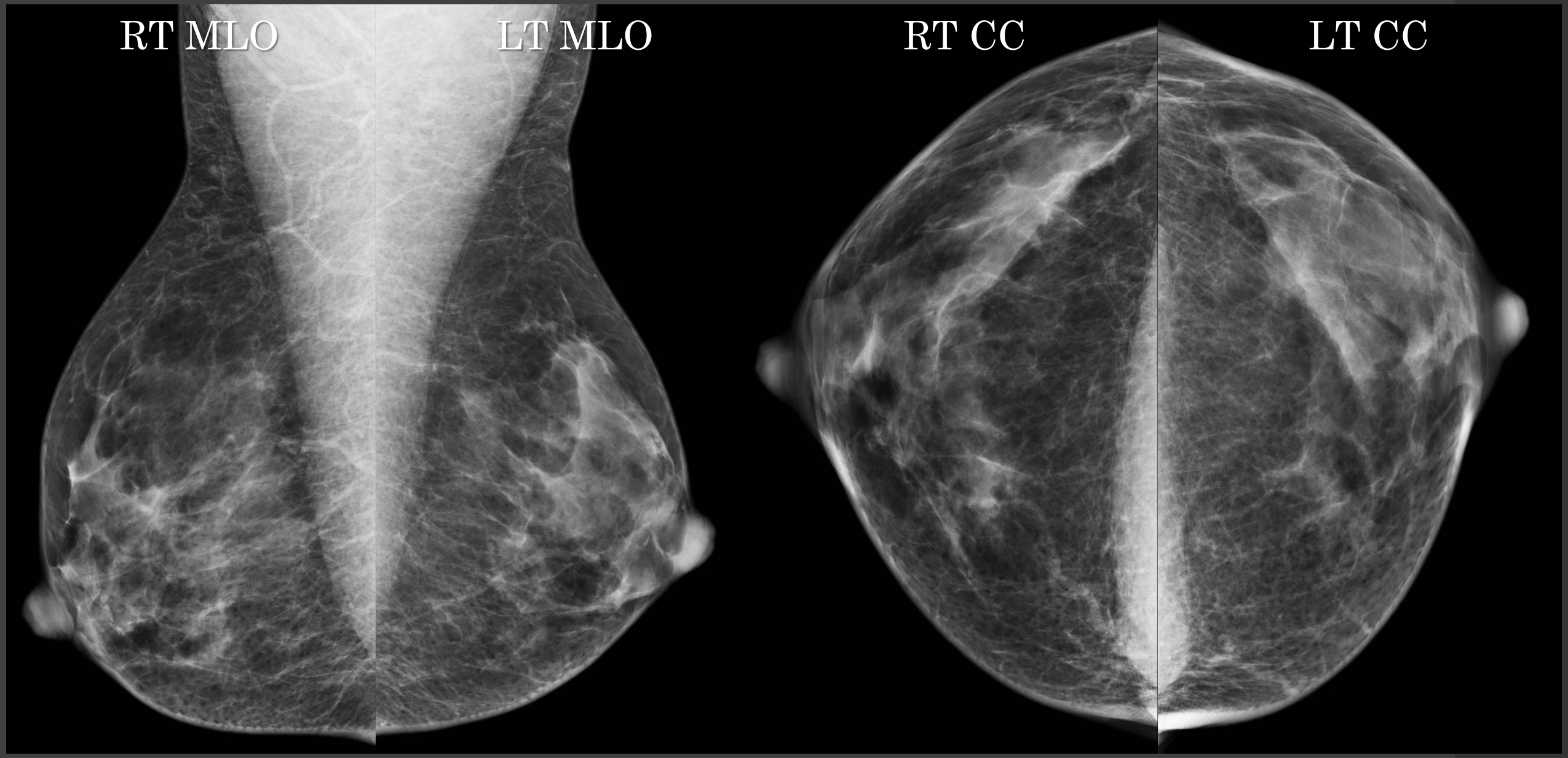

Standard Mammographic Compression Views

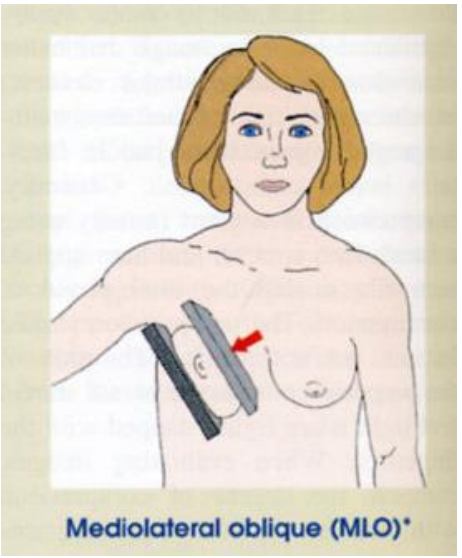

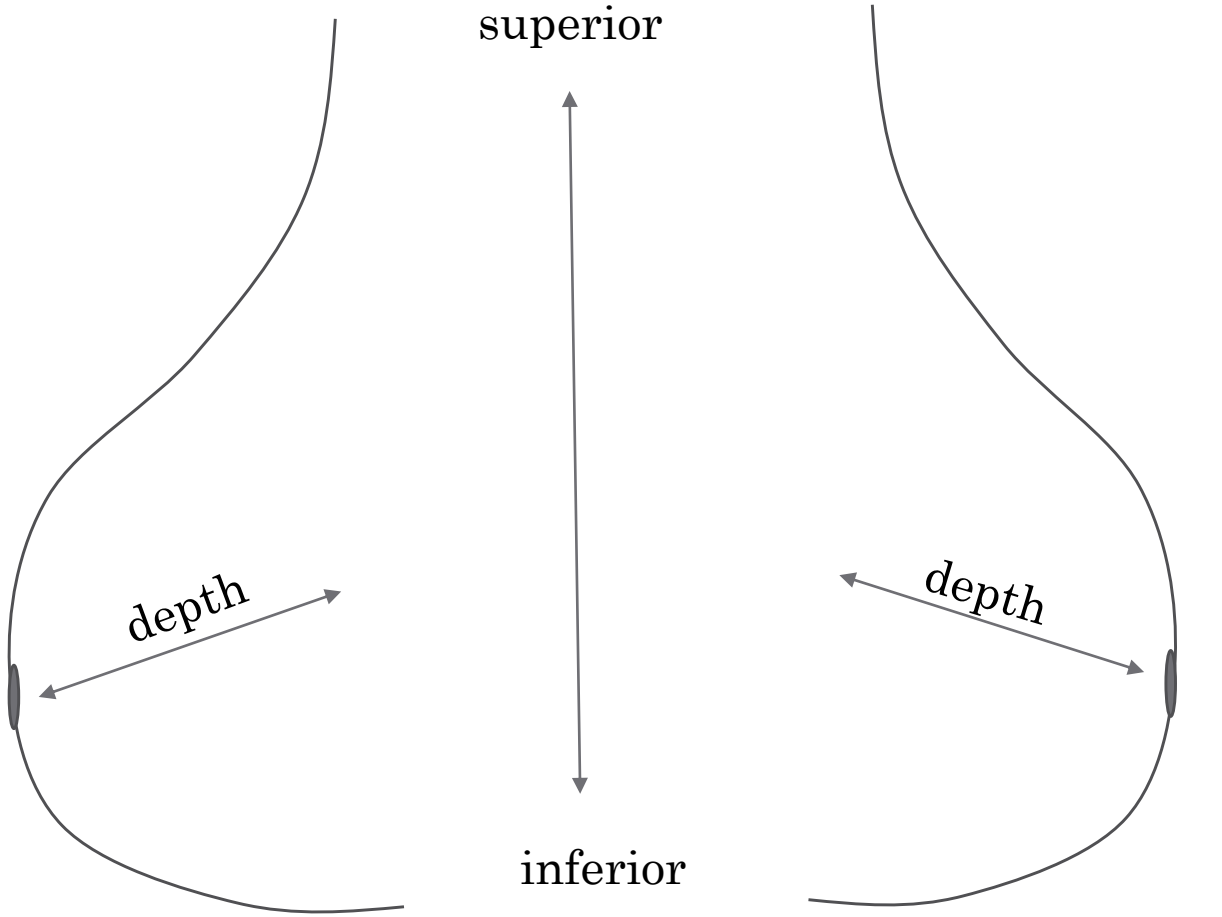

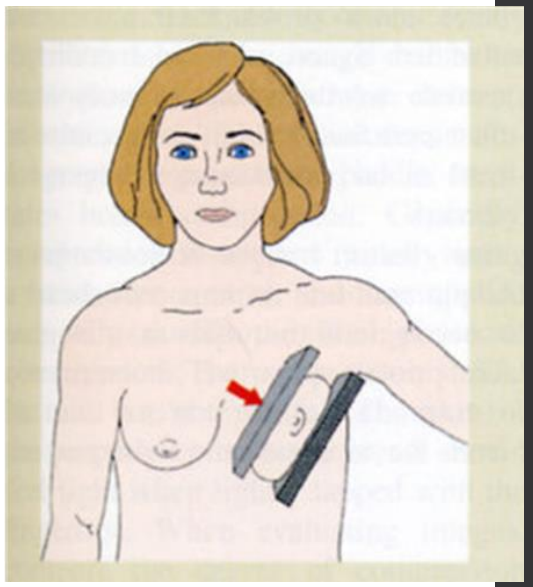

Standard Mammographic Compression Views

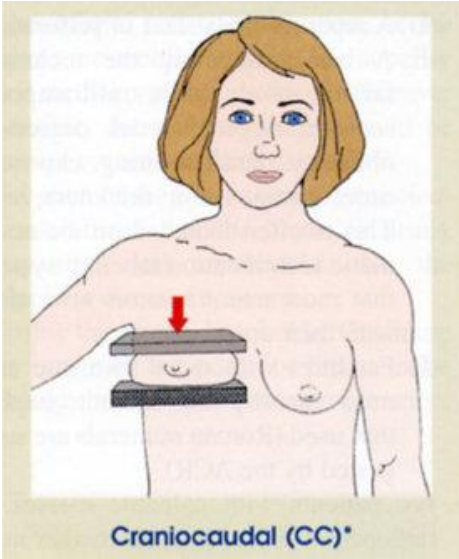

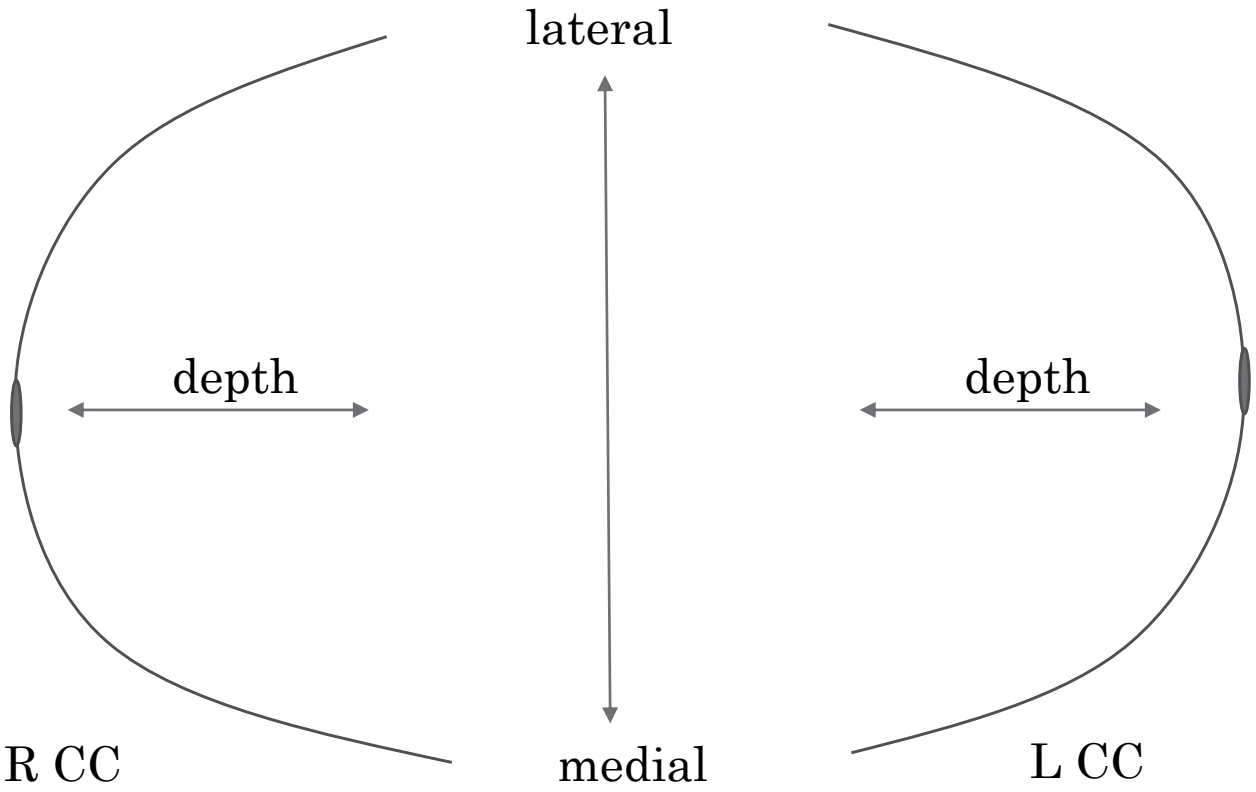

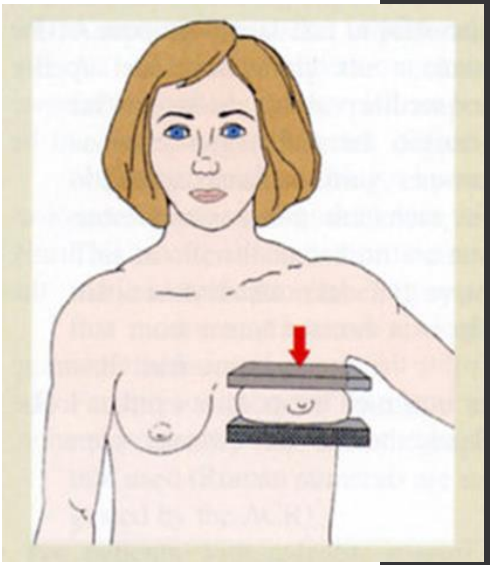

So let's put it together on the right…

- Together the MLO and CC views translate into:
  - **quadrants** – used in mammography reports
  - **clockface** – used in sonography reports

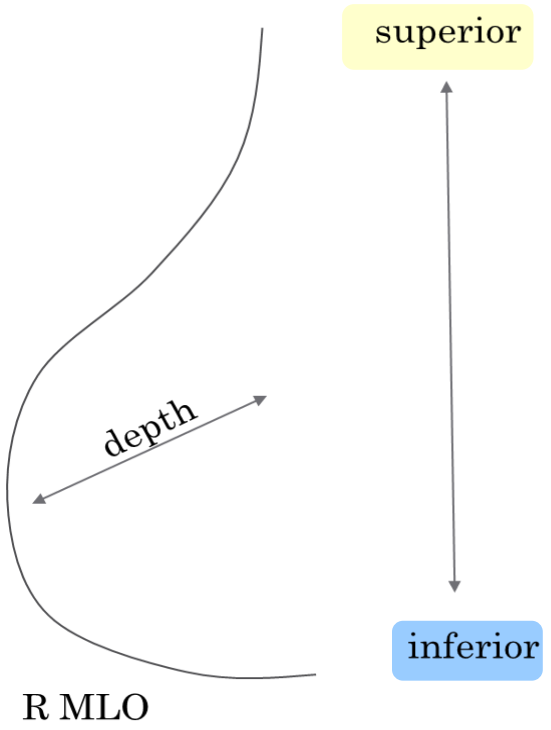

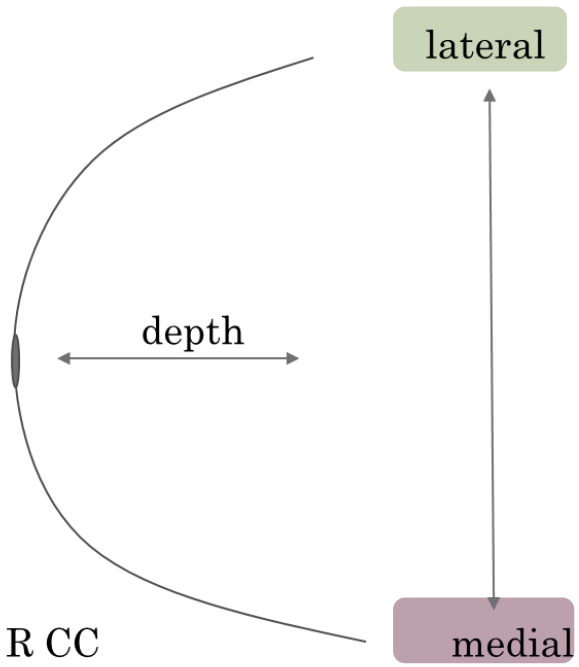

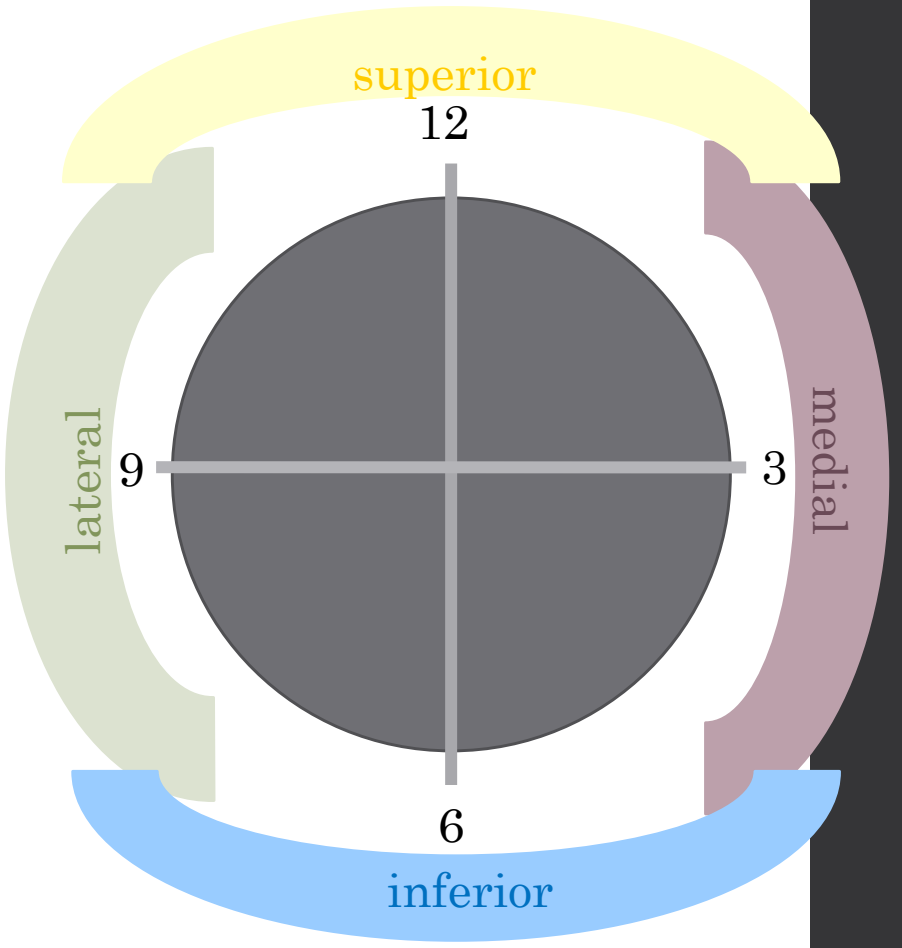

And the left …

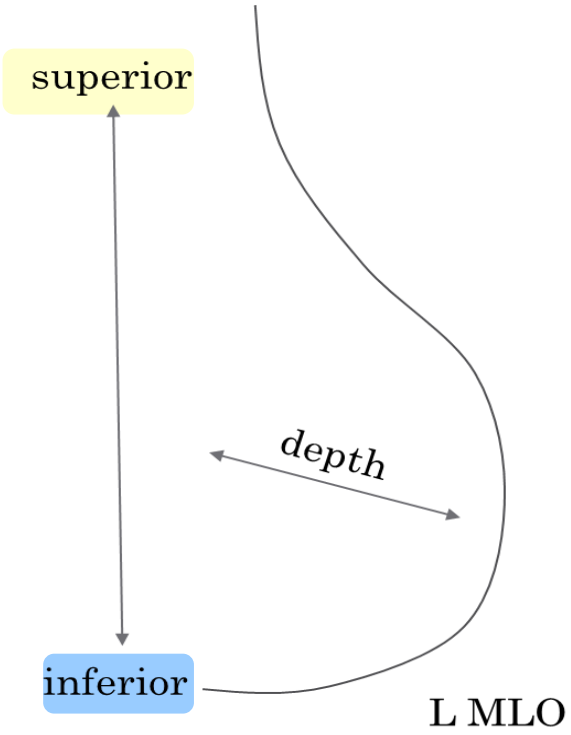
superior
depth
inferior
L MLO

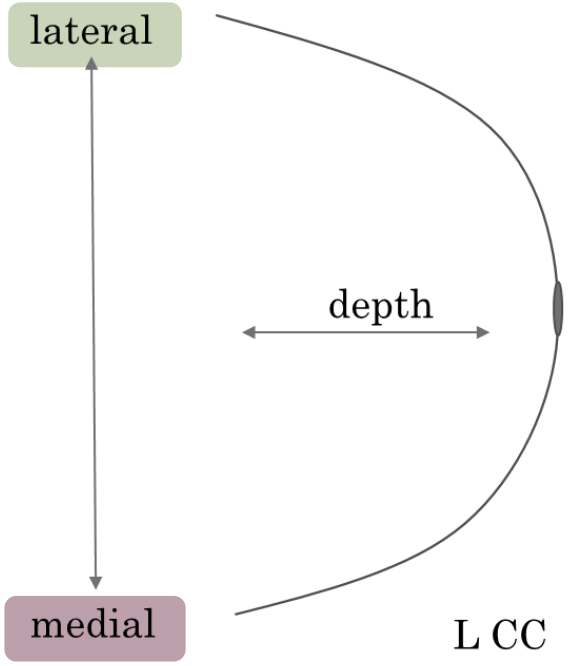
lateral
depth
medial
L CC

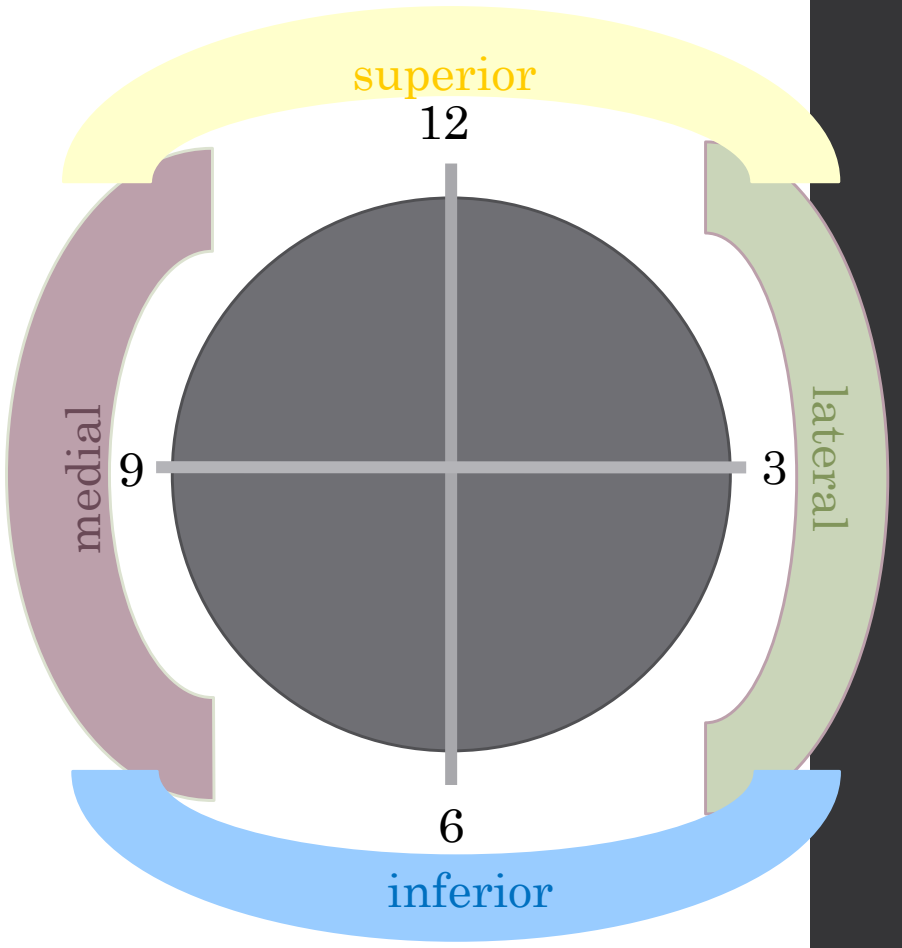
superior
12
medial
9
3
lateral
6
inferior

And one more thing…

- For the four quadrants, use upper, lower, outer, inner as lexicon
  - **Upper outer**
  - **Upper inner**
  - **Lower outer**
  - **Lower inner**

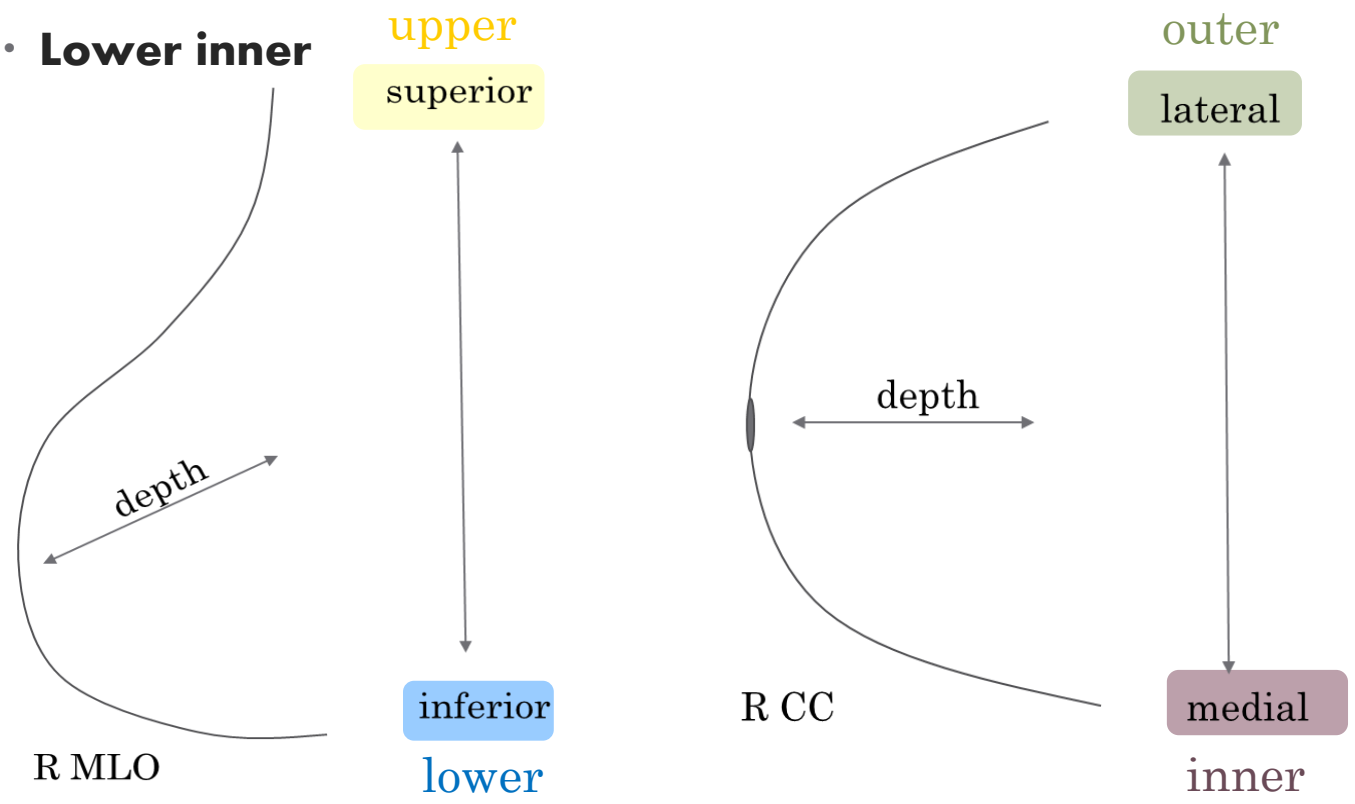

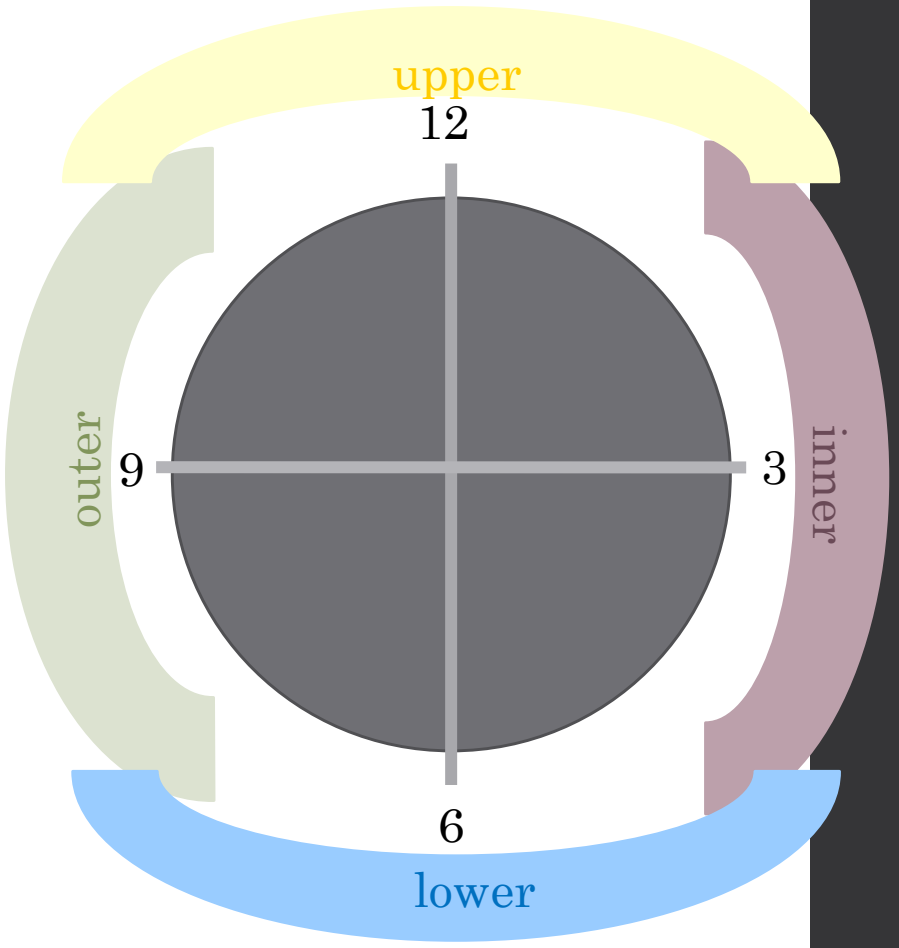

Regardless of whether you look at right or left breast images, the following holds true:

- **Upper** is always **up** on MLO

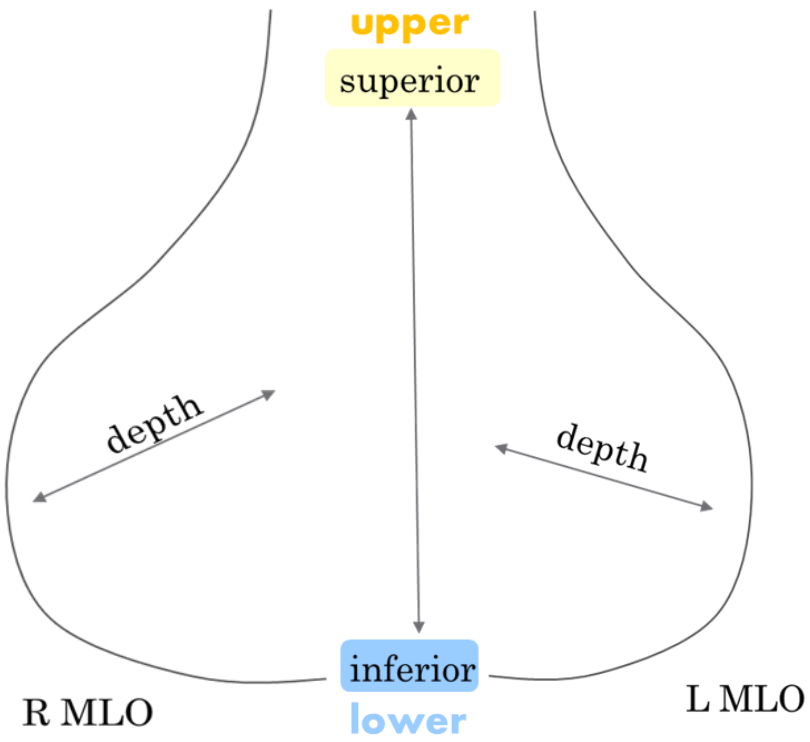

- **Lower** is always **down** on MLO

- **Outer** is always **up** on CC

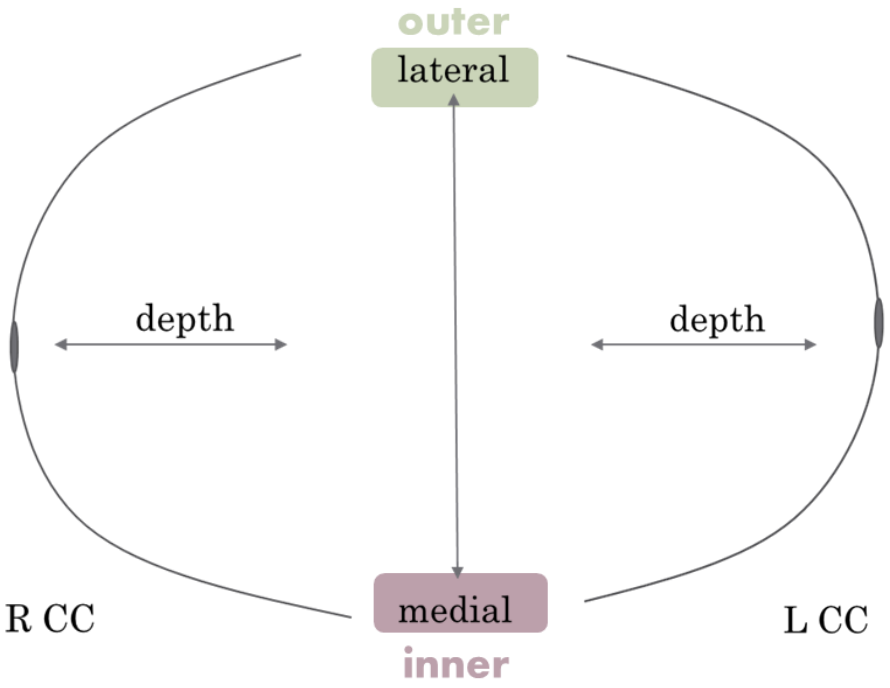

- **Inner** is always **down** on CC

And once you identify the quadrant on mammo, you can predict US clock location

- Right Breast
  - UIQ – 12 to 3
  - LIQ – 3 to 6
  - LOQ – 6 to 9
  - UOQ – 9 to 12

R v L matters!

i.e. Notice how UIQ is either 12 to 3 on L vs. 9 to 12 on R

- Left Breast
  - UIQ – 9 to 12
  - UOQ – 12 to 3
  - LOQ – 3 to 6
  - LIQ – 6 to 9

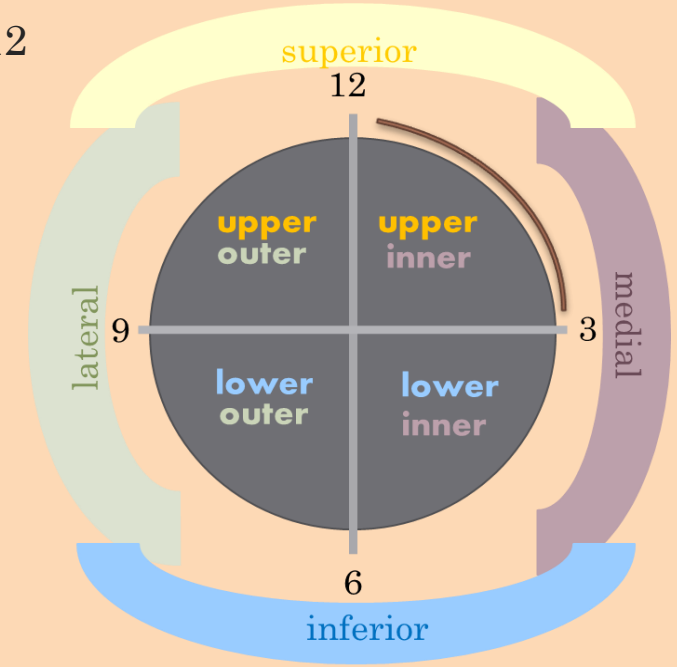

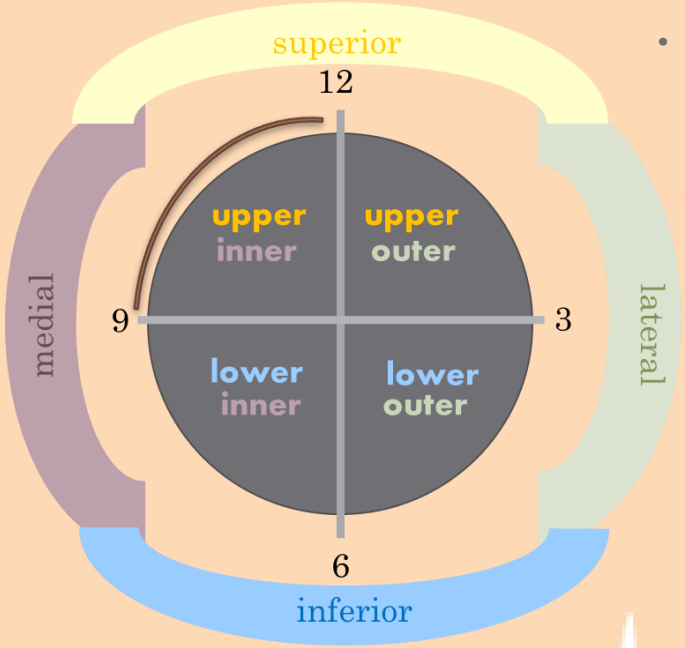

Practice Cases

Case 1

On both MLO and CC:

- Locate lesion – this is an easy one!
- Locate nipple.
- Determine quadrant.

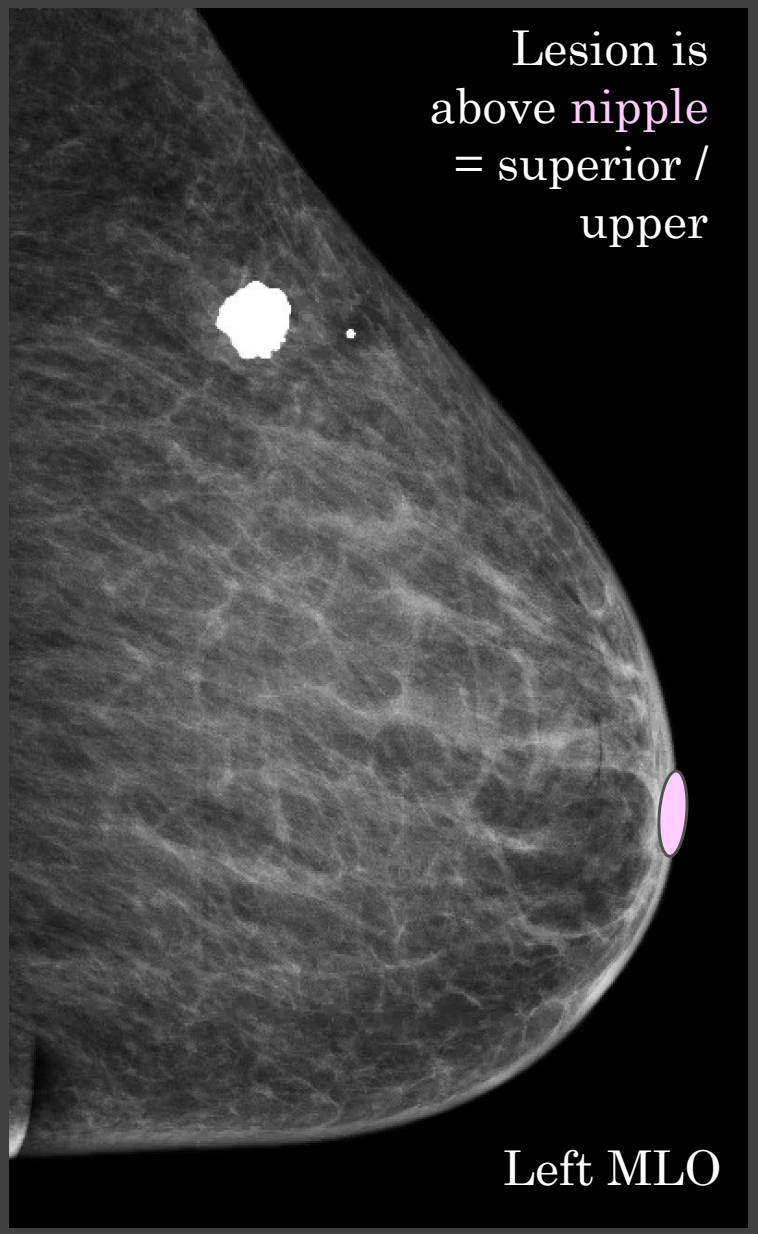

Case 1

Upper Outer

- Fibroadenoma (calcified)

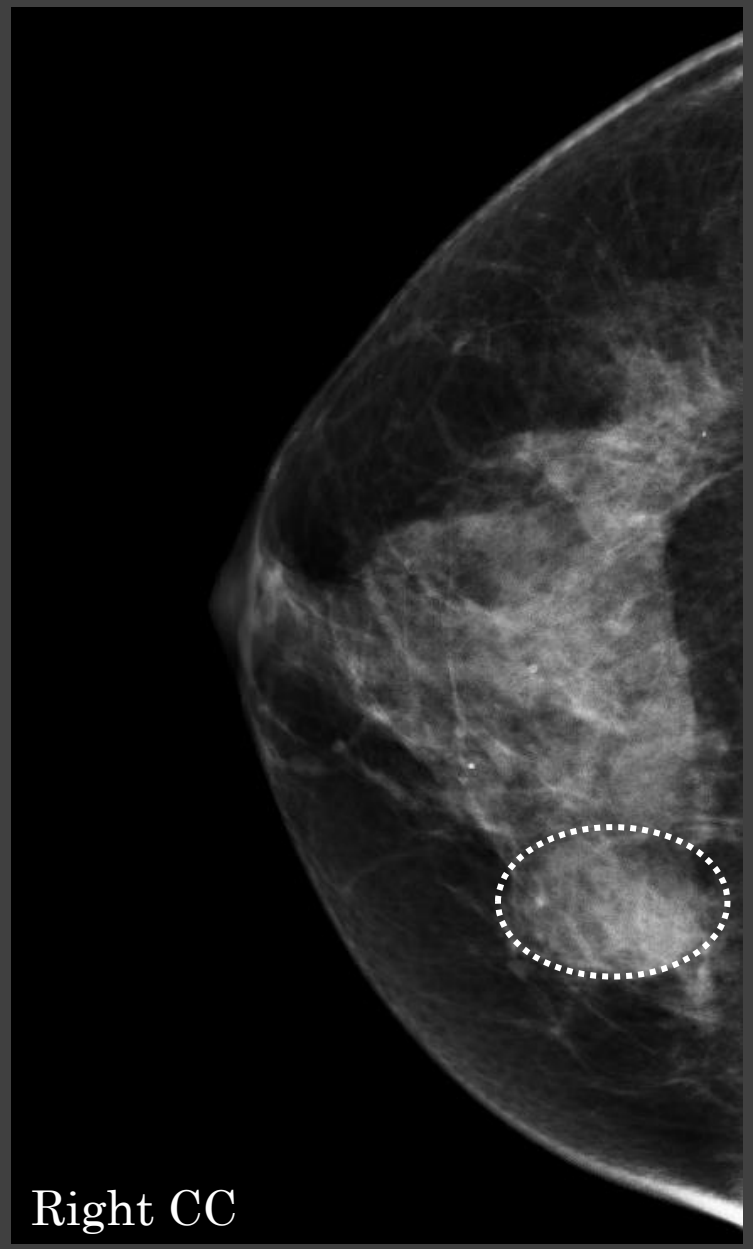

Case 2

On both MLO and CC:

- Locate the lesion.
- Locate the nipple.
- Is lesion above or below the nipple?
- Determine quadrant.

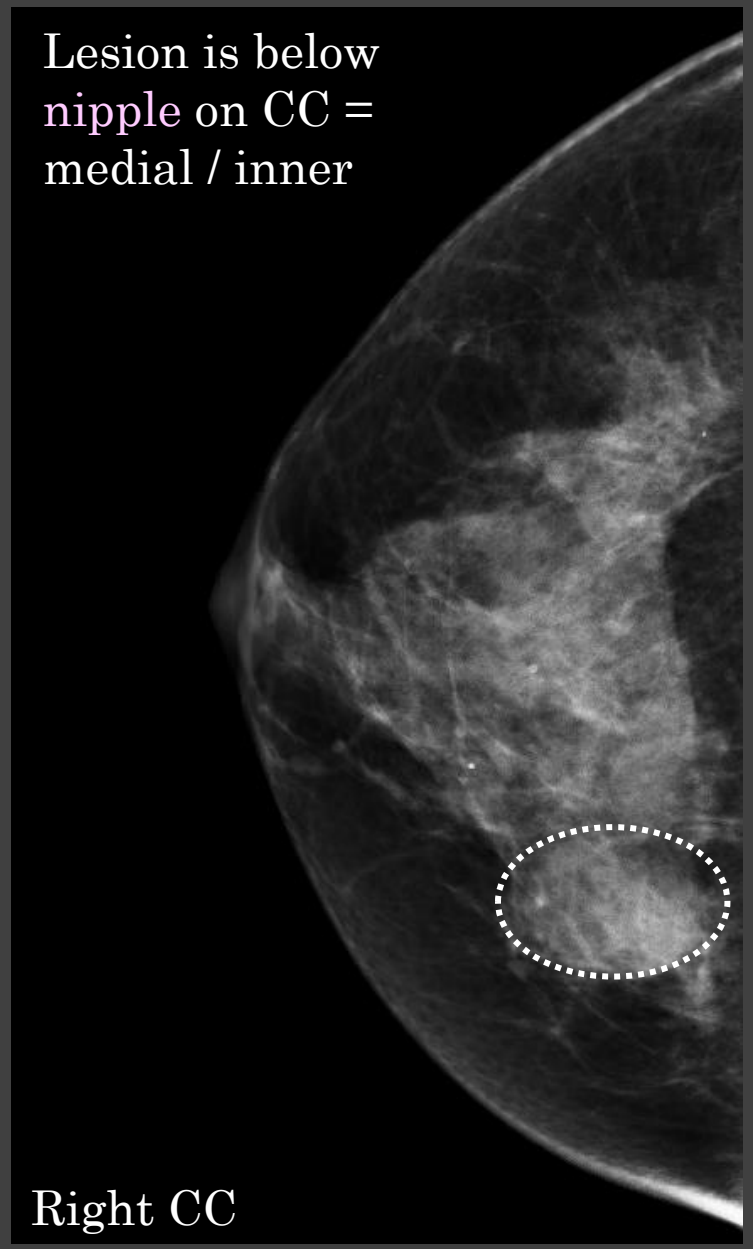

Case 2

Upper Inner

- 2 o'clock

- Found to be a 2cm cyst on ultrasound

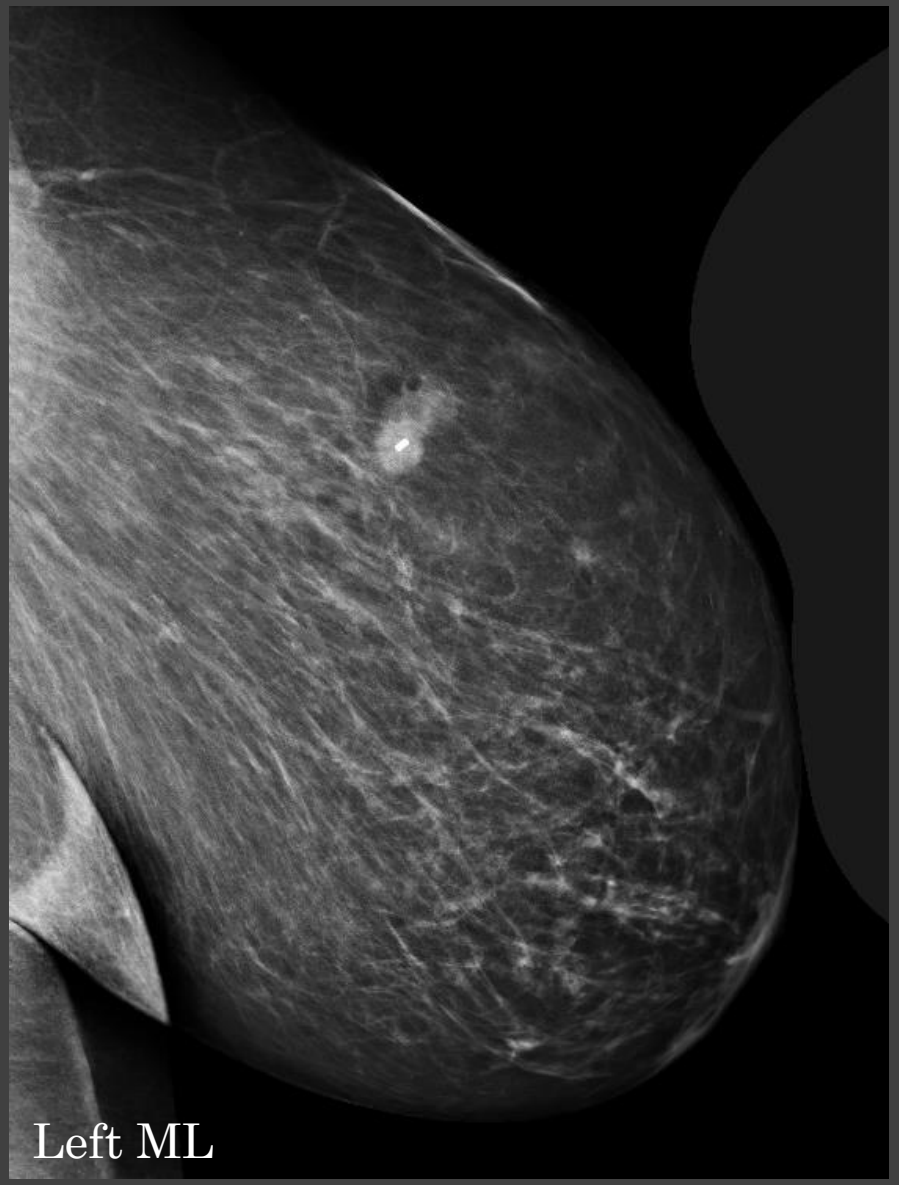

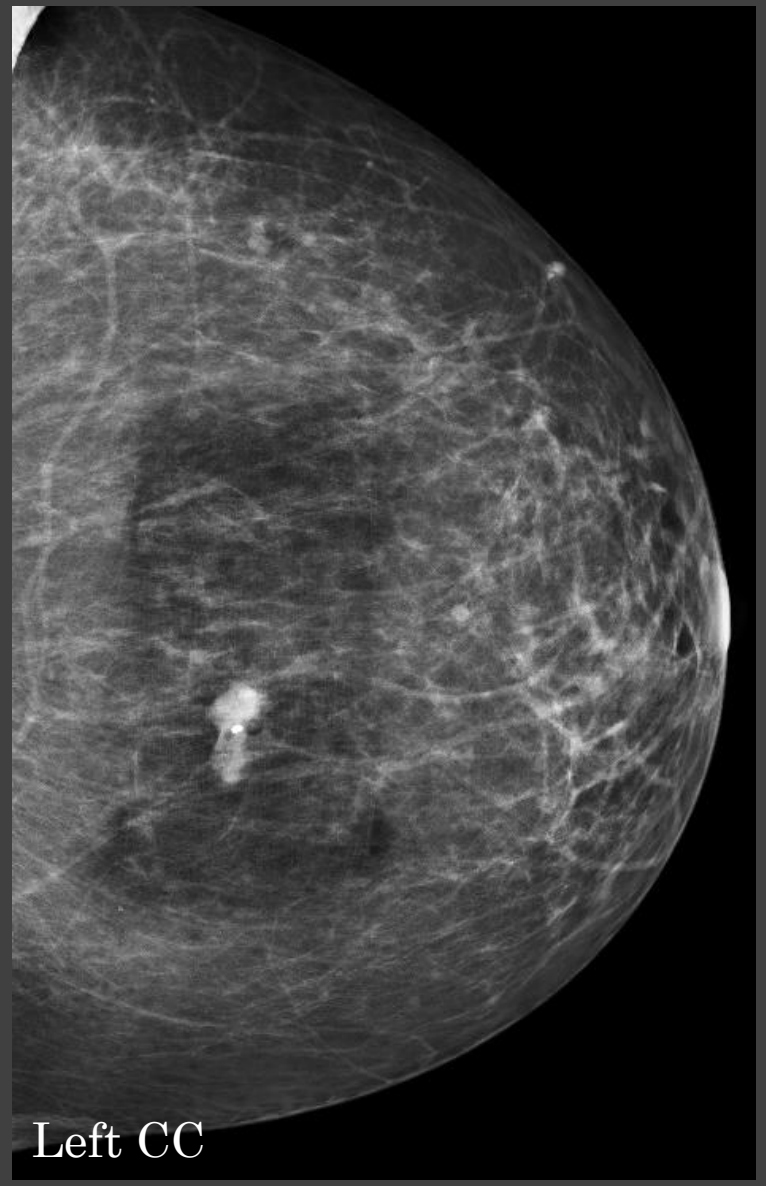

Case 3

On both ML and CC:

- Locate the lesion.
- Locate the nipple.
- Is lesion above or below the nipple?
- Determine quadrant.

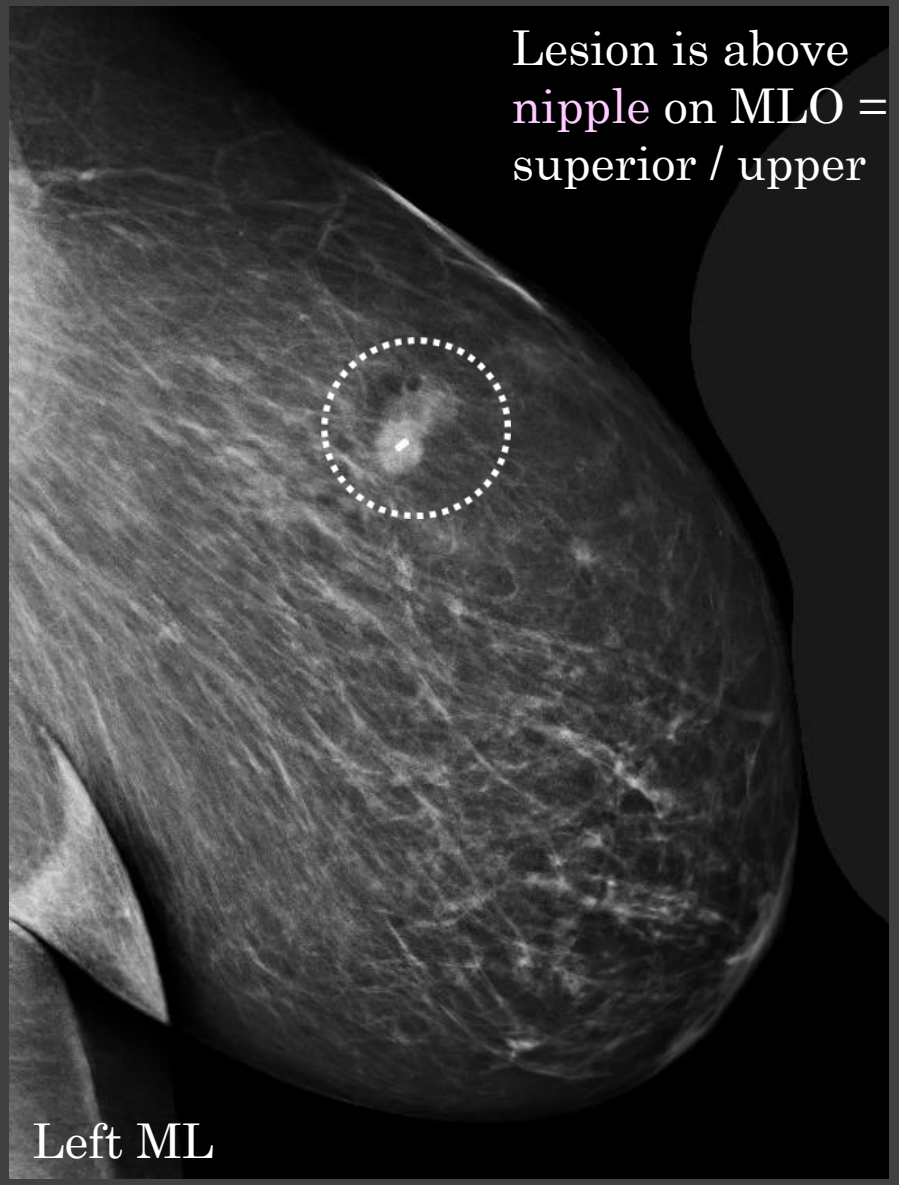

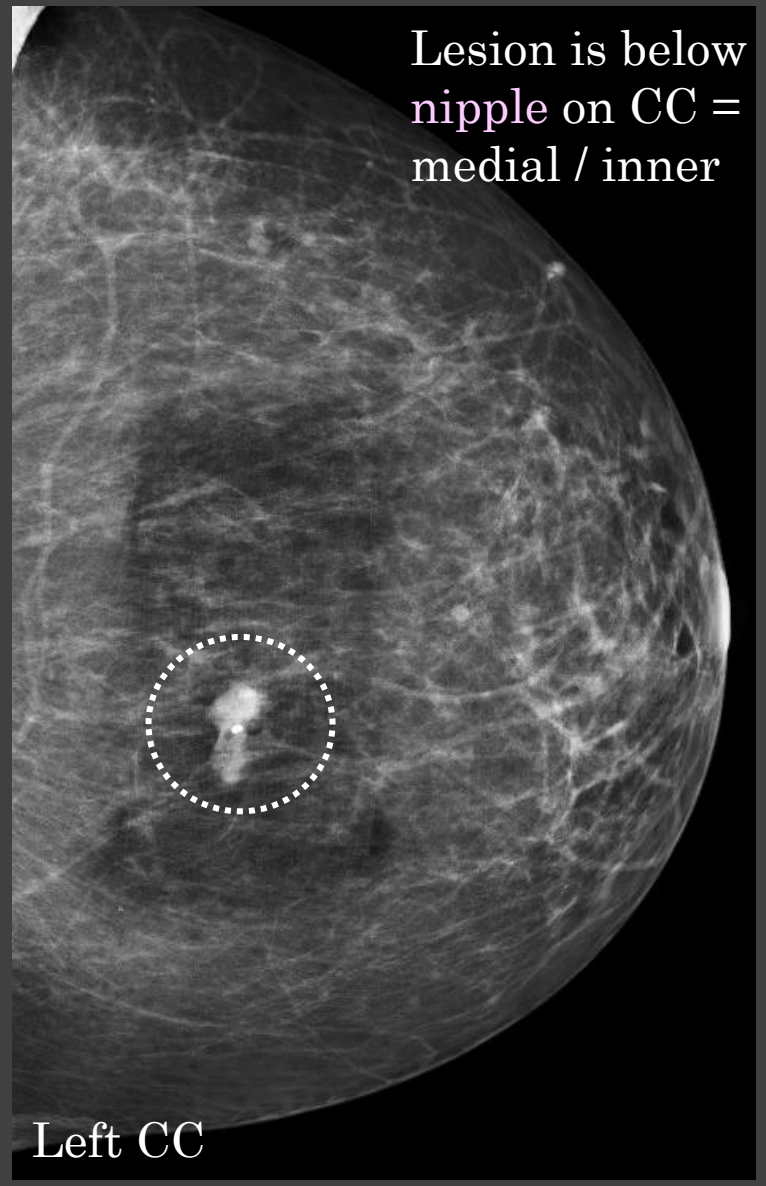

Case 3

Upper Inner

Left MLO

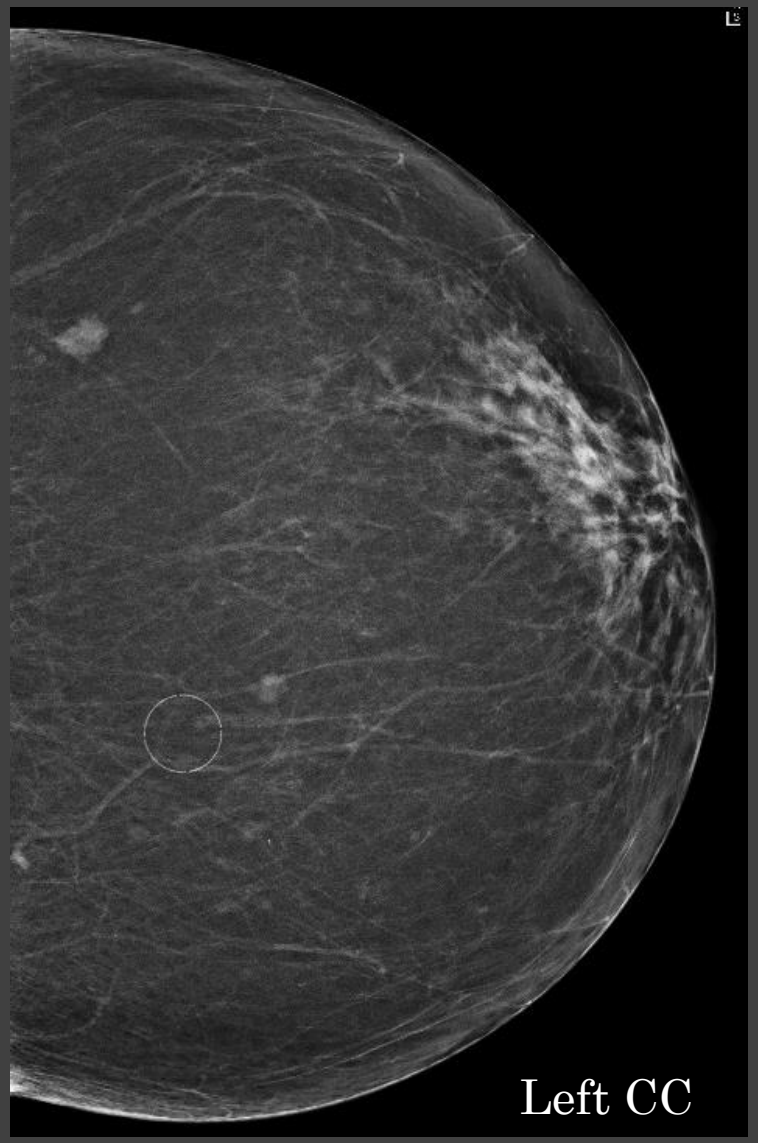

Left CC

Case 4

On both MLO and CC:

- Locate the lesion.
- Locate the nipple.
- Is lesion above or below the nipple?
- Determine quadrant.

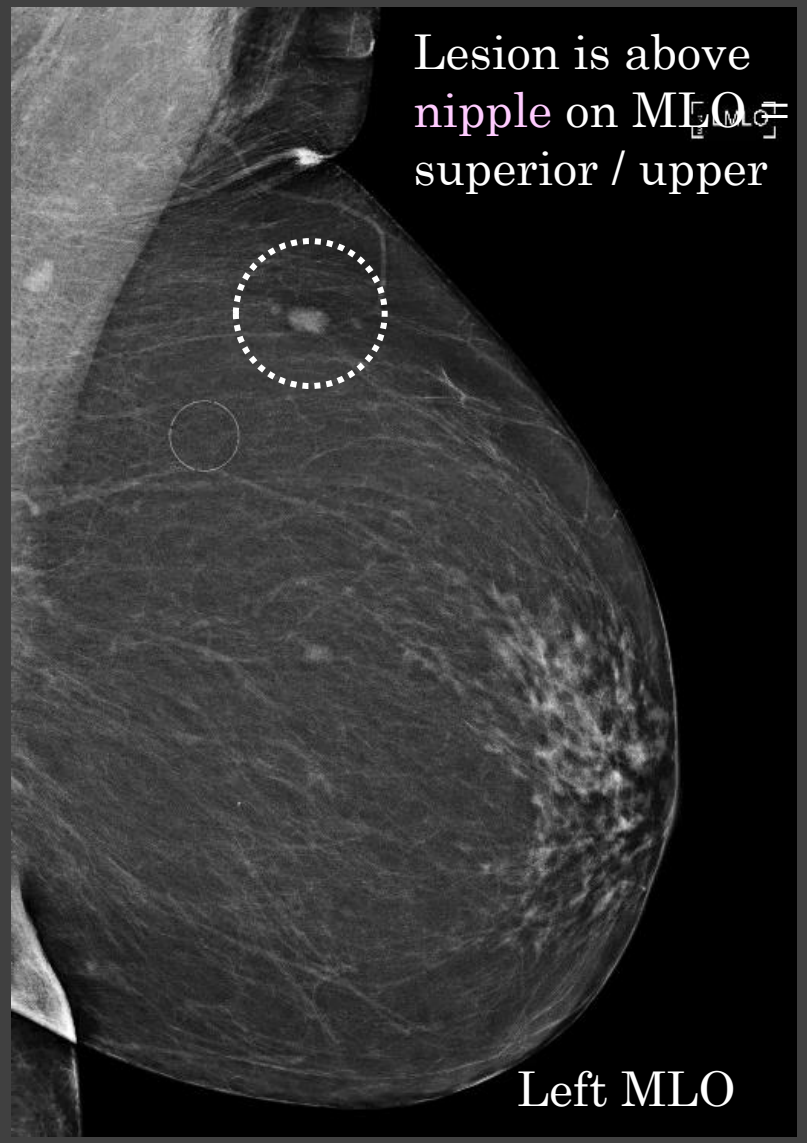

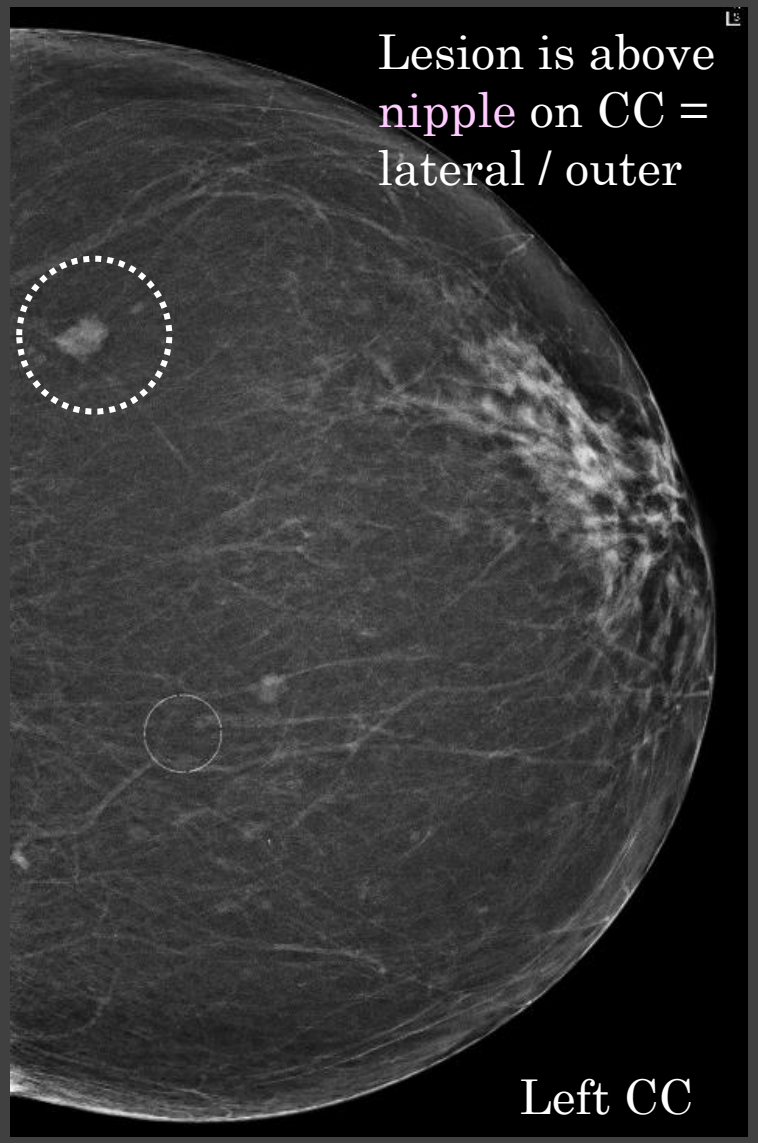

Case 4

Upper Outer

- 1-2 o'clock

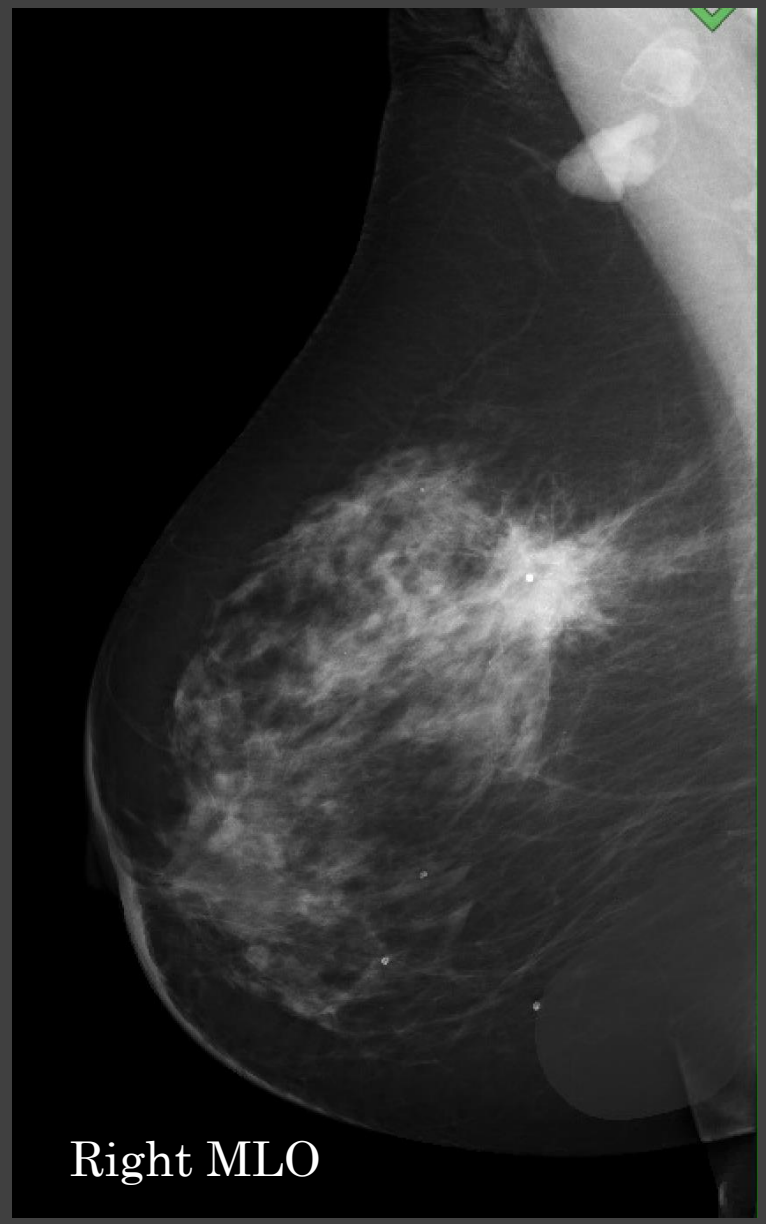

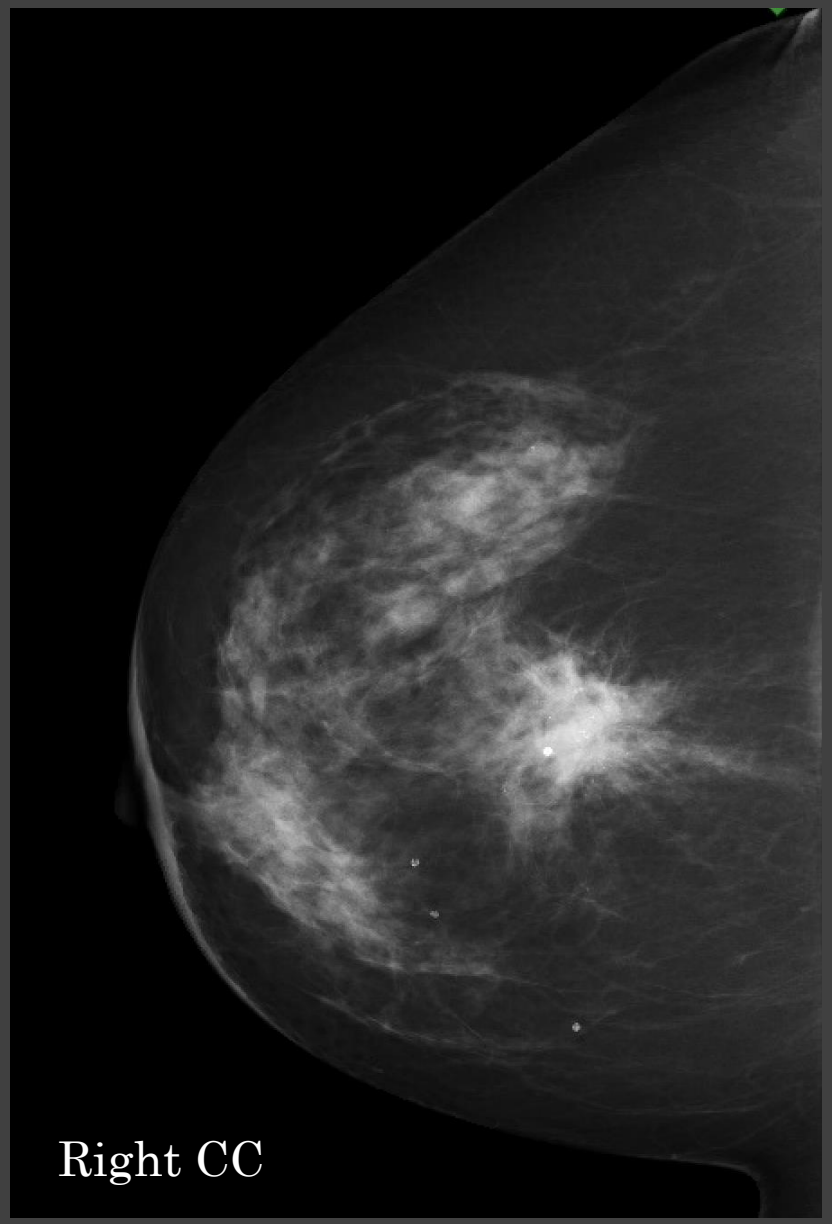

Case 5

On both MLO and CC:

- Locate the lesion.
- Locate the nipple.
- Is lesion above or below the nipple?
- Determine quadrant. If you cannot decide between quadrants, label as superior or inferior.

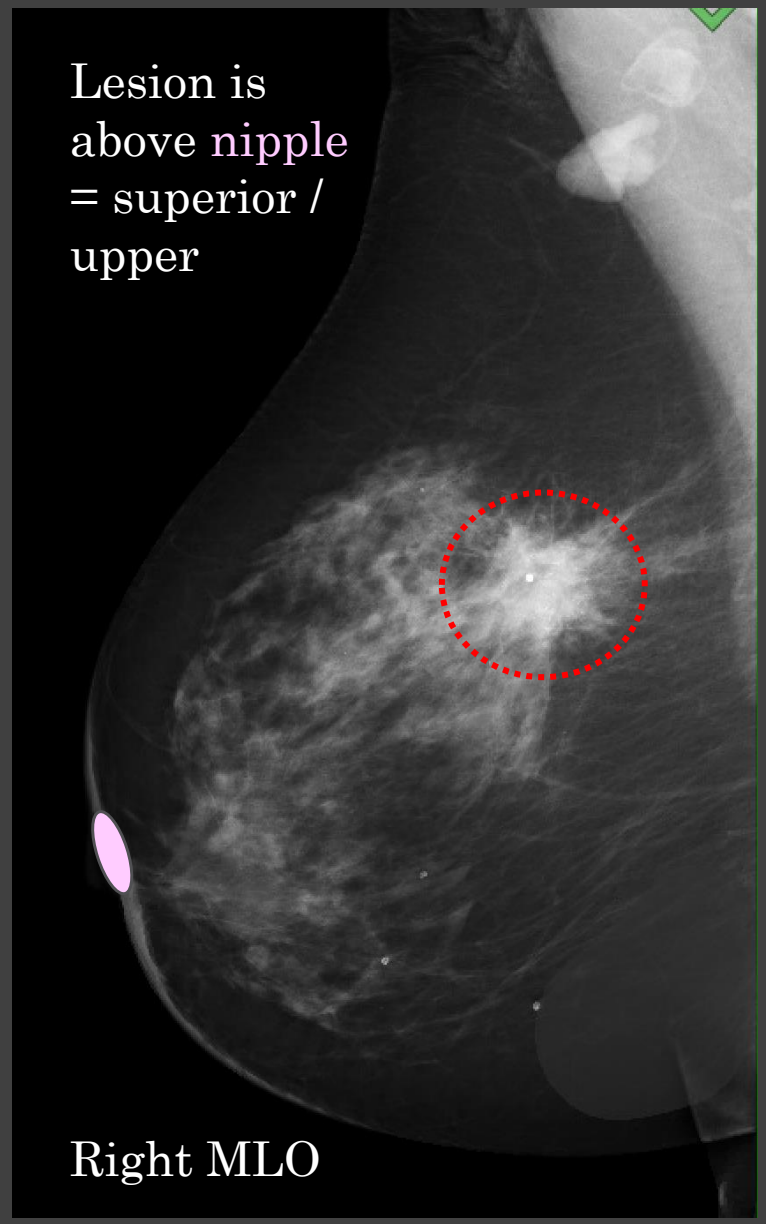

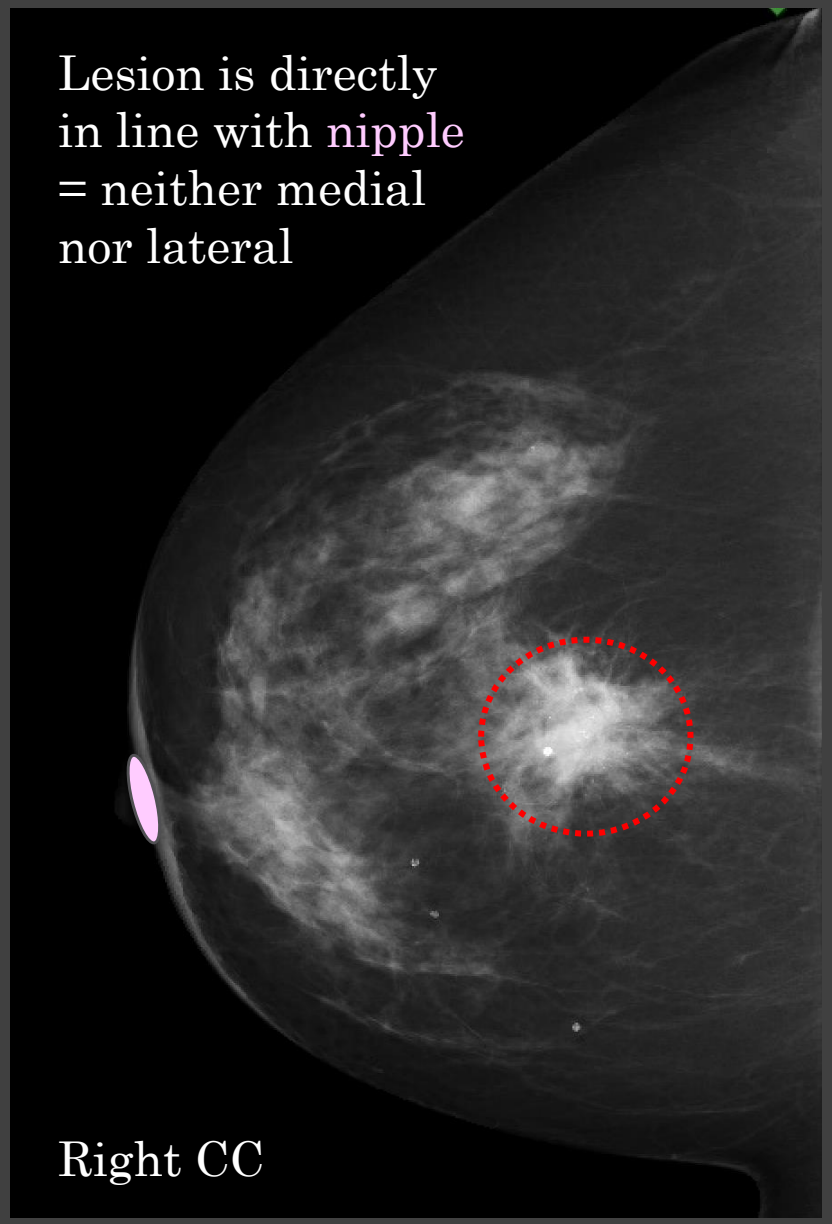

Case 5

Superior

approximately 12 o'clock

- Breast cancer in posterior depth
- And don't miss the axillary lymph node enlargement as result of LN metastases

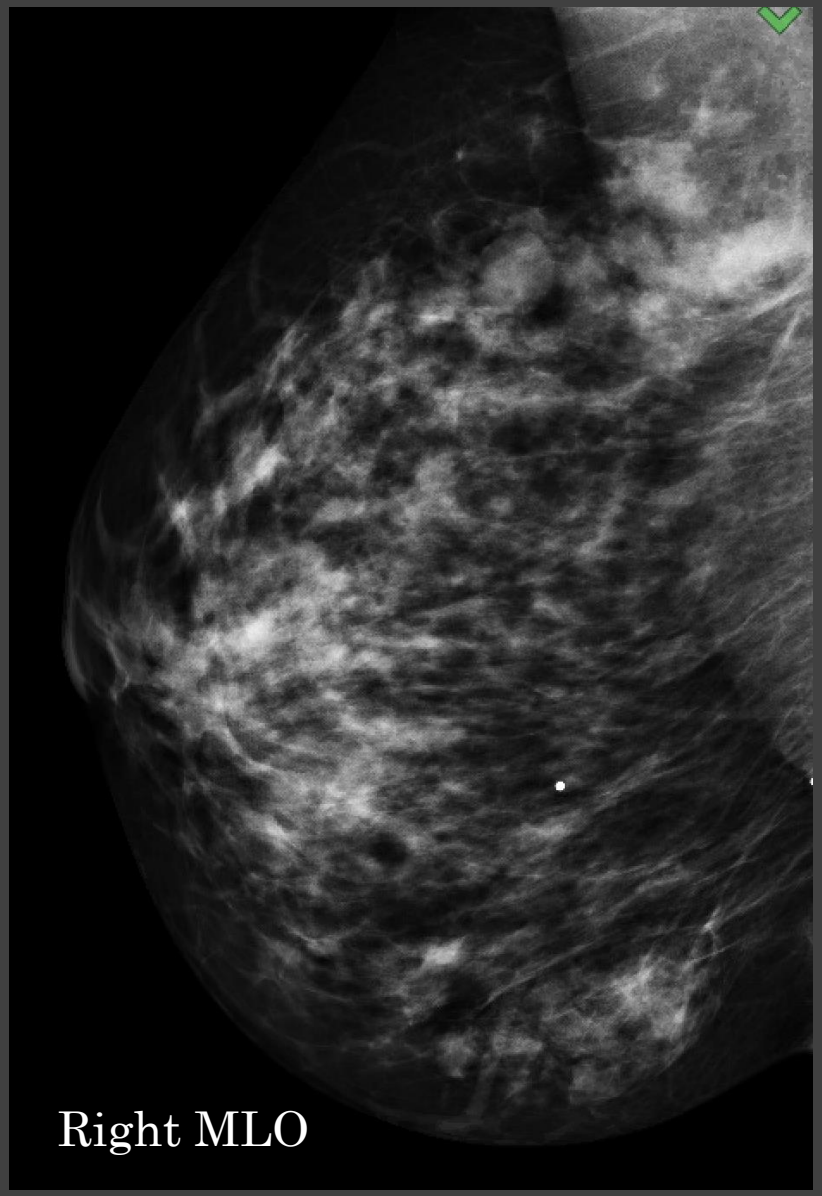

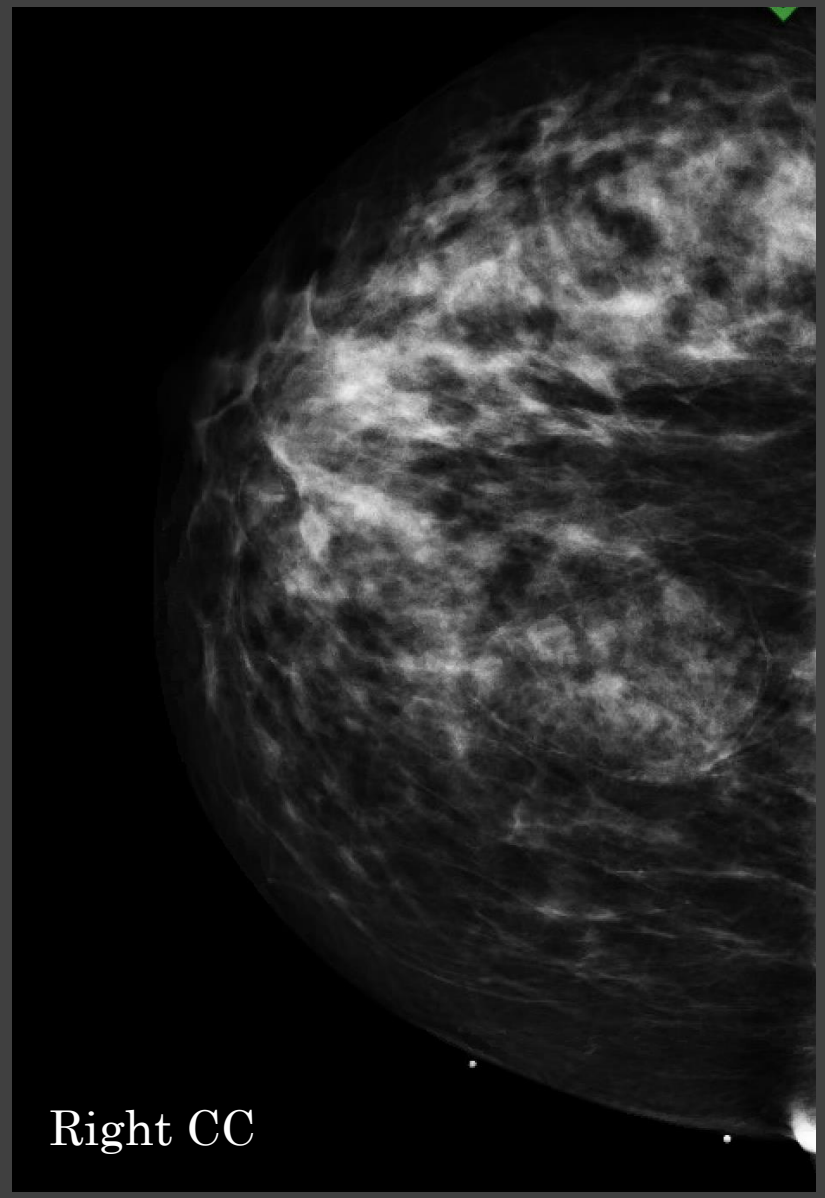

Case 6

On both MLO and CC:

- Locate the lesion.
- Locate the nipple.
- Is lesion above or below the nipple?
- Determine quadrant.

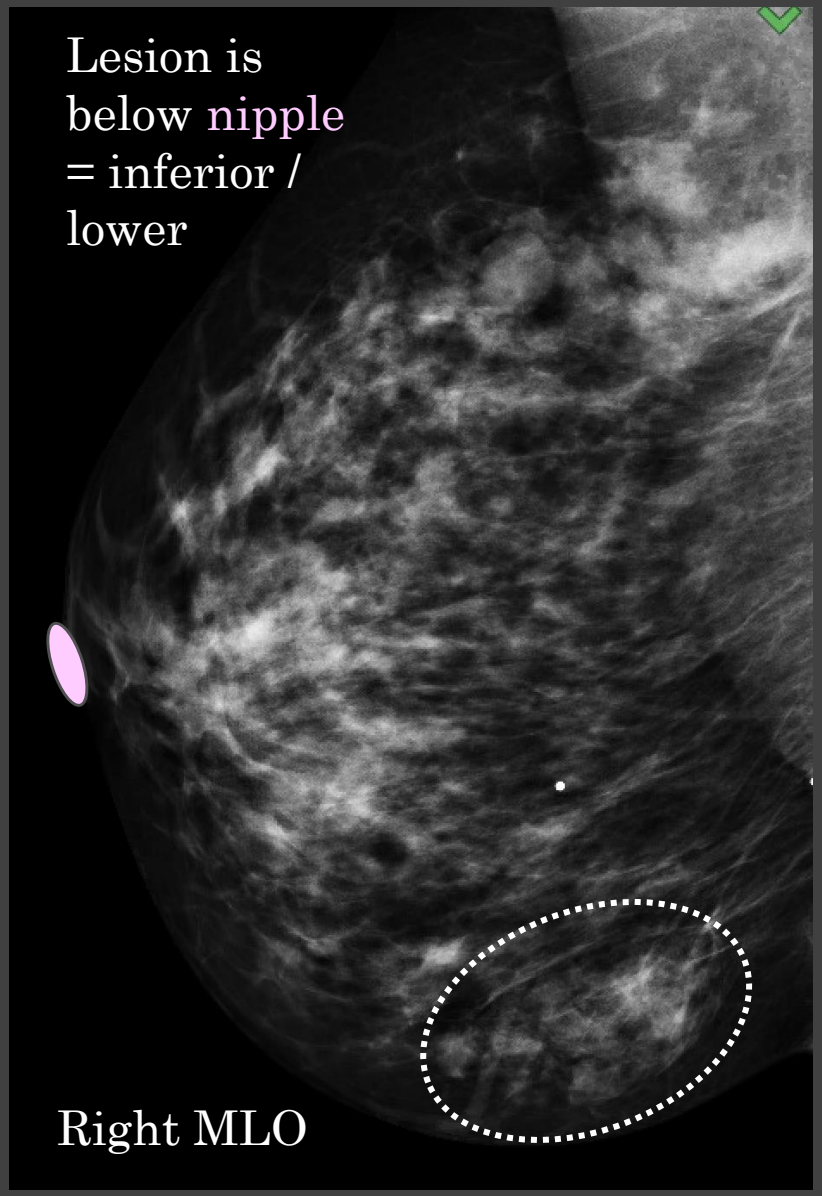

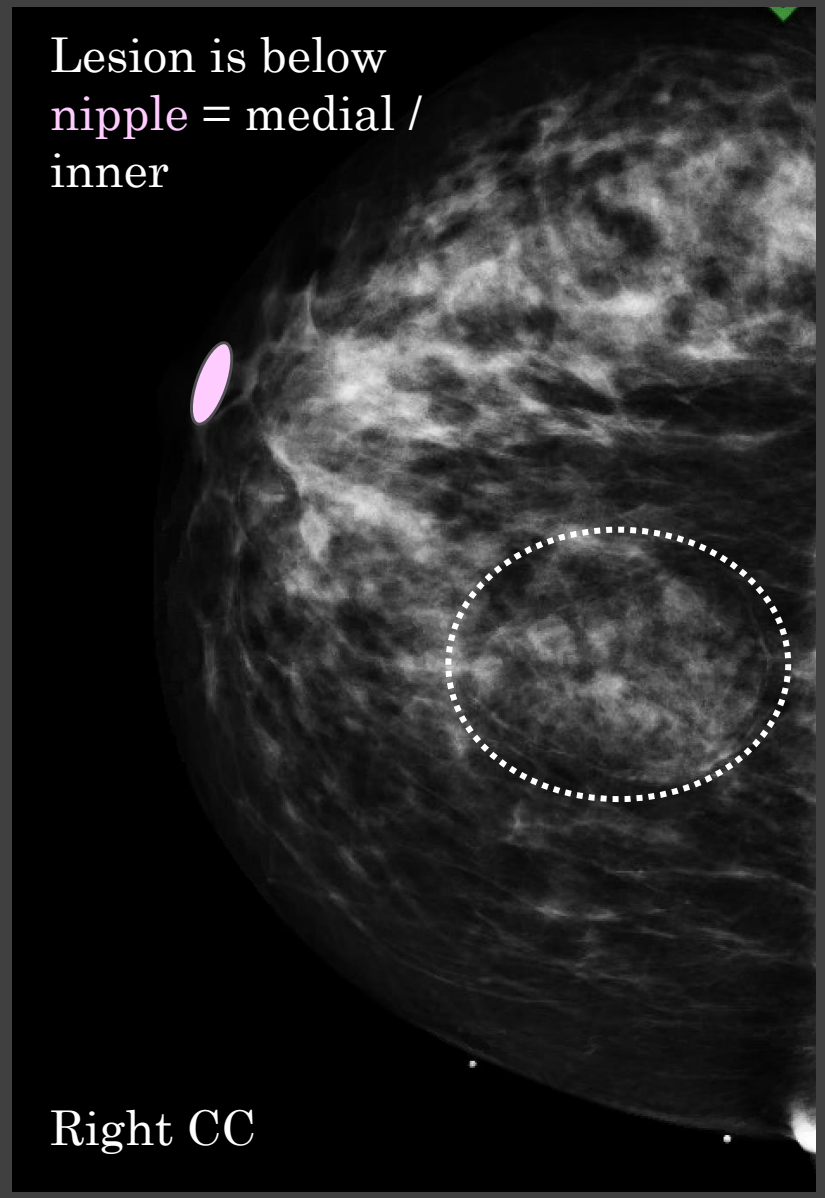

Case 6

Lower Inner

- Hamartoma

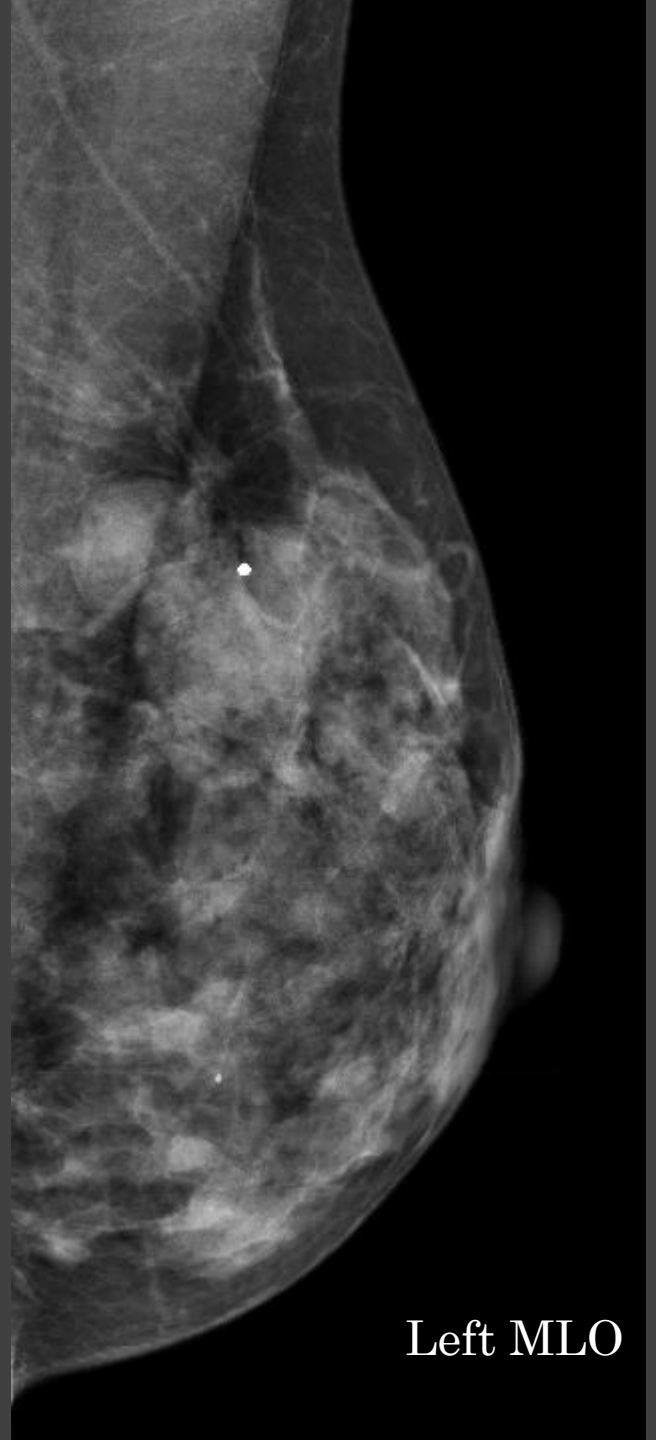

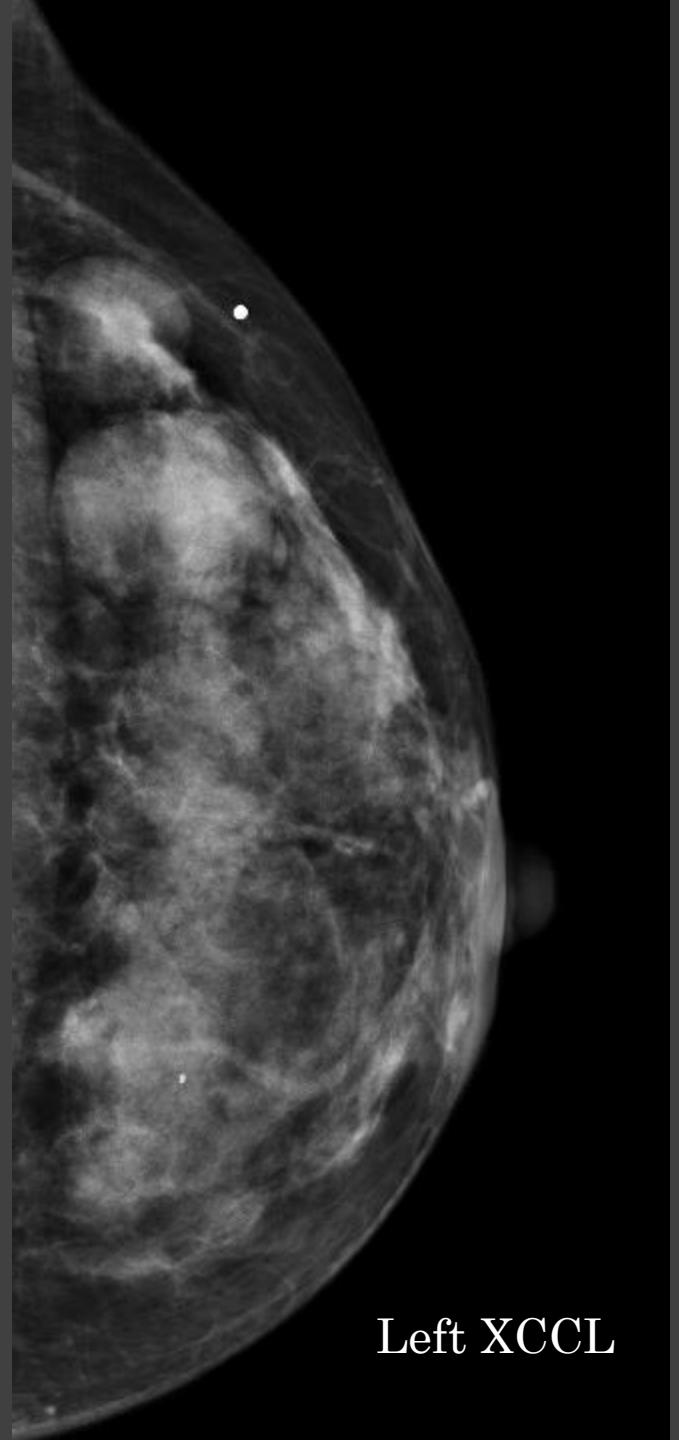

Case 7
CHALLENGE

On both MLO and CC:

- Locate the lesions (3).
- Locate the nipple.
- Are lesions above or below the nipple?
- Determine quadrant.

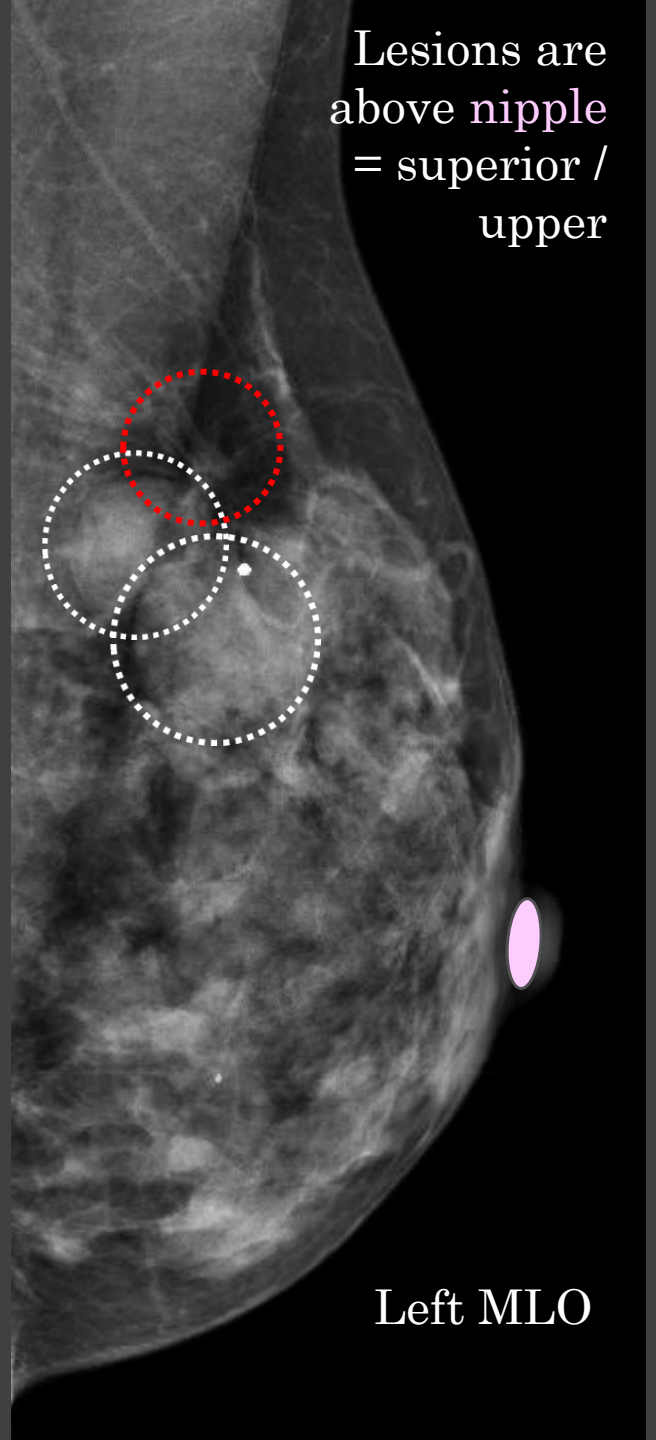

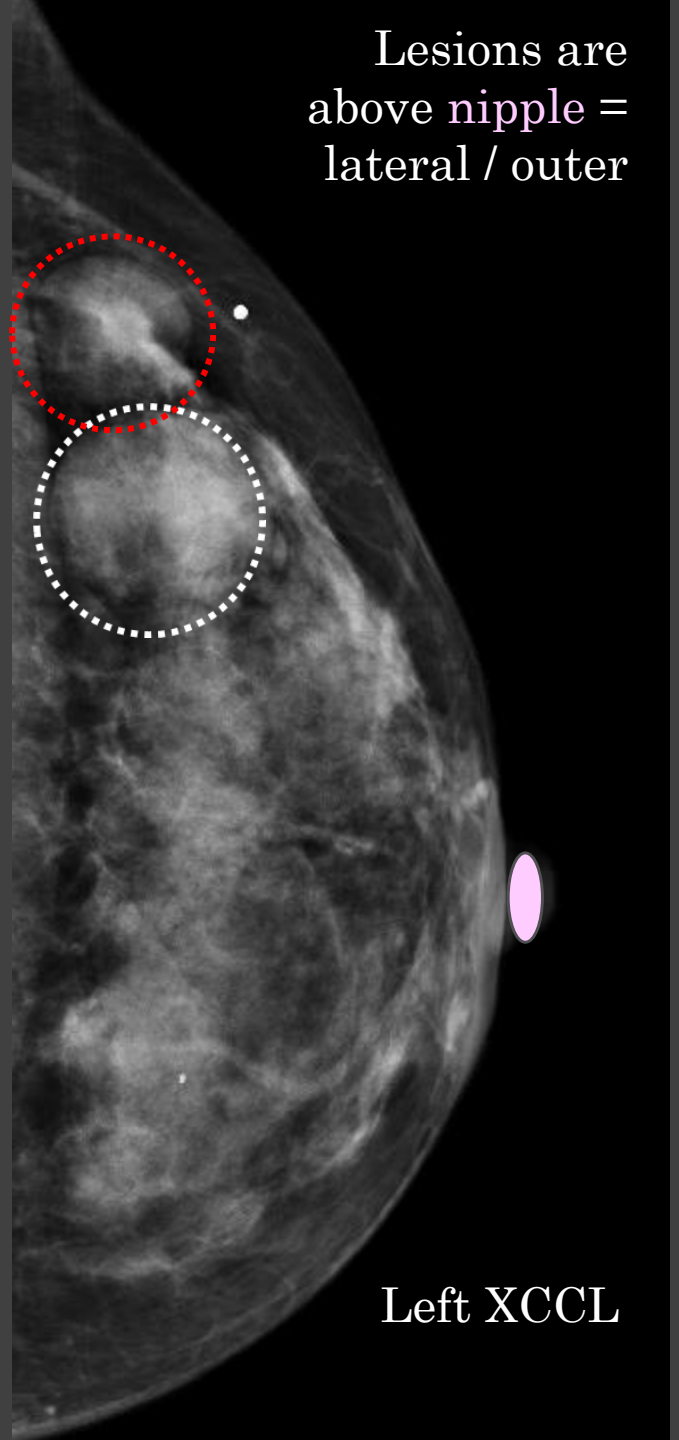

Case 7

Upper Outer

Two adjacent circumscribed masses

Ultrasound revealed those to be:

- Simple cyst
- Fibroadenoma

Spiculated Mass

- Breast Cancer

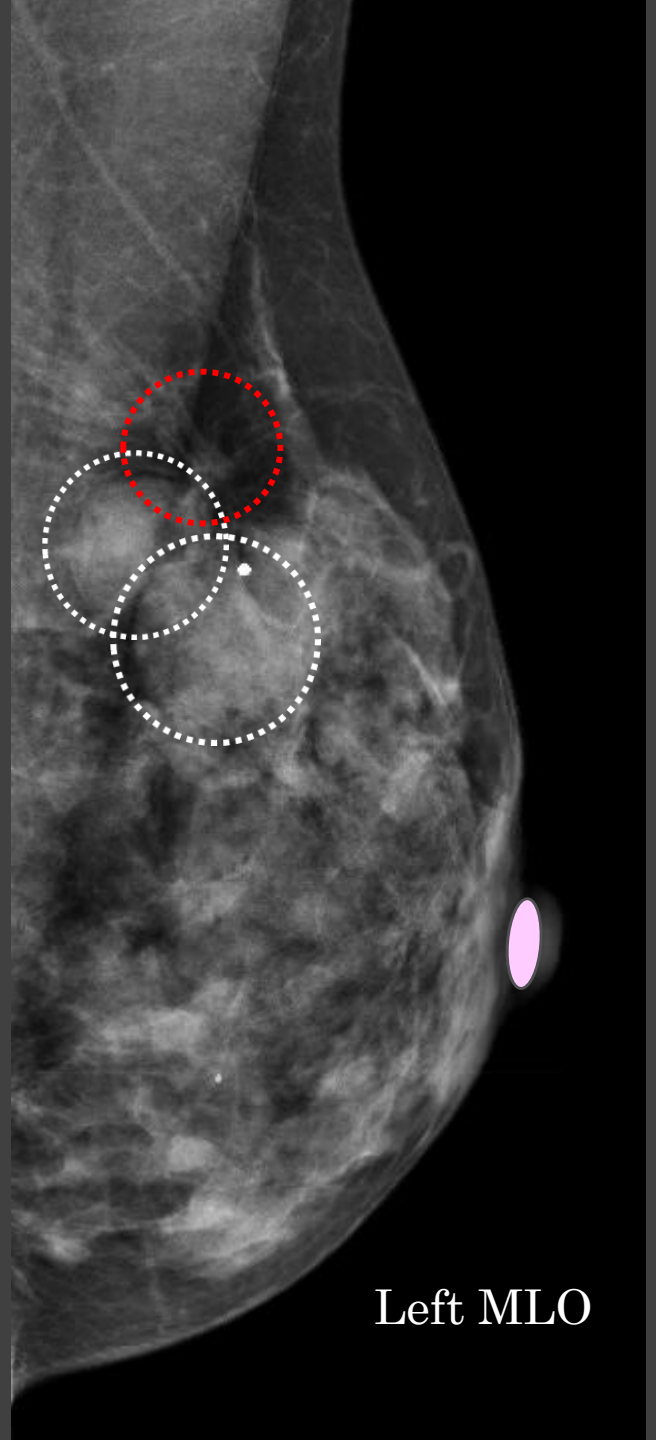

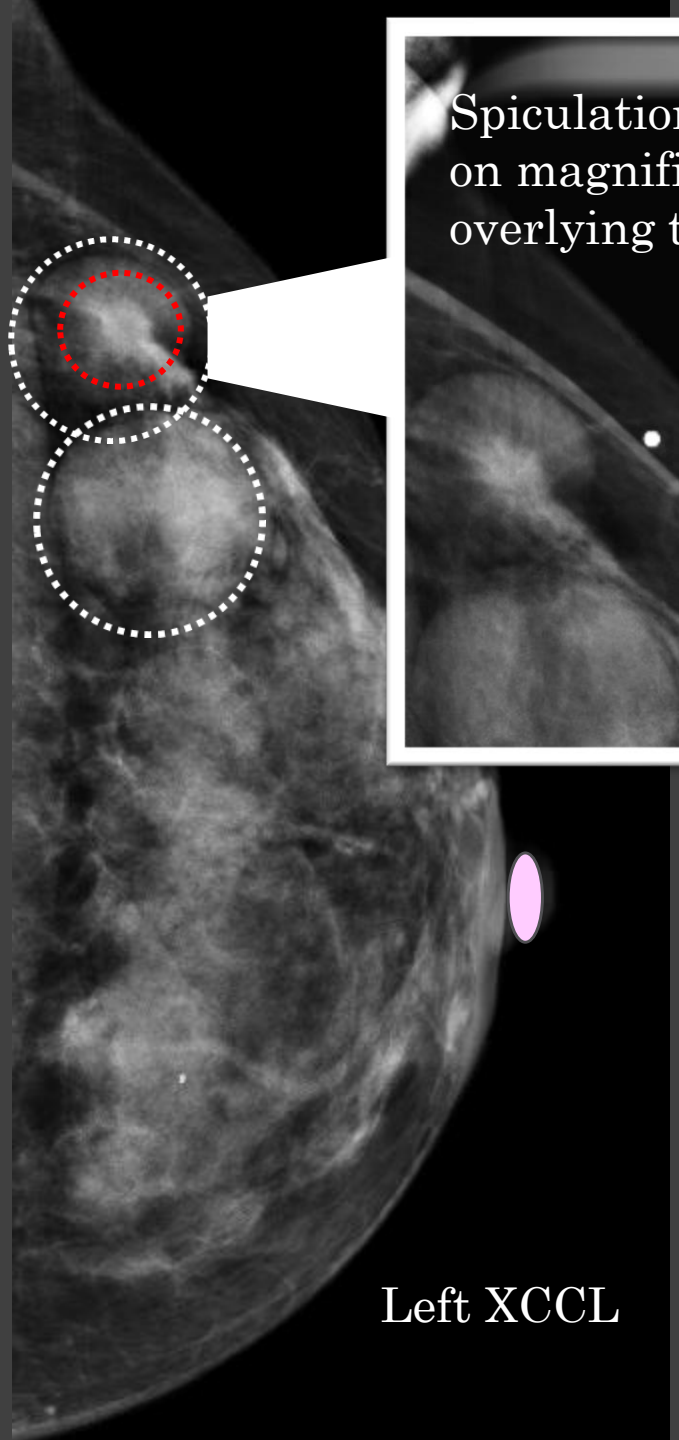

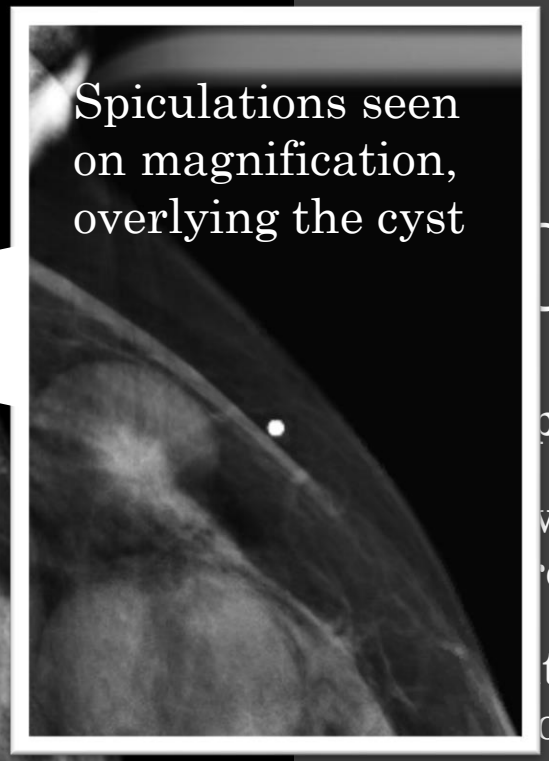

Case 7

pper Outer (all 3)

vo adjacent
rcumscribed masses

trasound revealed
ose to be:

- Simple cyst
- Fibroadenoma

Spiculated Mass

- Breast Cancer

In summary

- Recognize MLO versus CC projections
- Understand that MLO projections discern superior (upper) versus inferior (lower)
- Understand that CC projections discern lateral (outer) versus medial (inner)
- The four quadrants are used in mammography; clockface in sonography
- Understand the clockface is mirror image for lateral (outer) and medial (inner) (i.e. 3:00 on left is 9:00 on right, 2:00 on left is 10:00 on right, and so forth)

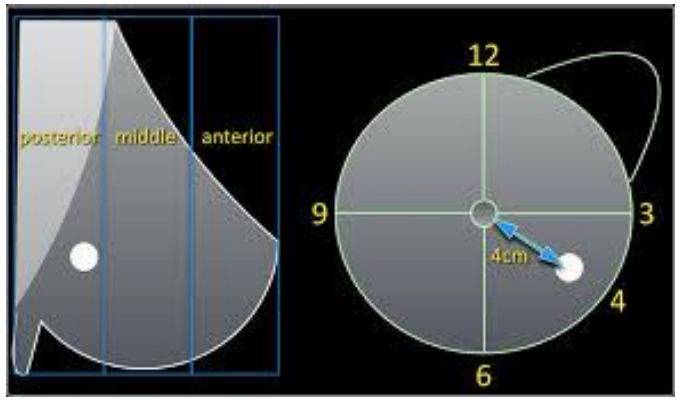

Final Exercise

- Label the MLO and CC views
- Label the quadrants on the clock

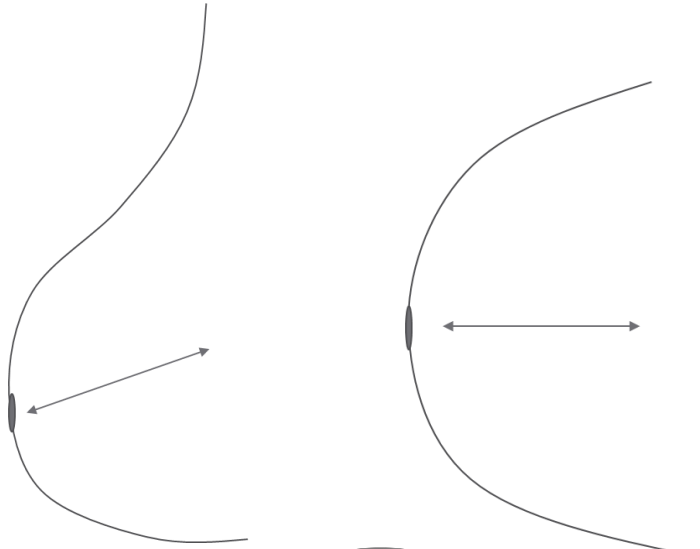

Right

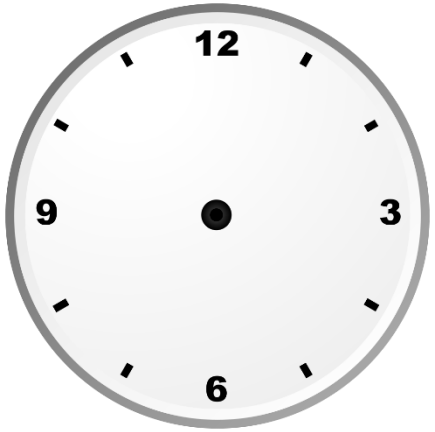

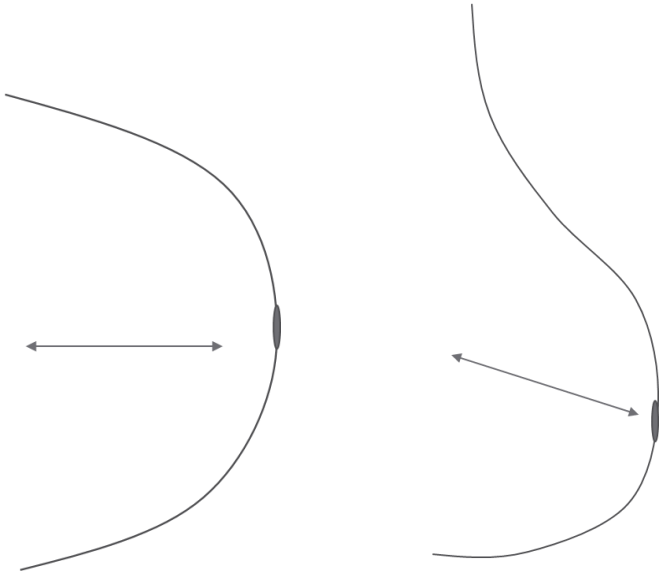

Left

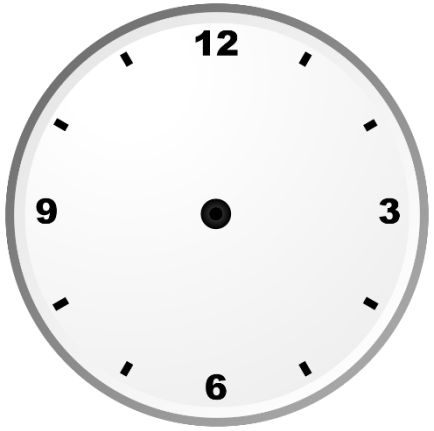

Final Exercise

- Label the MLO and CC views
- Label the quadrants on the clock

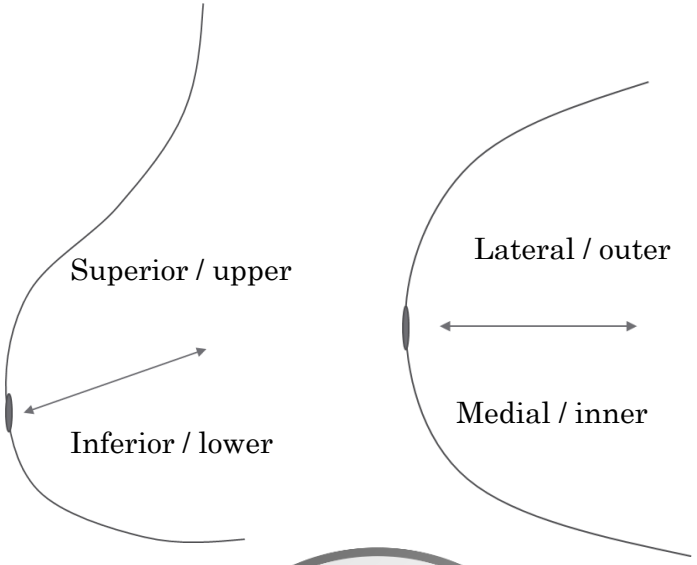

Right

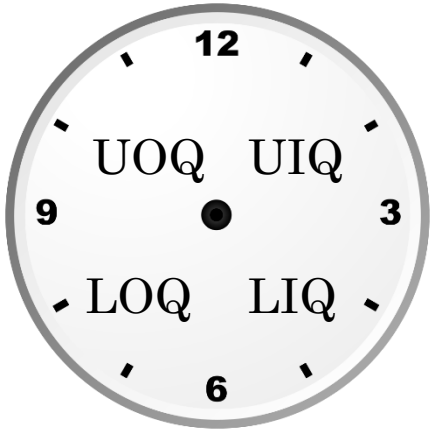

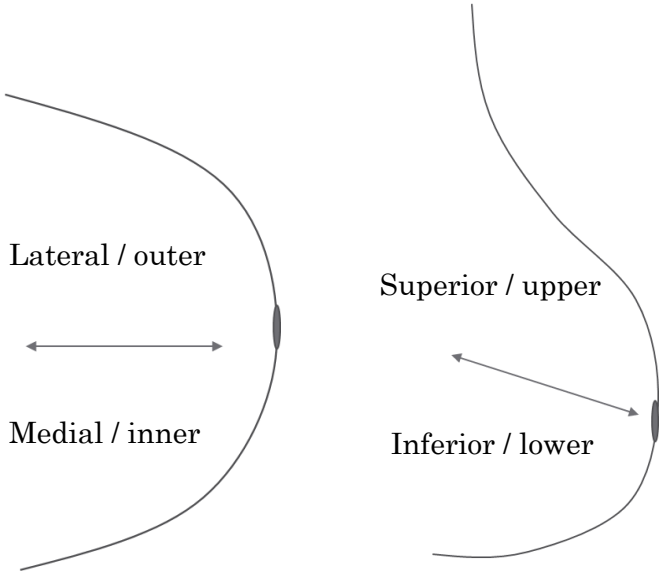

Left