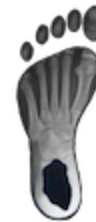


Introduction to Nuclear Medicine



Objectives

- What is nuclear medicine?
- Pros and cons
- Safety
- Indications
- A few sample types of studies





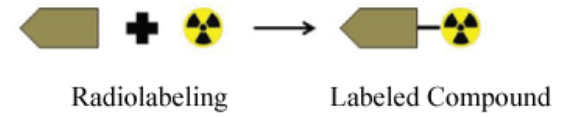
Radiolabeling

Labeled Compound

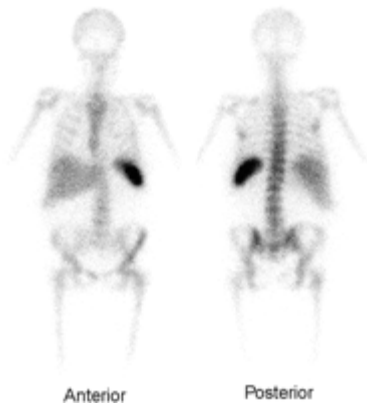What is nuclear medicine?

- Nuclear medicine uses **radionuclides** (unstable forms of elements whose atomic nuclei decay and emit gamma radiation that we can detect with gamma cameras) for diagnosis and treatment of disease
- We can use the radionuclides in certain drugs to create **radiopharmaceuticals**
- When radiopharmaceuticals are administered to patients, they accumulate in different organs or tissues
 - Thus, HIDA (a lidocaine analog) stuck to technetium will accumulate in the bile like lidocaine would and take a picture of the bile.
 - Radioactive iodine will go to the thyroid like normal iodine and show us what parts of the body are taking up iodine.
 - FDG (a glucose analog) will be taken up like normal glucose and show us what parts of the body have heavy anaerobic metabolism

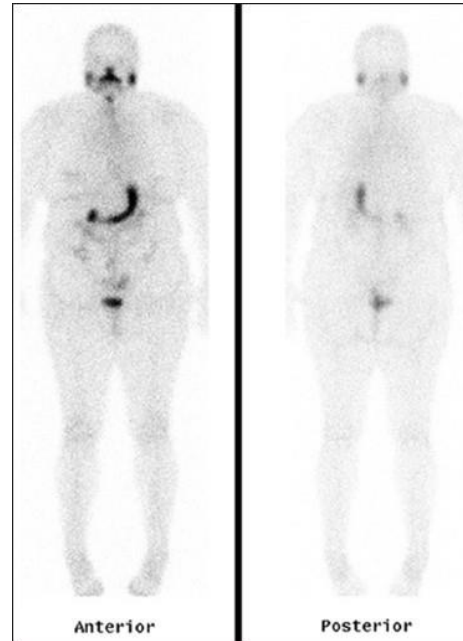




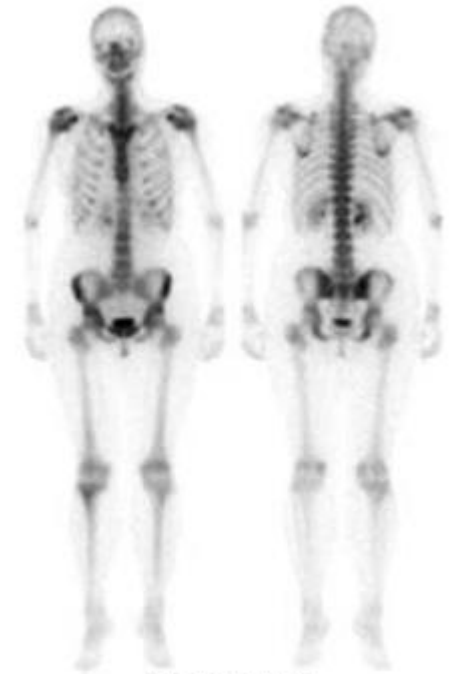Some radionuclide scans



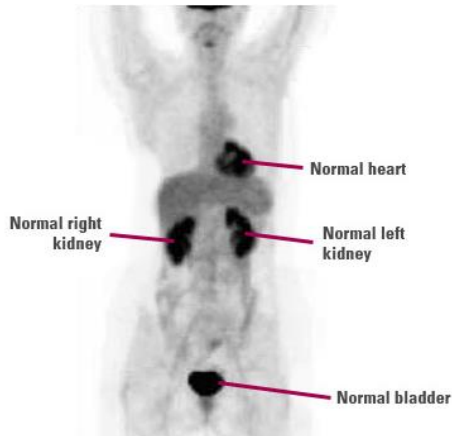
In-111 labeled WBCs



Whole body iodine scan (post-thyroidectomy)



Tc-99m MDP



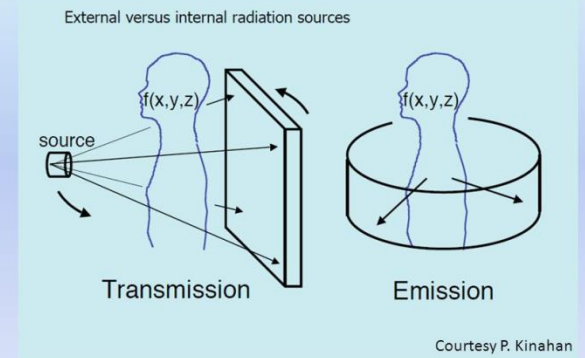
FDG-PET



What is nuclear medicine?

- In radiographs and CT, X-rays are transmitted *through* the patient's body.
- In nuclear medicine, gamma rays (from the radiopharmaceutical, presumably localized by physiology) are emitted *from* the patient's body
 - They are then detected by a gamma camera or PET scanner

Emission versus transmission imaging





Nuclear medicine basics: pros

- Examine physiology
 - Sometimes allows us to answer questions not answered by other imaging modalities
 - Possibility of molecular targeting/precision medicine (we can see if a tumor has somatostatin receptors, for instance)
- Take as many images as we want after injection
 - Since the dose is administered at the time of injection, we can get as many extra pictures as we want without additional radiation.





Nuclear medicine basics: pros

- Concentrations are low, so safe for patients in renal or hepatic failure
- Less affected by obesity (gamma rays are very penetrating)

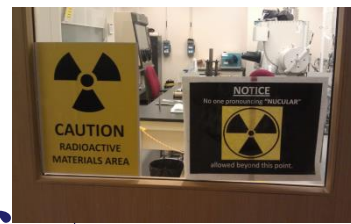



Nuclear medicine basics: cons

- Relatively high radiation dose—CT or more
 - The patient keeps getting radiated by the radiopharmaceutical until it gets excreted, so we have to give relatively little to start with
- Low spatial resolution ('unclear medicine')
- Variations in biodistribution for reasons other than disease
 - As a result, often extensive preparation (some exams may require the patient to be NPO, others to be off certain medications)





Nuclear medicine basics: safety

- Radiopharmaceuticals are at nanomolar (subpharmacologic) concentrations, so we can give pharmacologically active drugs
 - Ioflupane (DaT Scan) is a cocaine analog on Schedule II
 - HIDA is a lidocaine analog
 - Thallium is poisonous at higher concentrations
- Reasonably high radiation dosage (similar to CTs)



Nuclear medicine basics: terminology

- Much of the confusion from a new field can arise from the unfamiliar terminology
- Terms:
 - Increased uptake
 - Normal uptake
 - Decreased/absent uptake or photopenic (there is no antonym)
- Compare: increased or decreased opacity (radiograph), attenuation (CT), intensity (MR), echogenicity (US)



Nuclear medicine basics: indications

- Note that the nuclear exam typically answers one question
- A V/Q scan will rule out pulmonary embolism, but will not distinguish among pneumonia, pleural effusion, and malignancy.
- A HIDA scan will rule out cholecystitis, but will not distinguish kidney stones, appendicitis, and diverticulitis.



Nuclear medicine basics: indications

- By far most common nuclear scan is **PET scan with FDG**
 - This is mostly used for cancer staging
 - Exploits dedifferentiated tumors' heavy anaerobic metabolism and consequent glucose utilization
 - Also has applications in cardiology (viability), neurology (finding seizure foci), and infectious diseases (finding sites of occult infection)



Nuclear medicine scan: indications (by organ system)

- CNS—dementia, tumors, epilepsy
- Endocrine—thyroid, parathyroid, neuroendocrine tumors
- Cardiovascular—coronary artery disease
- Pulmonary—pulmonary emboli
- GI—delayed emptying, GI bleed, cholecystitis, others
- MSK—bone metastases, osteomyelitis, prosthetic joint infections
- Oncology—various (FDG—generic, MIBG, DOTATATE—neuroendocrine tumors, FACBC—prostate, NaF/bone scan—bone mets)



Nuclear medicine basics: indications (most common at UNC)

- Oncologic staging and restaging (FDG-PET)
- Coronary artery disease (myocardial perfusion imaging)
- Skeletal metastases, prostate and breast cancer (bone scan)
- Gastric dysfunction (gastric emptying study)
- Urinary tract obstruction (Lasix/MAG3 study)
- Pulmonary embolism (V/Q study)
- Sentinel node staging (Lymphoscintigraphy)
- Cholecystitis (HIDA scan)
- Hyperthyroidism and thyroid nodules (thyroid scan)
- Parathyroid adenoma (parathyroid scan)
- Calculation of GFR (DTPA)
- Therapy of hyperthyroidism or thyroid cancer (radioiodine treatment)
- Staging of thyroid cancer (whole-body iodine scintigraphy)
- Assessment of renal scarring (DMSA)

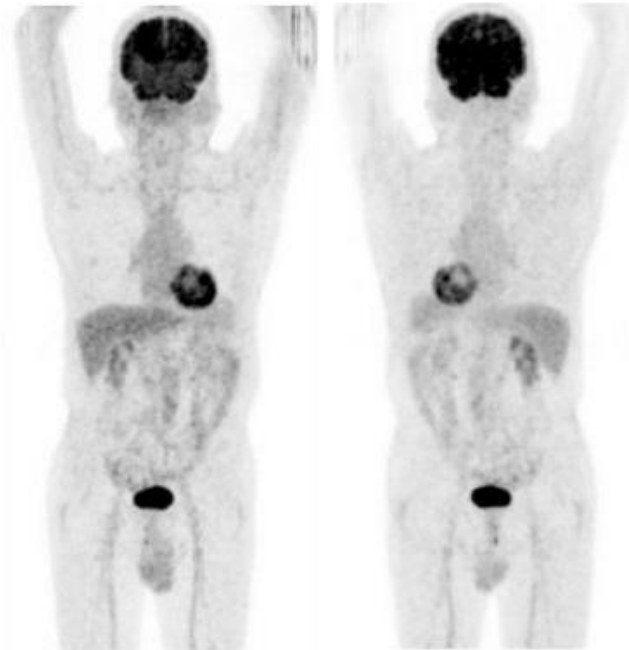


Oncology: FDG-PET

- When do we order the study?
 - Initial staging of a malignancy
 - Response to chemotherapy and/or radiation
 - Detection of recurrence
- What is the clinical question?
 - Is there cancer somewhere? If so, where is it?
- What are we studying? Anaerobic metabolism (and consequent glucose upake)



Normal FDG PET scan

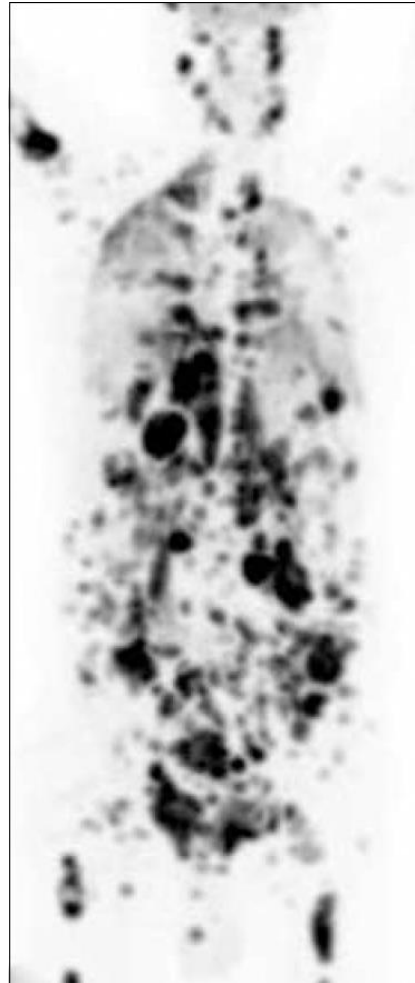


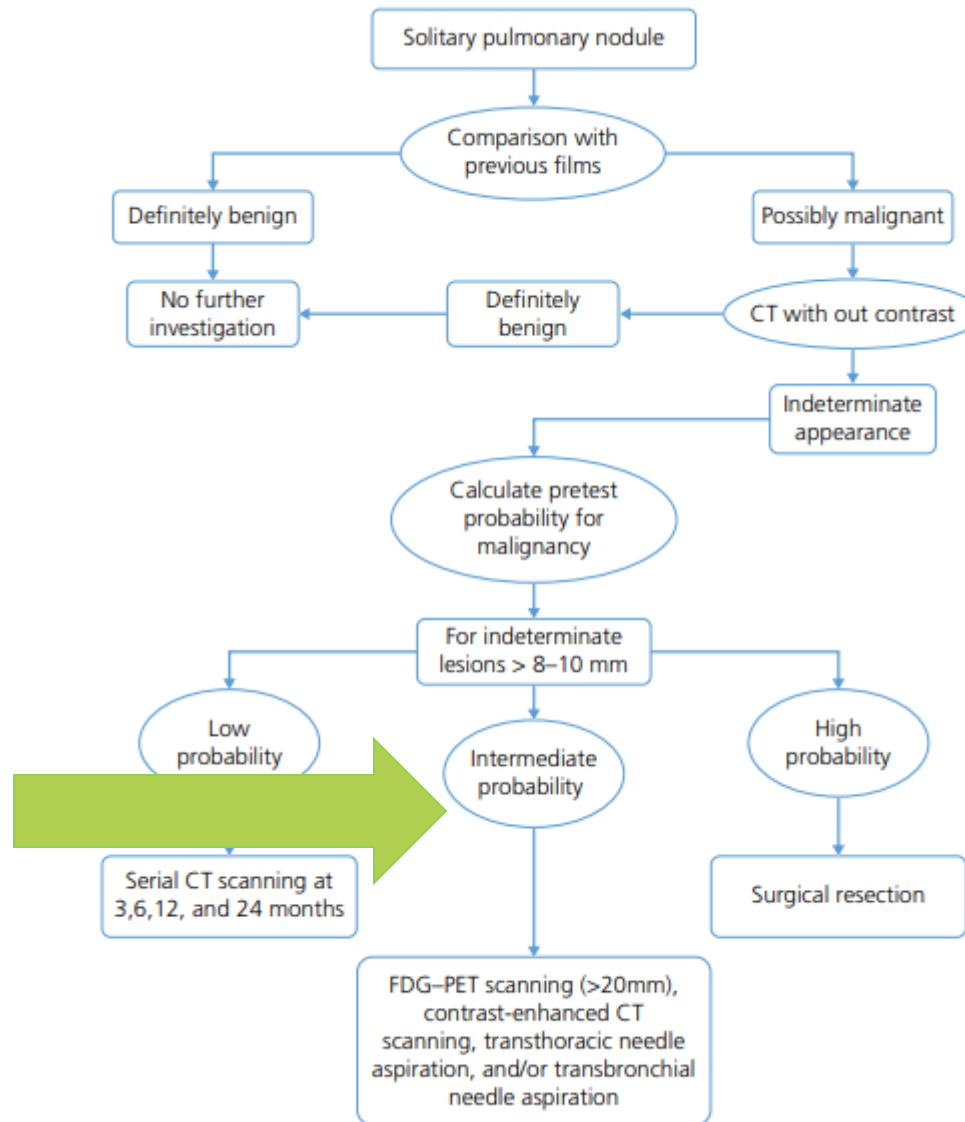
Anterior

Posterior



FDG PET for widespread lymphoma





CT, computed tomography; FDG-PET-fludeoxyglucose-positron emission tomography

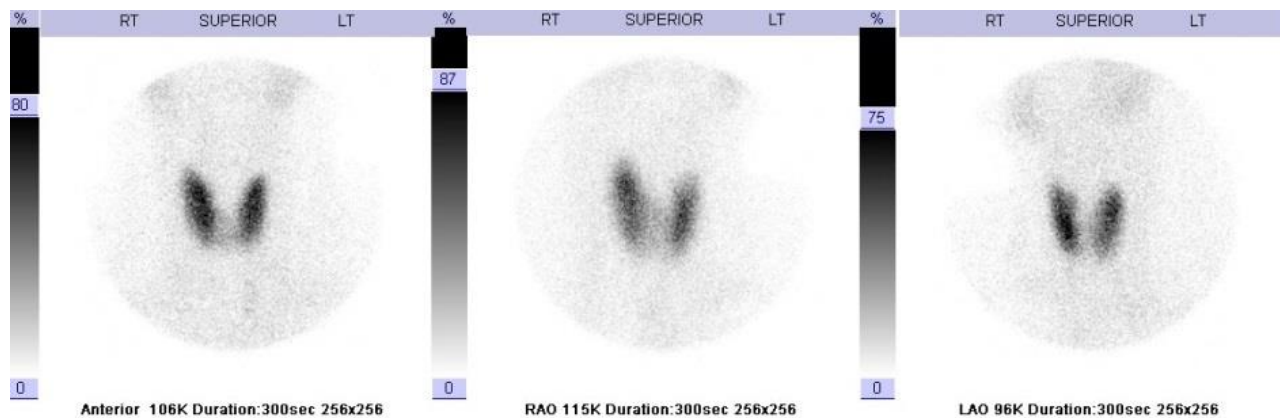
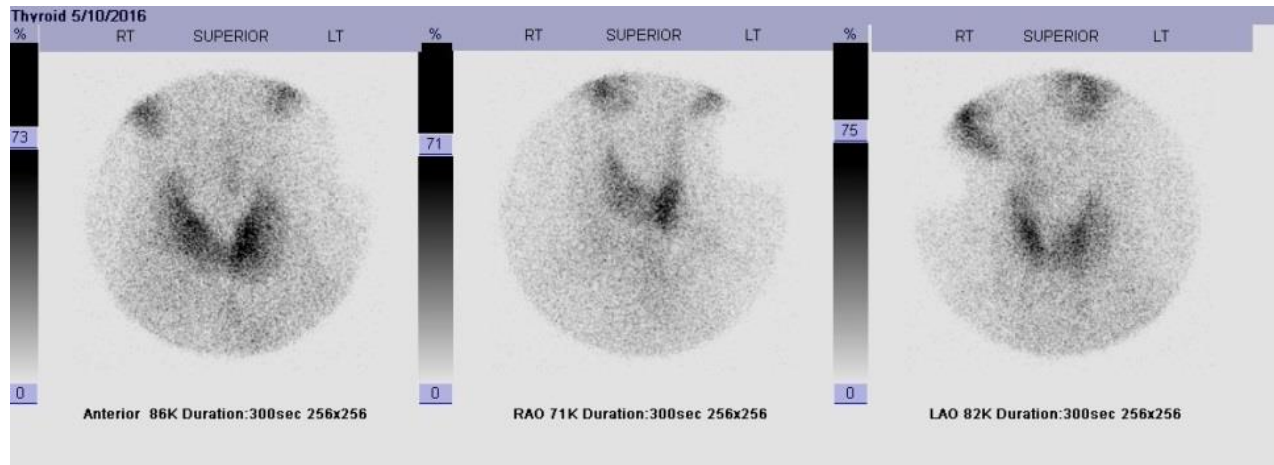


Endocrine: thyroid

- When do we order the study?
 - When the patient's hyperthyroid, especially if we're worried about a nodule
 - After thyroidectomy for cancer and we want to know if there's thyroid tissue left
- What is the clinical question?
 - Either: what is thyroid function (hyperthyroidism)?
 - If low, the patient likely has subacute thyroiditis (which resolves on its own); if high, it is likely Graves' disease or multinodular goiter (which can be treated with medications, surgery, or radioactive iodine)
 - Or: is there thyroid tissue, benign or malignant, left (thyroid cancer)?
 - If you start seeing thyroid tissue in the lymph nodes, lungs, or bones, you have a metastasis.
- What are we studying? Iodine uptake

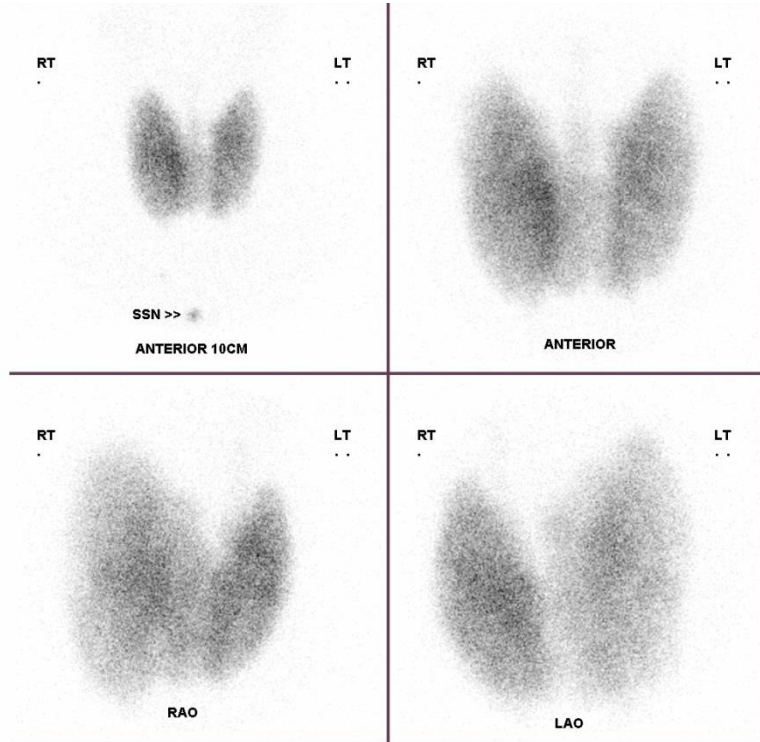


Normal thyroid studies (18%, 27% uptake)

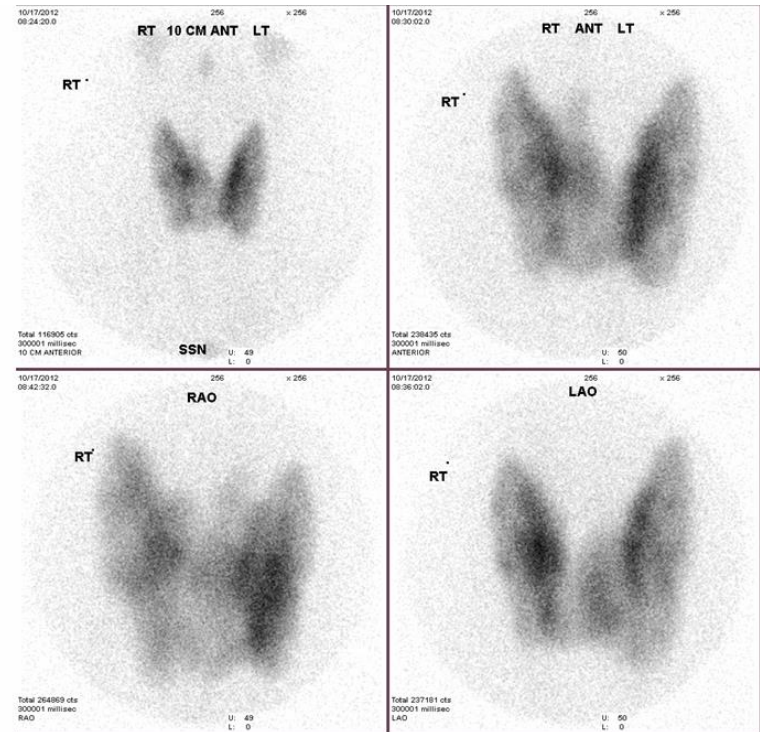


Hyperthyroidism

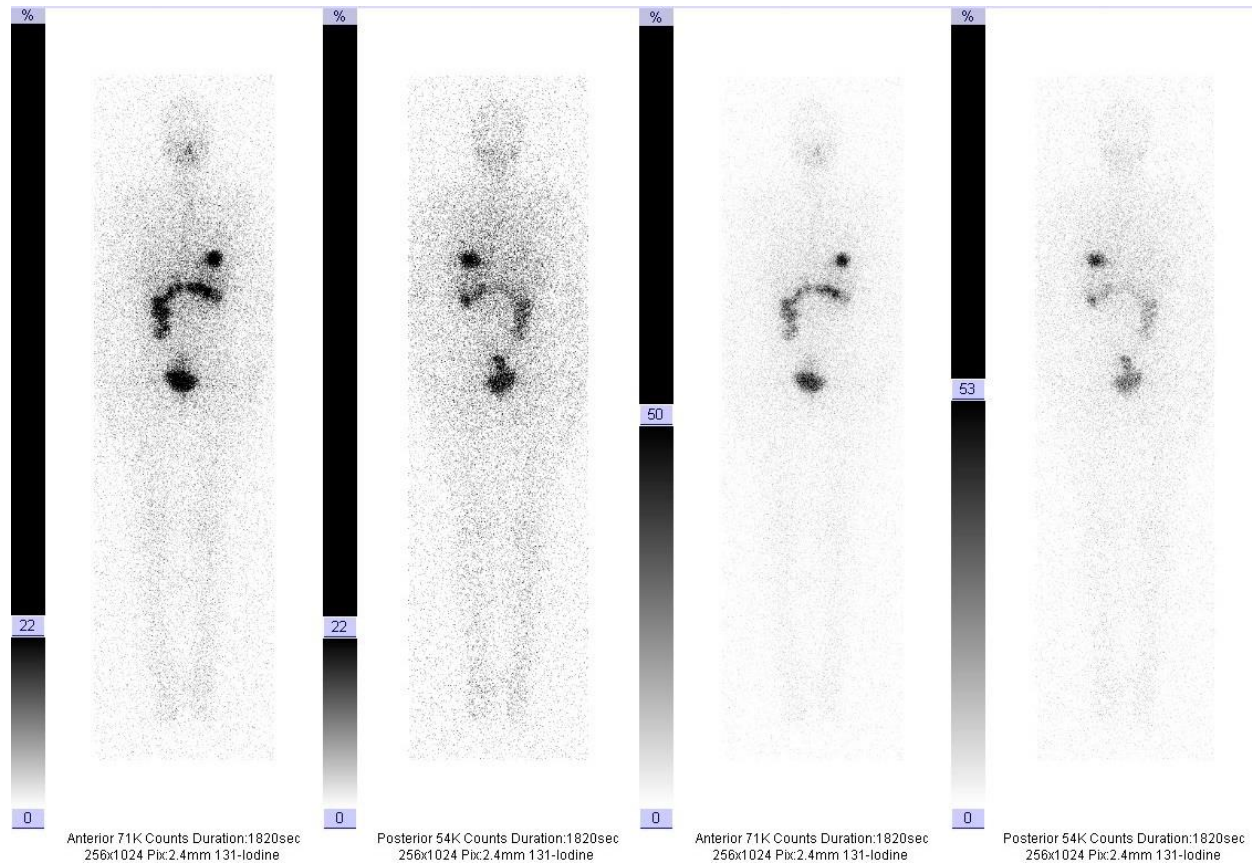
Graves




MNG



Whole-body iodine scan, negative

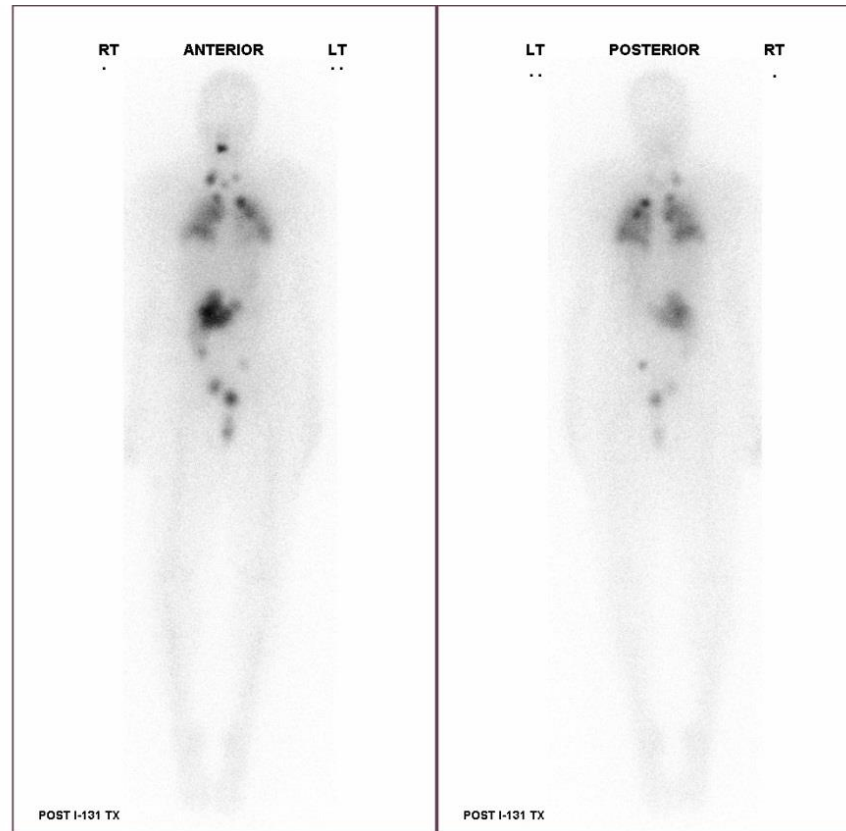


Whole-body iodine scan, residual tissue



Thyroid cancer

Pulmonary and nodal mets



Cardiac imaging

- **When do we order the study?** When we're worried about CAD
- **What is the clinical question?** Is there clinically significant coronary artery disease and, if so, is the affected tissue still alive?
- **What are we studying?** Perfusion (mostly) *at time of injection*
- **What's the name of the tracer?**
Tetrafosmin/sestamibi (SPECT), ammonia or rubidium (PET)

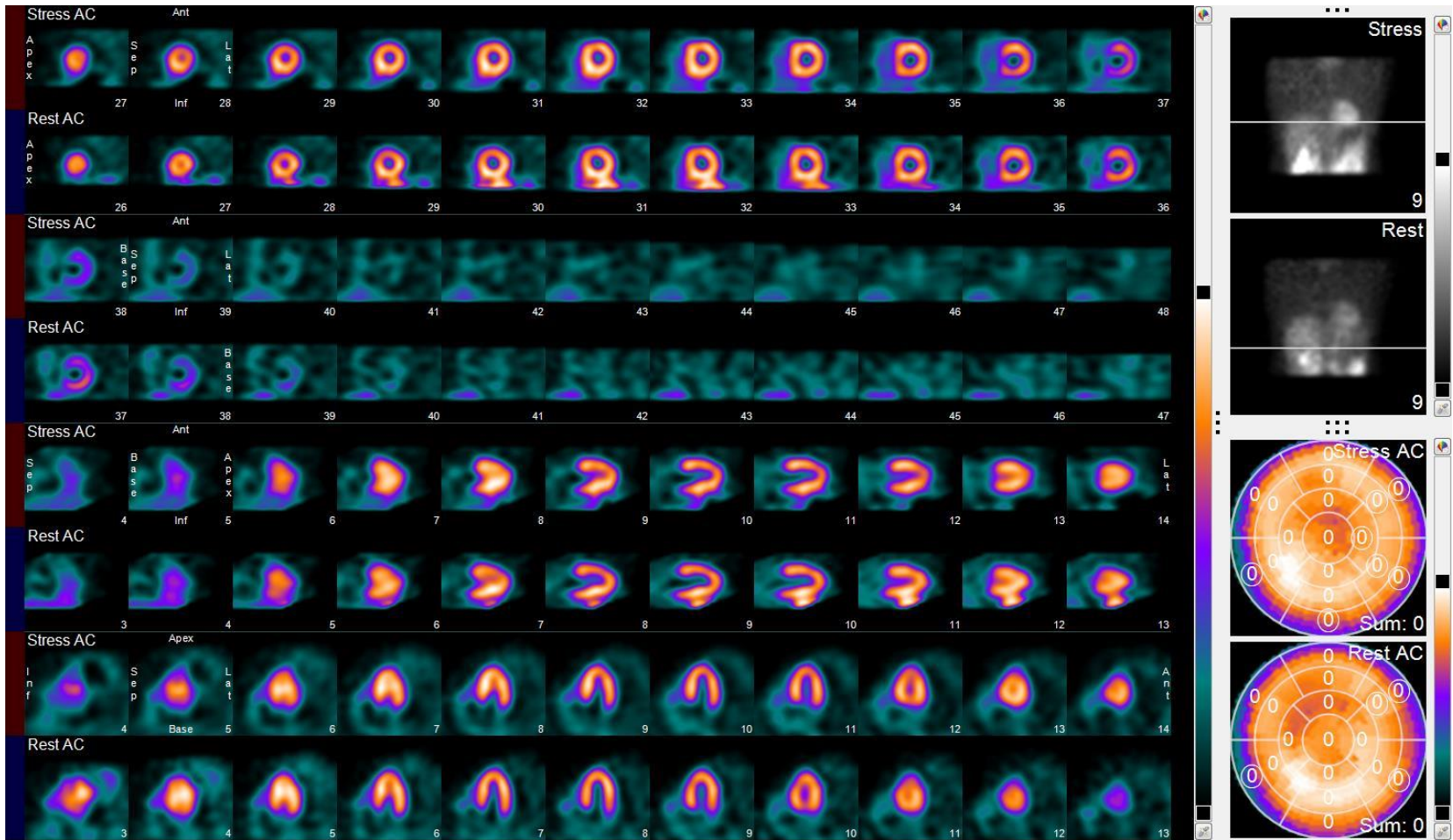


Stress and rest imaging

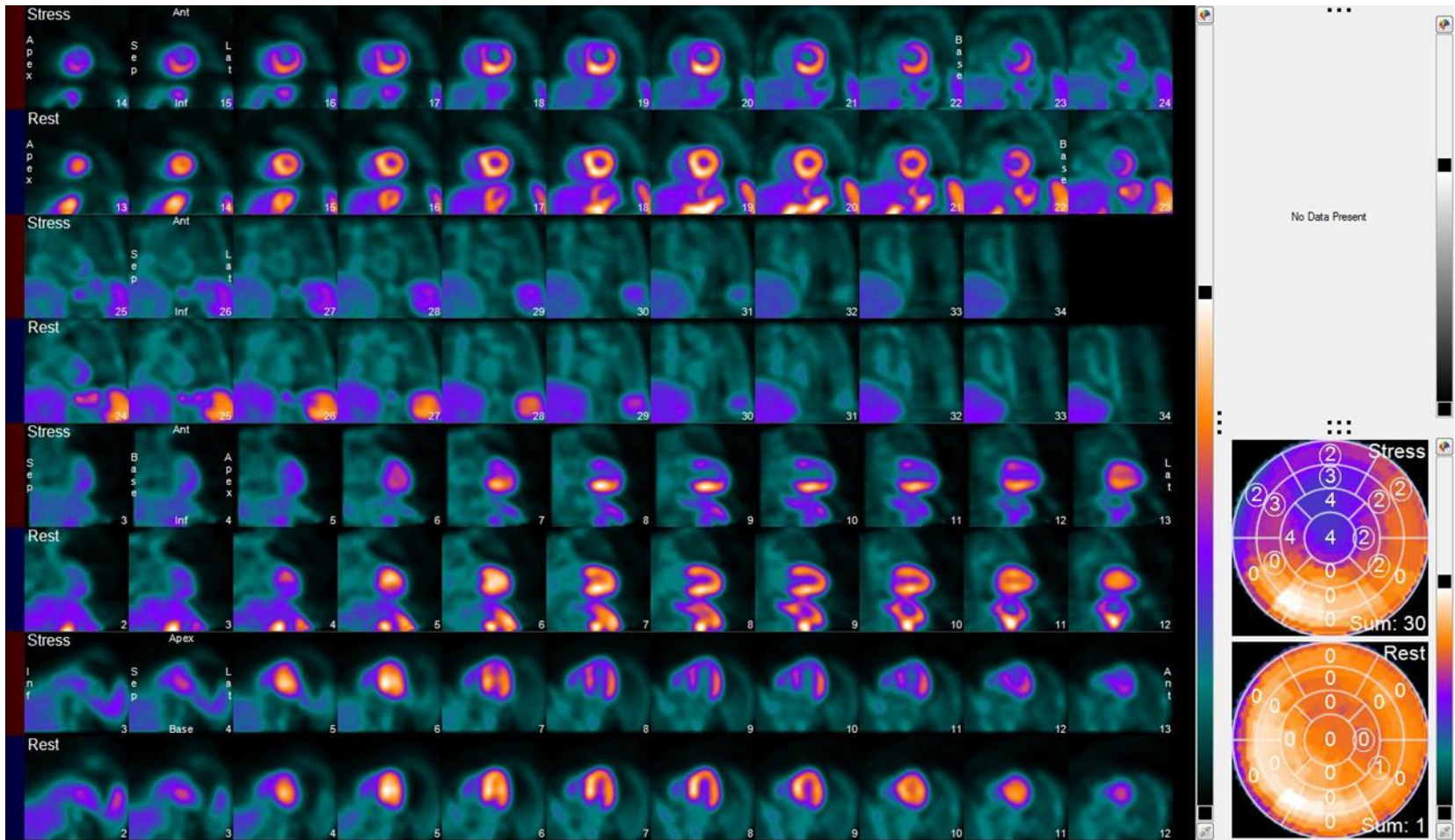
- To compare the two, we get stress and rest images
- There are a few ways to stress patients
 - We can use exercise or drugs
 - Drugs can be vasodilators or inotropes



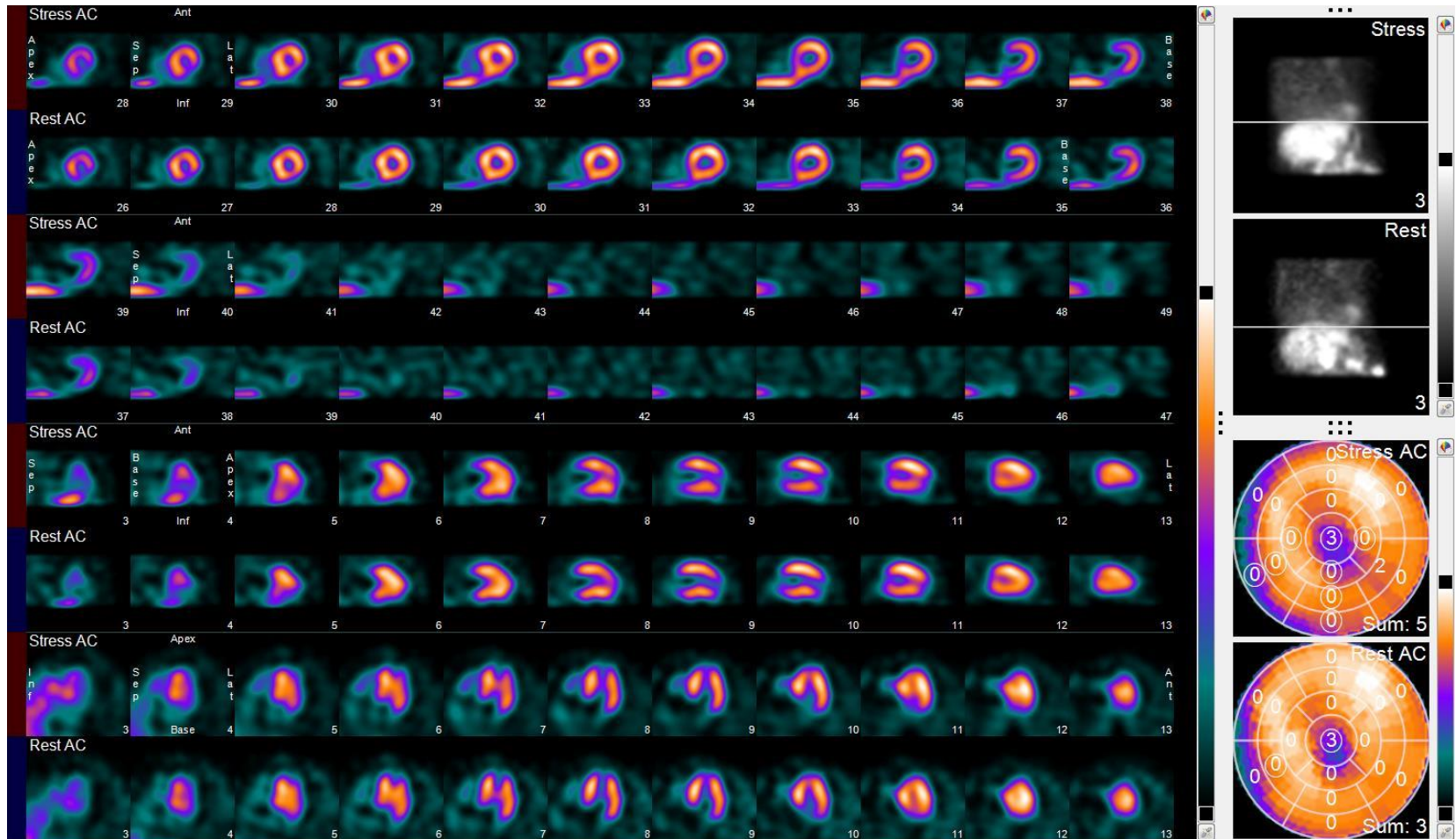
Normal



Ischemia



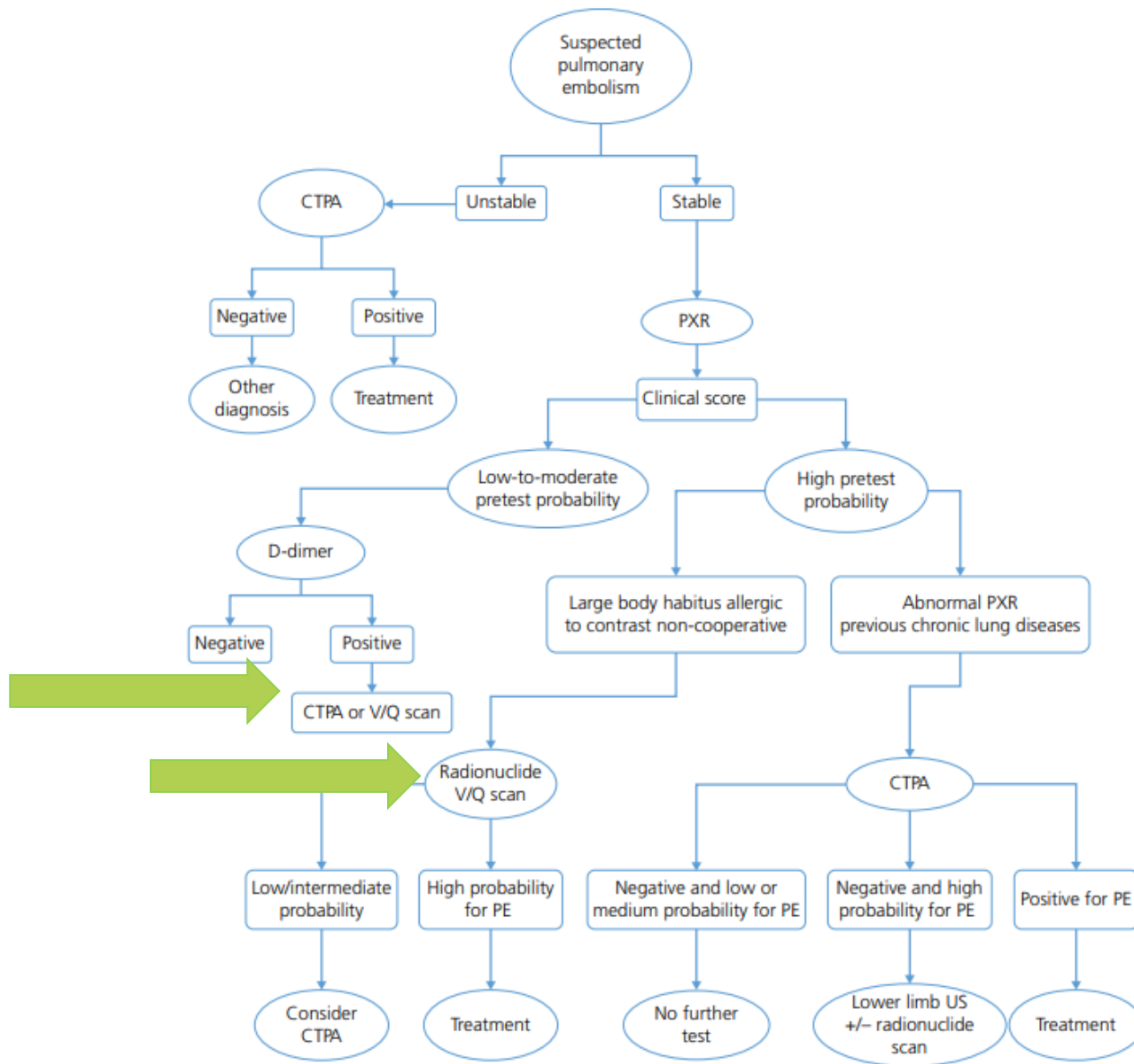
Infarct



V/Q scan

- **When do we order the study?** When we're worried about PE but don't want to get a CTPA
- **What is the clinical question?** Does the patient have a pulmonary embolism?
 - Lower-radiation than the other option, a CTPA; also used with contrast allergies and renal failure
 - The perfusion scan in particular is also used to assess relative lung perfusion before surgery
- **What are we studying?** Lung ventilation and perfusion
 - Alone among pulmonary pathologies, the PE damaged perfusion *but not* ventilation
- This test is interpreted together with a **chest X-ray**

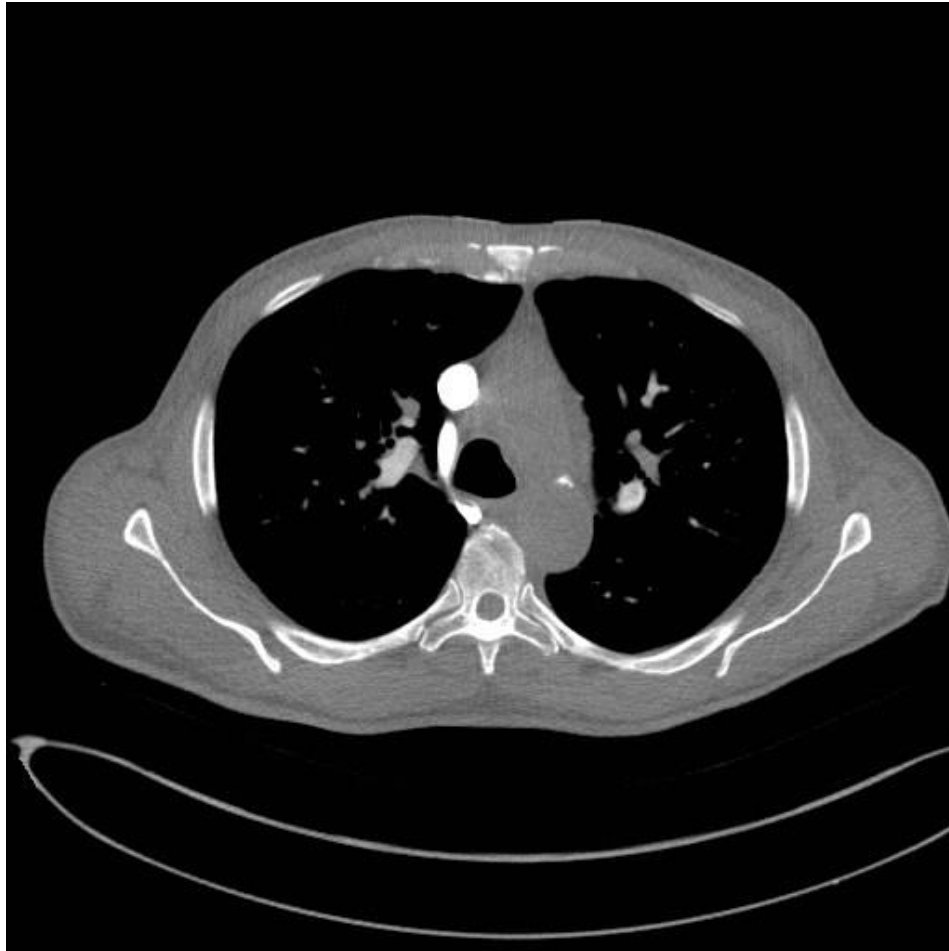



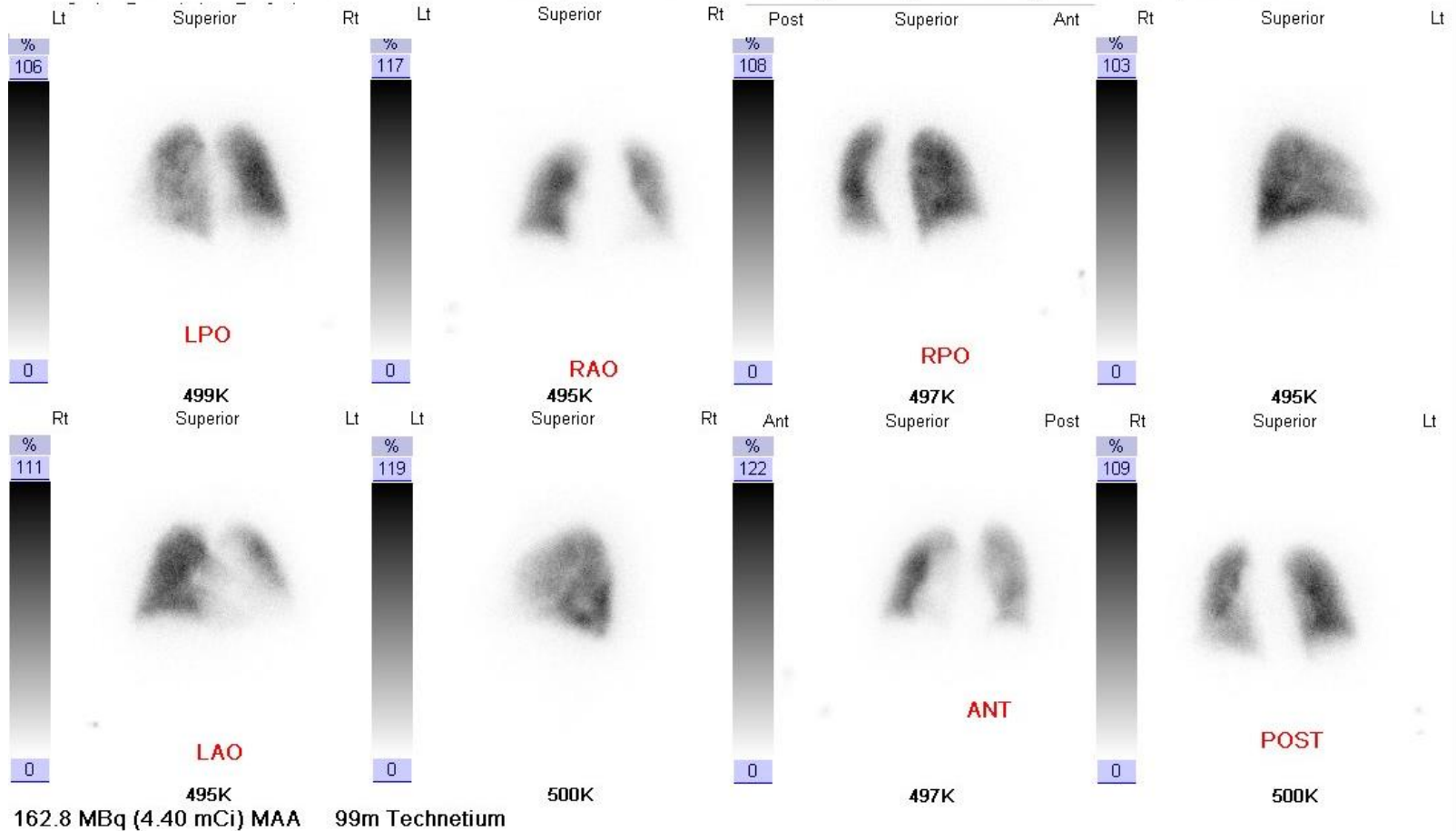
PXR, plain X-ray; CTPA, computed tomography pulmonary angiogram; V/Q scan, ventilation/perfusion scan; US, Ultrasonography.



What if the CTPA is nondiagnostic?




Normal perfusion



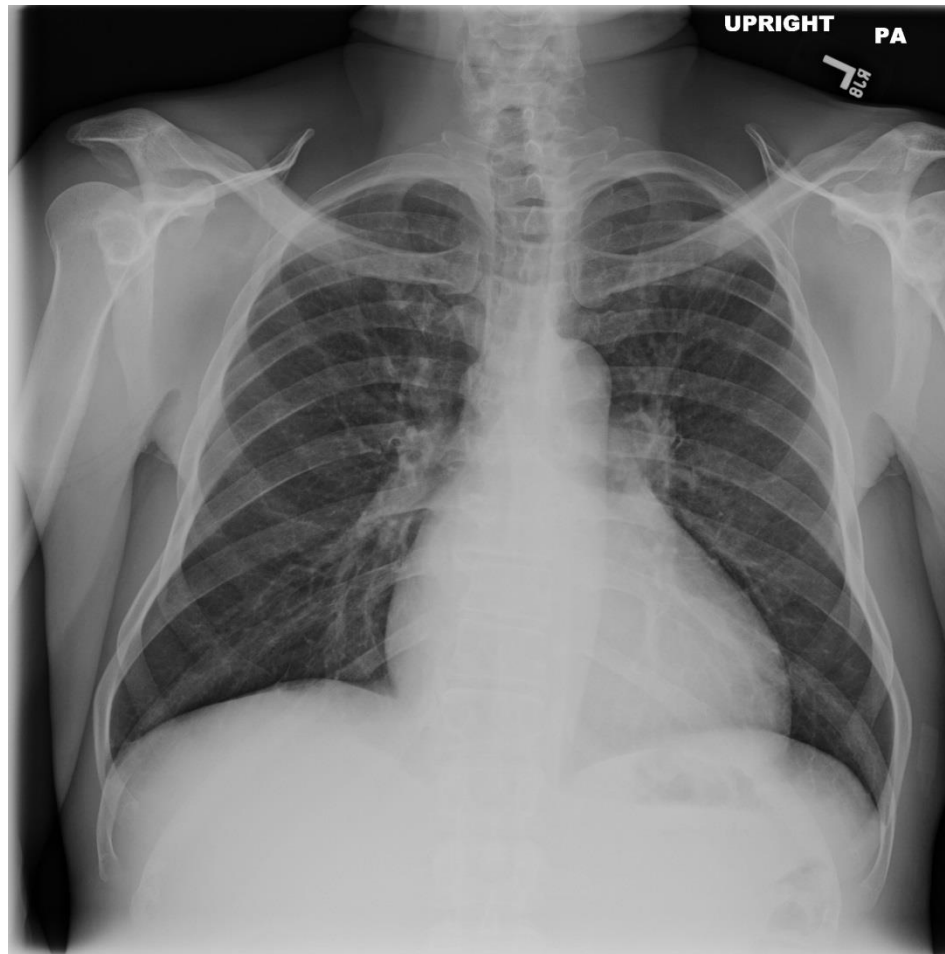
Normal ventilation

TIDet-2 Vent | 6/30/2016

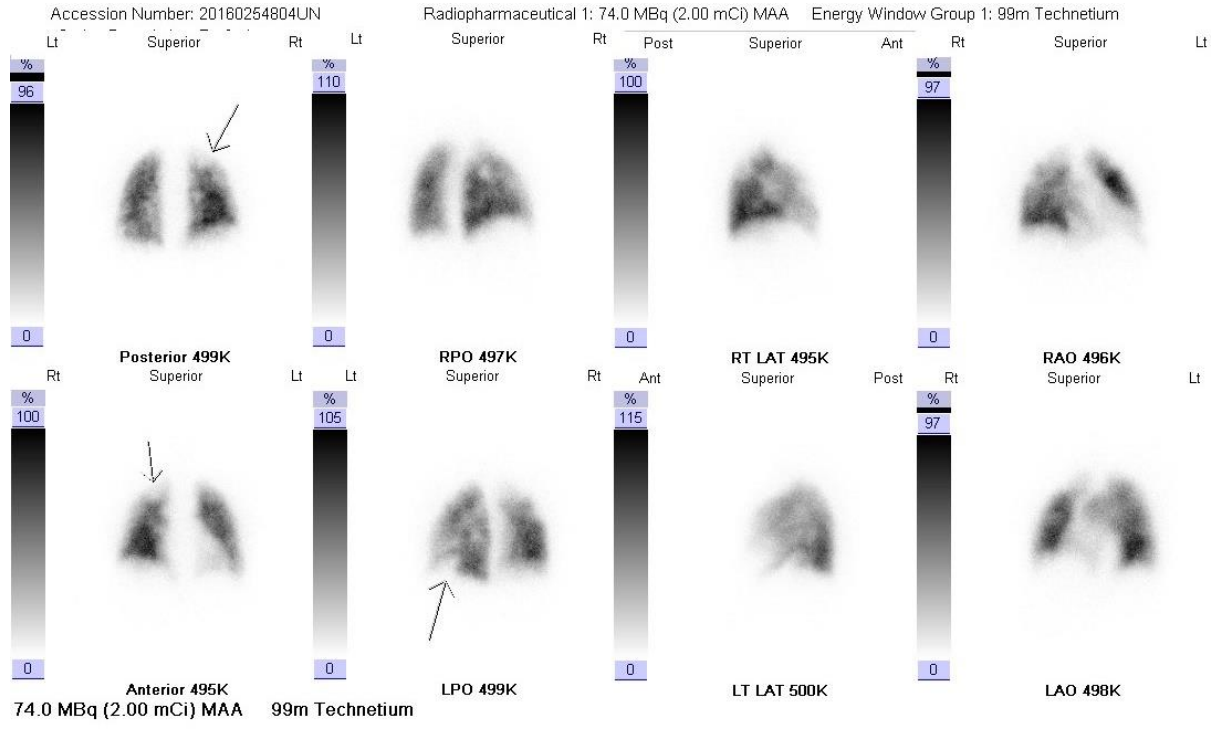
Lt Superior Rt



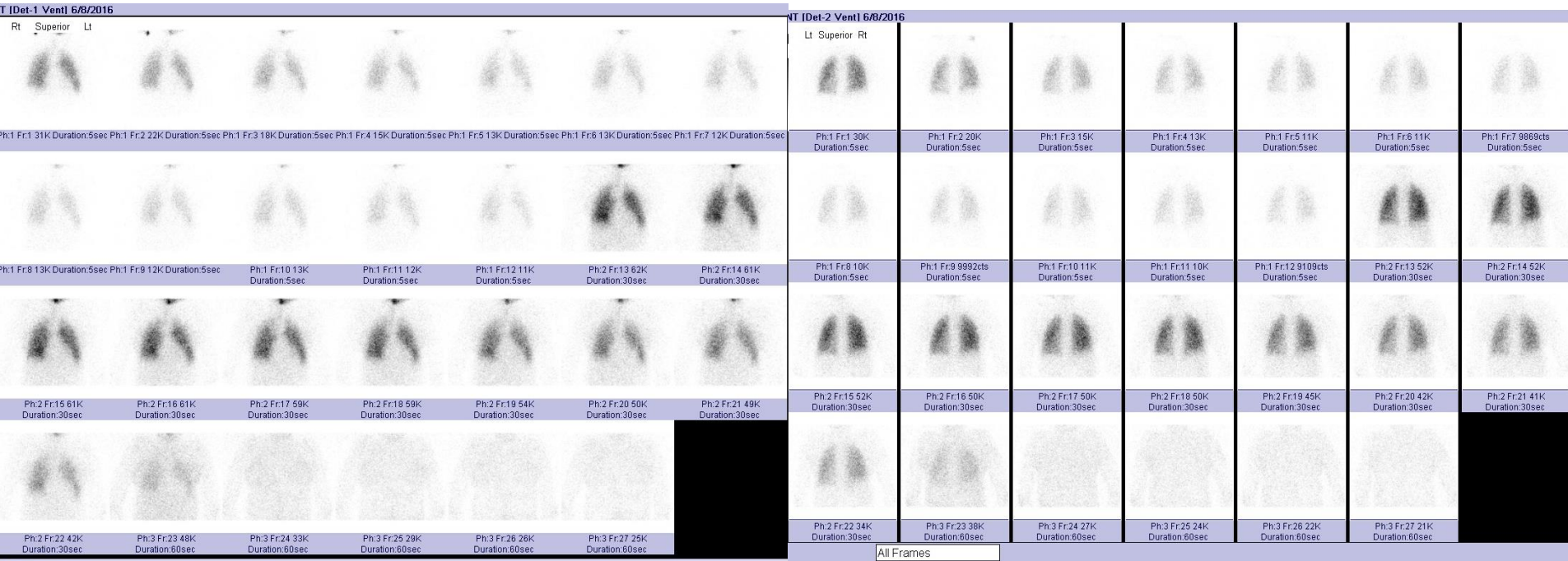Normal CXR



VQ: abnormal perfusion



VQ: normal ventilation

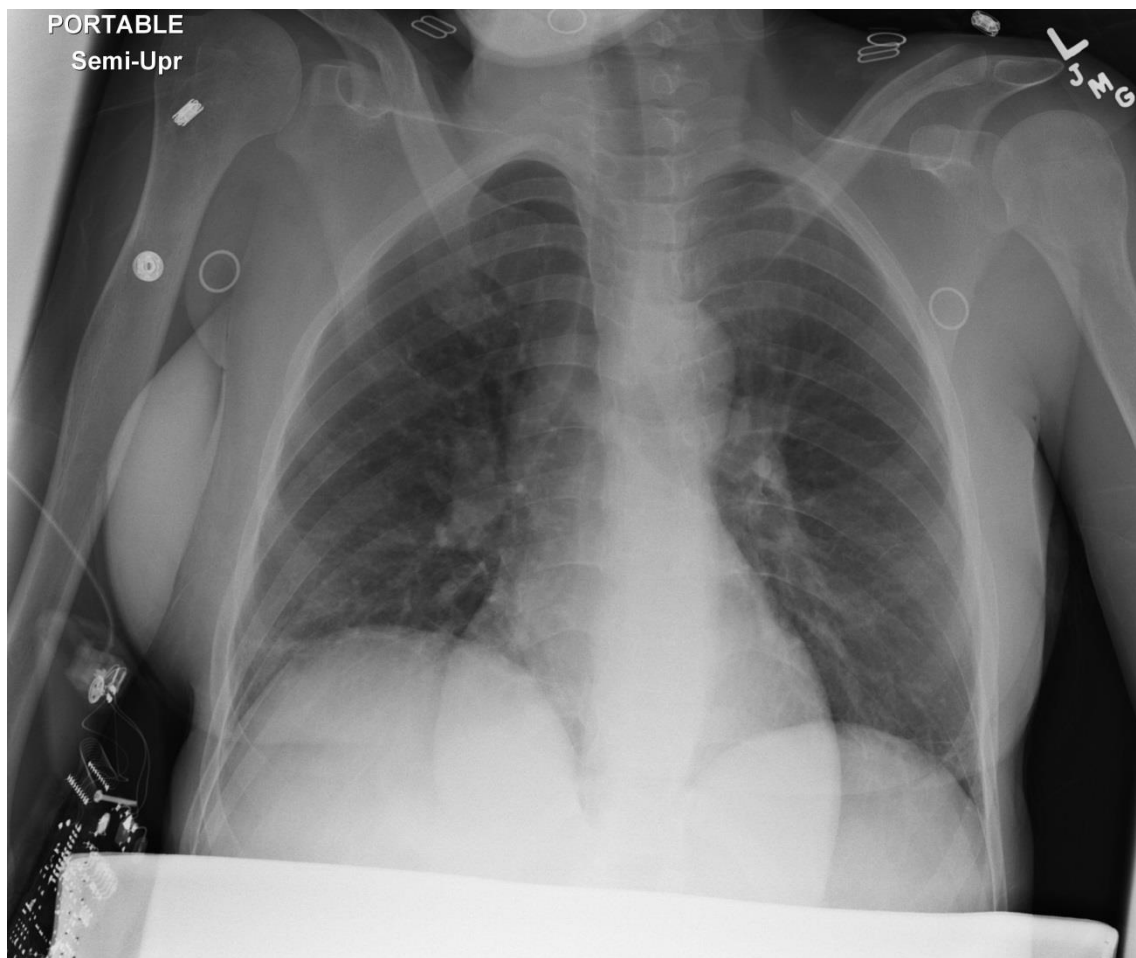


T:78%

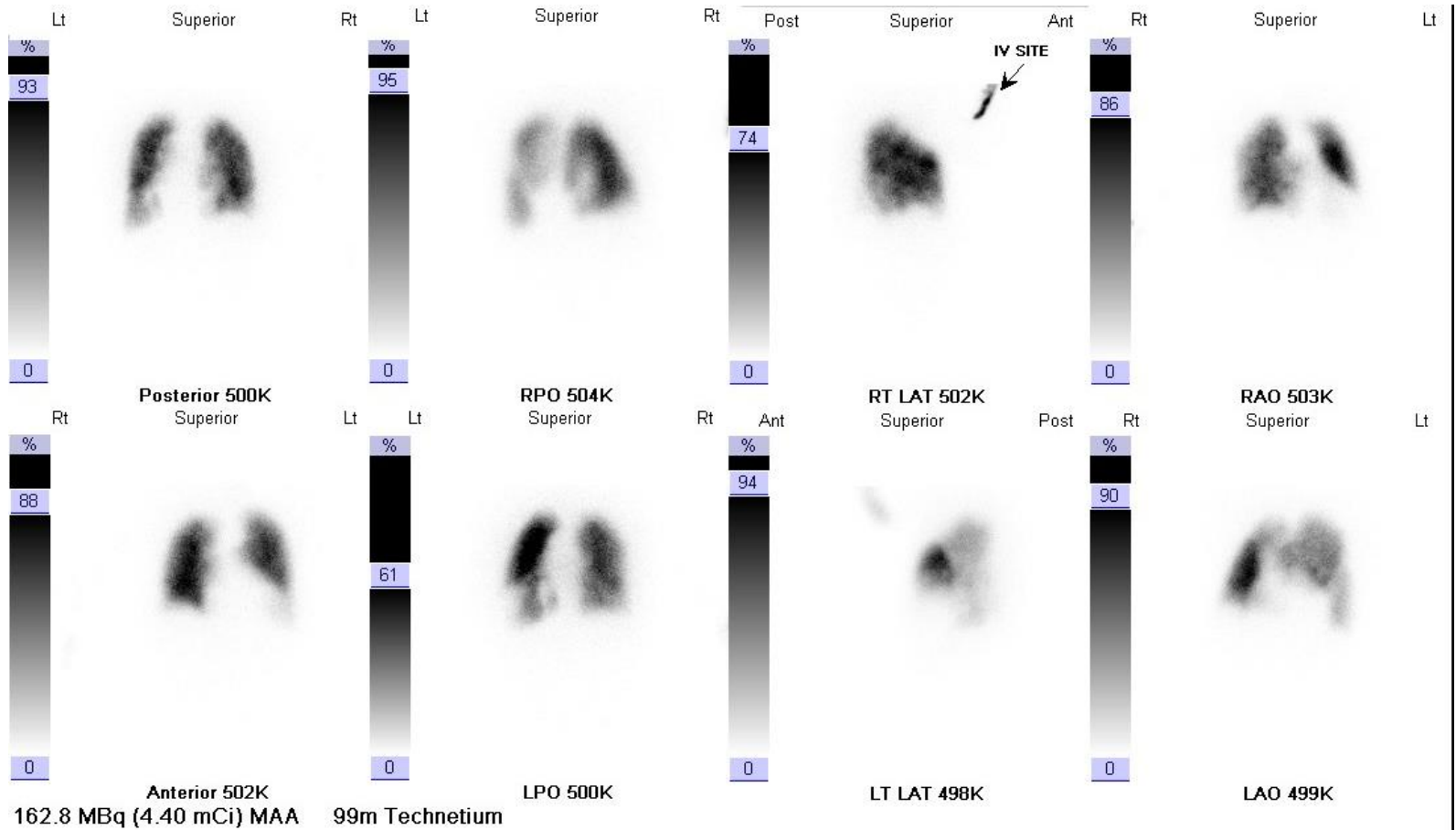
All Frames



Normal CXR



Perfusion defect: left lower lobe



Gastric emptying scan

- **When do we order the study?** When clinicians are worried about rapid or delayed gastric emptying (vomiting, nausea, abdominal pain, GI sx in DM)
- **What is the clinical question?** Is gastric emptying too slow, too fast, or just right?
- **What are we studying?** Movement of radiotracer (and thus presumably food) out of the stomach



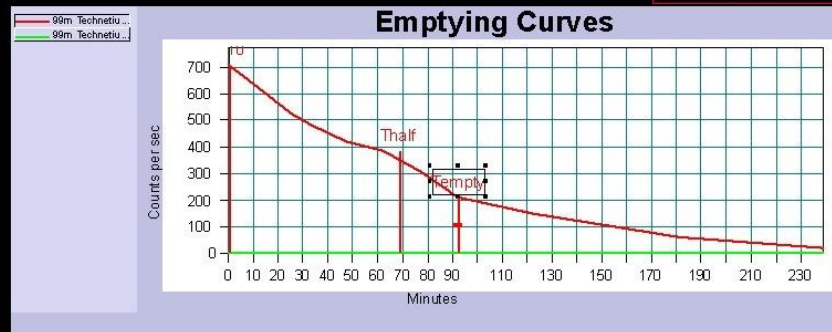
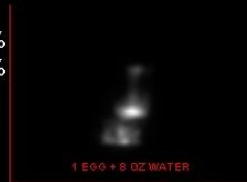Normal gastric emptying study

Bkgd Correction	On	Parameter	99m Technetium
Decay Correction	On	Emptying	70 %
Geometric Mean	On	Emptying begin (T0)	0 mins
		Emptying end	92 mins
		T 1/2	69 mins
		T0 -> T 1/2	69 mins

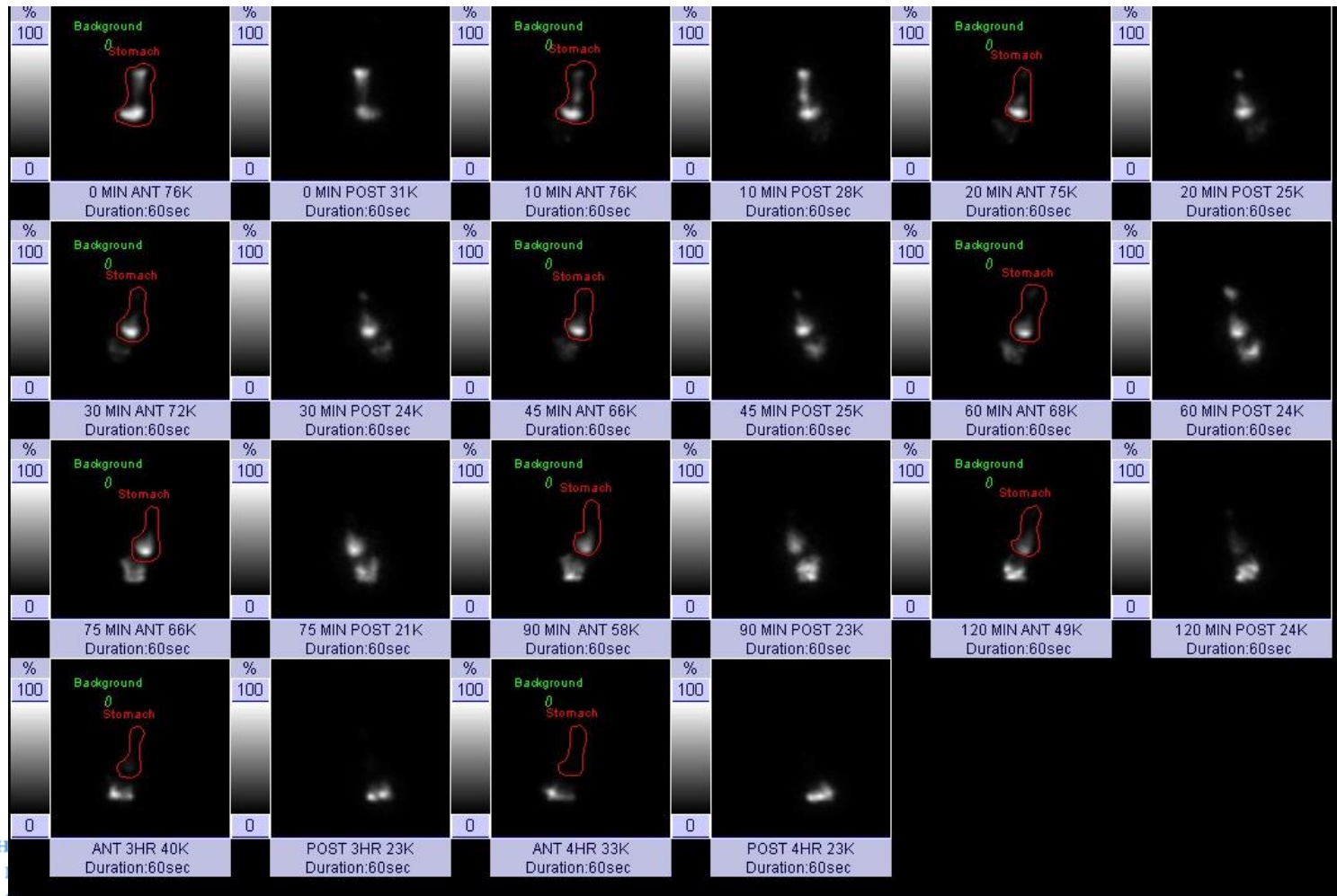
PERCENT EMPTYING WITH NO CURVE FIT

Series Description: GASTRIC EMPTYING
Study Date: 4/4/2016
Study Time: 12:17:16 PM
Operator Name: AC/YM
Radiopharmaceutical 1: 36.3 MBq (0.98 mCi) Sulfur Colloid
Energy Window Group 1: 99m Technetium

EMPTYING AT 60 MIN = 45%
EMPTYING AT 90 MIN = 70%
EMPTYING AT 2HRS = 79%
EMPTYING AT 4HRS = 97%



Normal gastric emptying scan: images



Rapid gastric emptying scan

Bkgd Correction	On	Parameter	99m Technetium
Decay Correction	On	Emptying	92 %
Geometric Mean	On	Emptying begin (T0)	0 mins
		Emptying end	120 mins
		T 1/2	17 mins
		T0 -> T 1/2	17 mins


PERCENT EMPTYING WITH NO CURVE FIT

Series Description: GASTRIC EMPTYING
 Study Date: 8/6/2015
 Study Time: 9:58:27 AM
 Operator Name: motfej
 Radiopharmaceutical 1: 40.7 MBq (1.10 mCi) Sulfur Colloid
 Energy Window Group 1: 99m Technetium

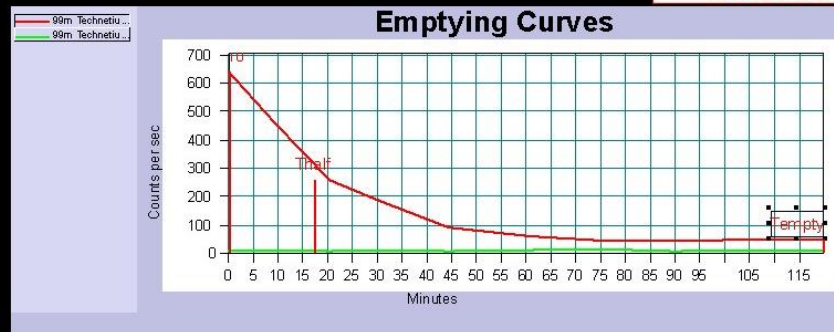
EMPTYING AT 60 MIN
 EMPTYING AT 90 MIN
 EMPTYING AT 120 MIN

MOT/EJR/AA

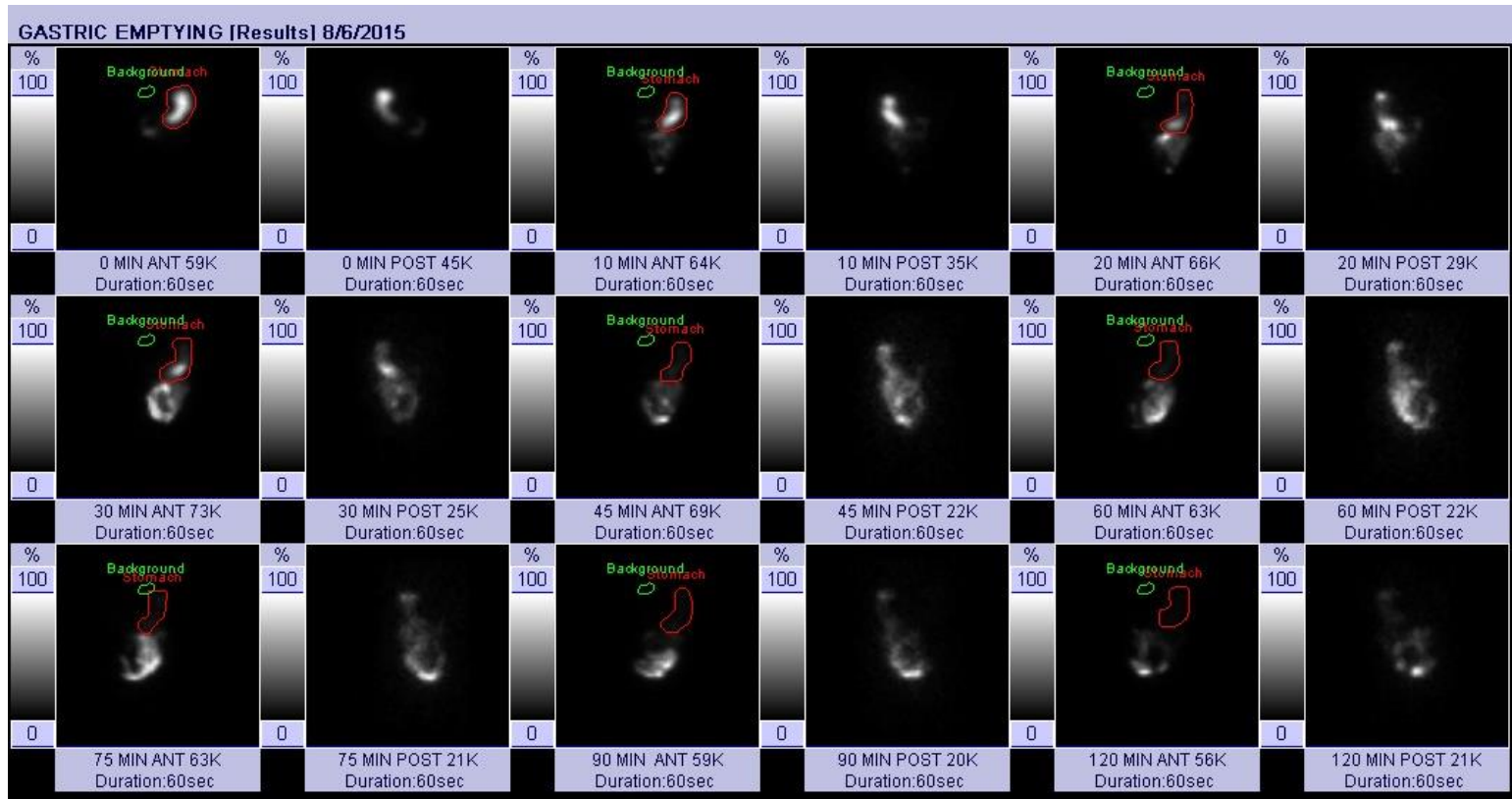
91%
 93%
 92%



1.1mCi Tc-99m SC
 in 1 egg
 W/ 4 oz of water



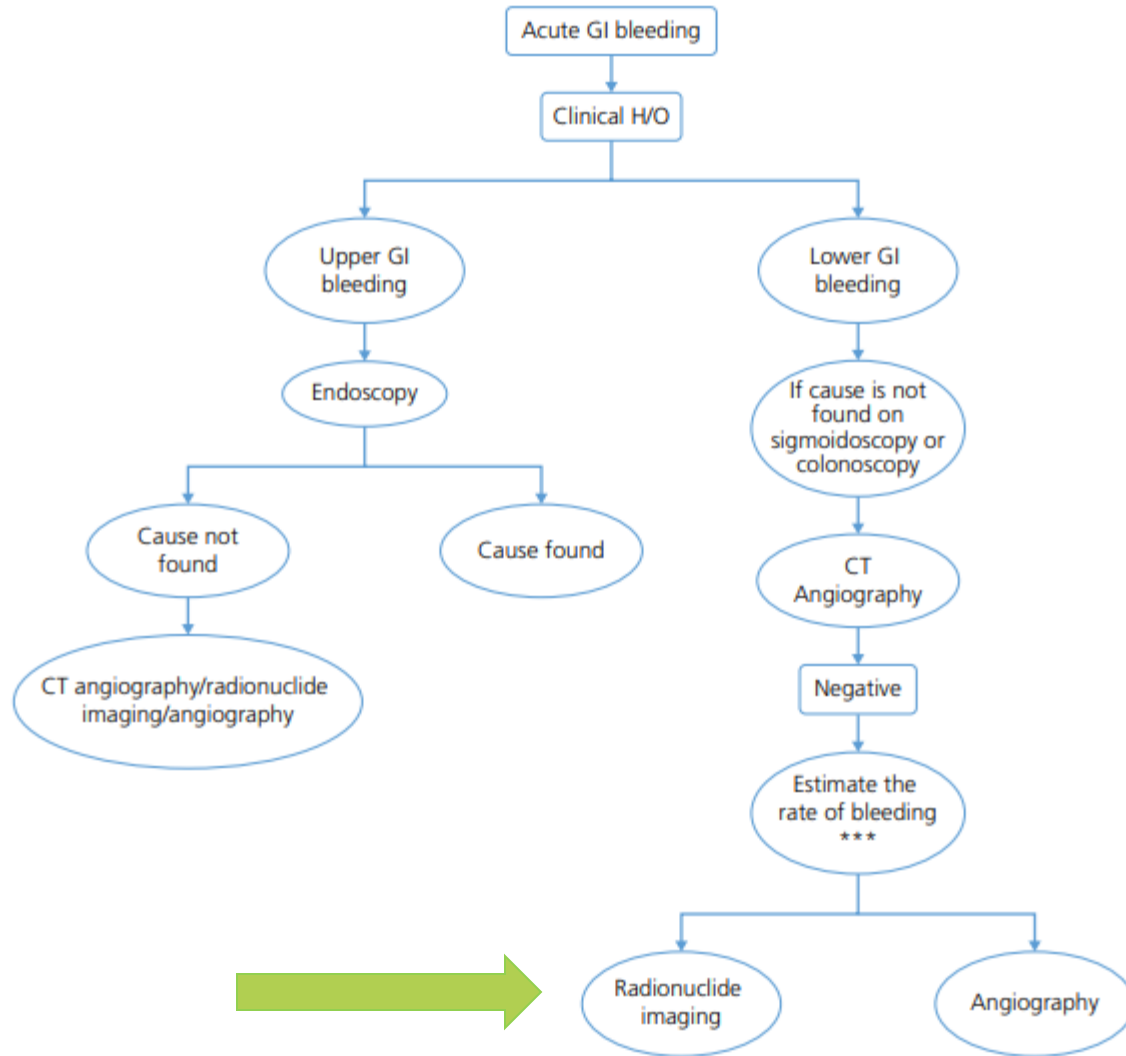
Rapid gastric emptying scan: images



GI: GI bleed study

- When do we order the study? When we believe there is an active slow GI bleed
- What is the clinical question? Does the patient have an **active** lower GI bleed?
 - This study is not sensitive for upper GI bleeds
- What are we studying? Extravasation of tracer from the vasculature of the GI tract

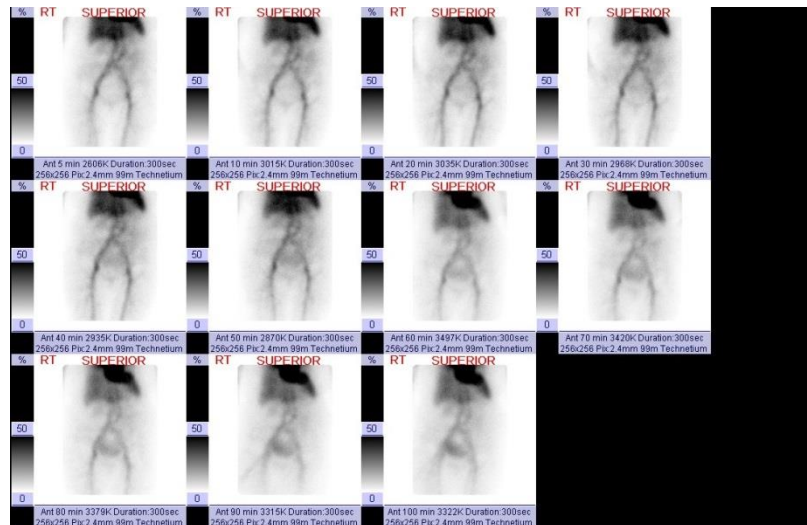
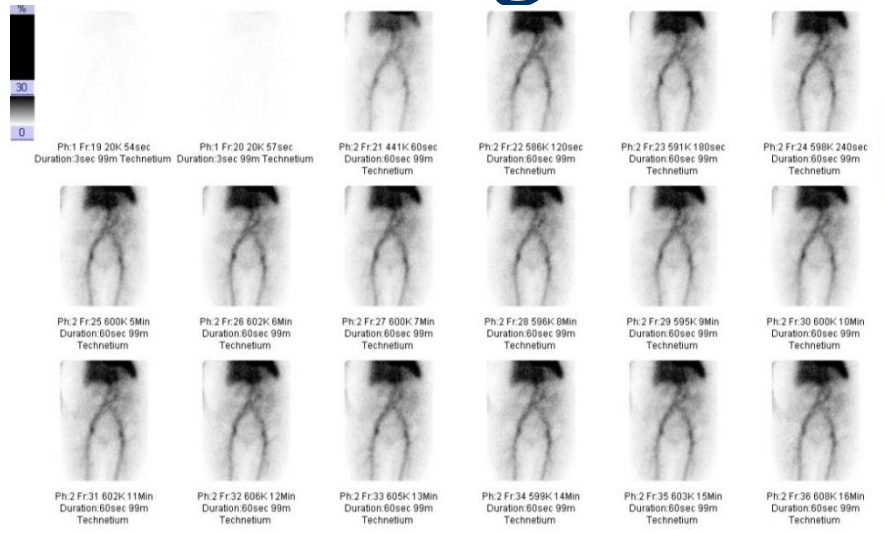





CT, computed tomography.



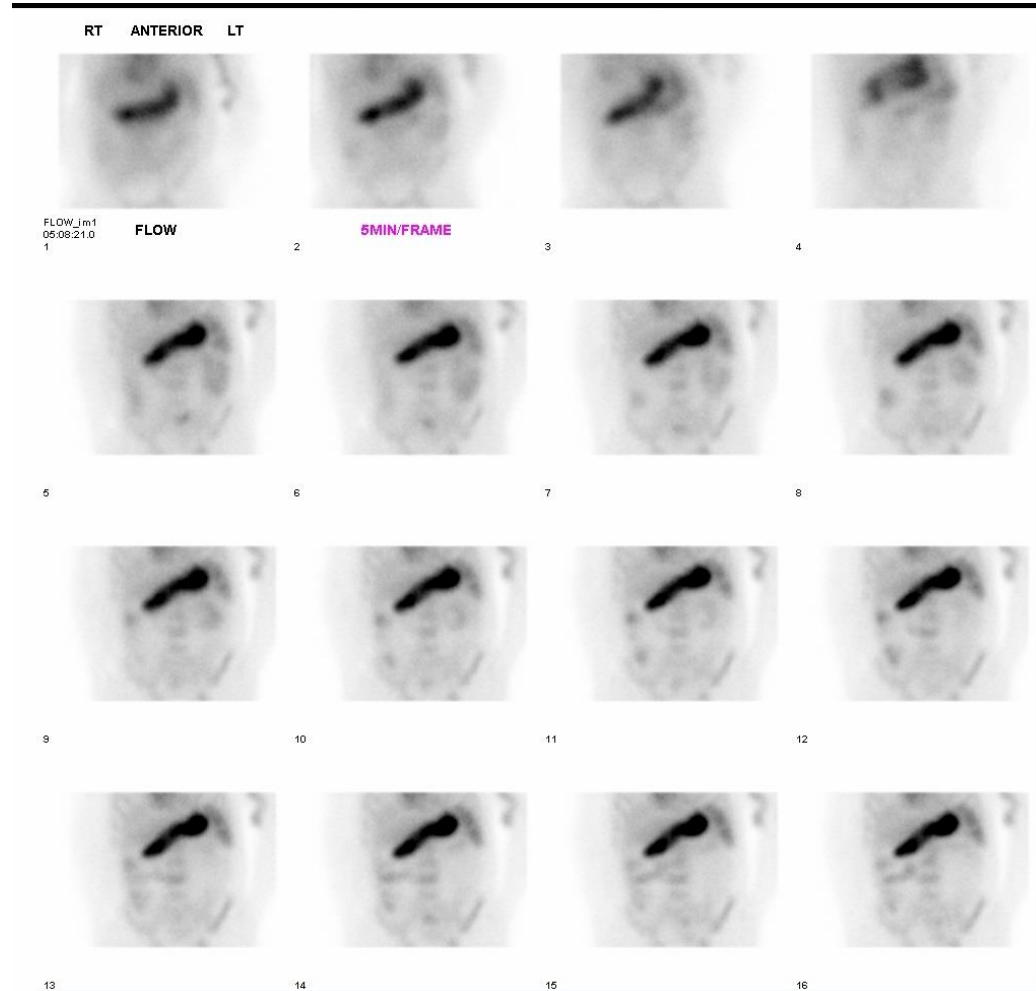
GI bleed: negative study

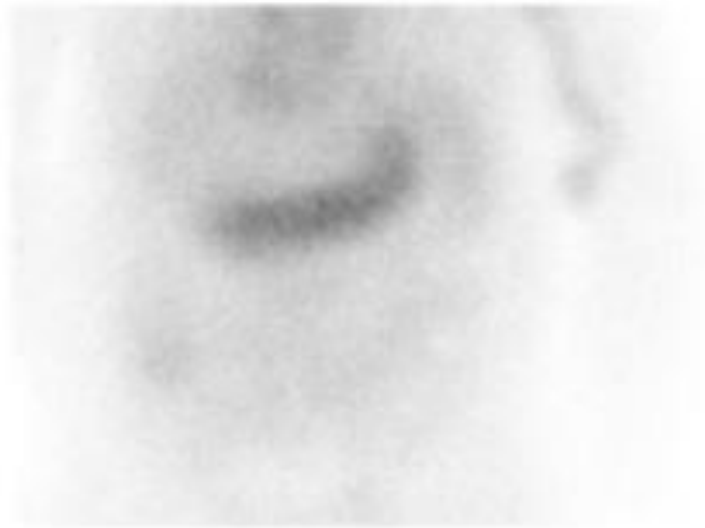

GI bleed: negative cine



GI bleed: positive study



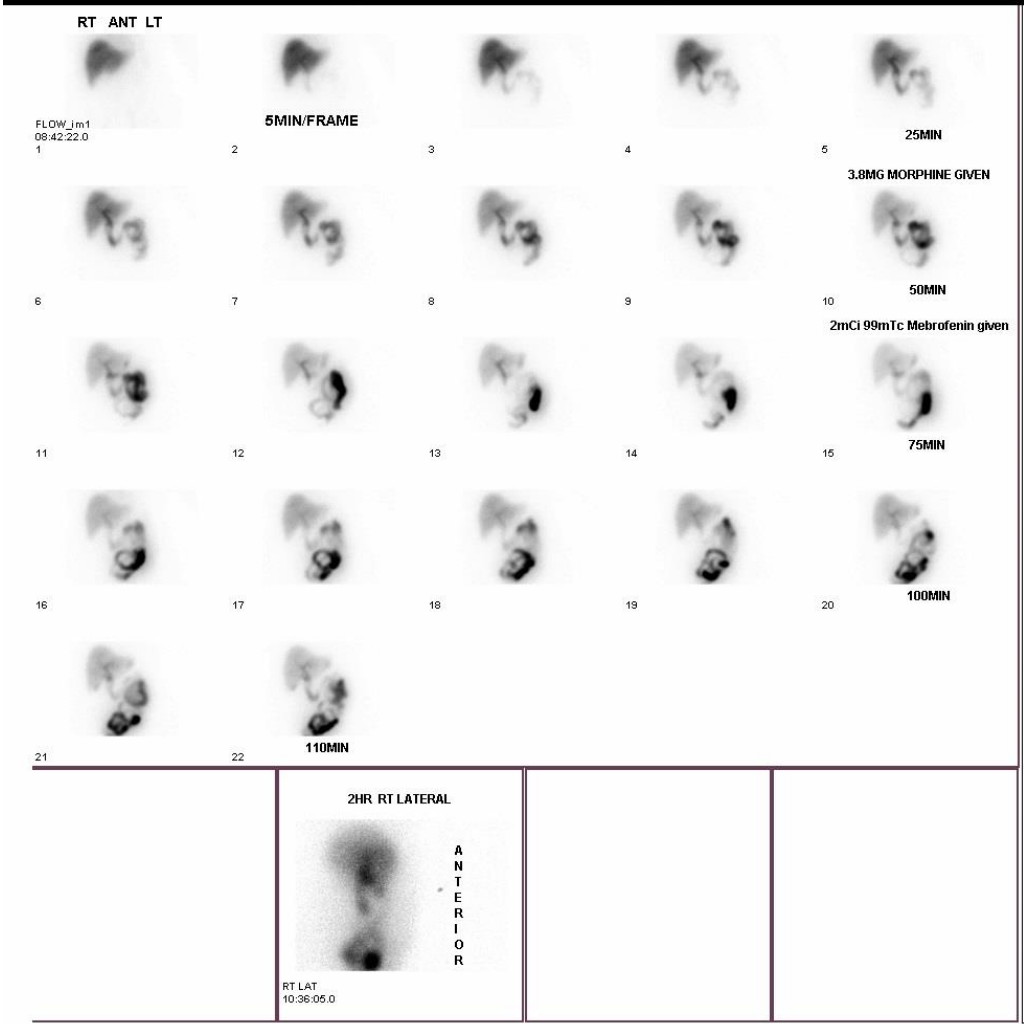


GI: HIDA scan

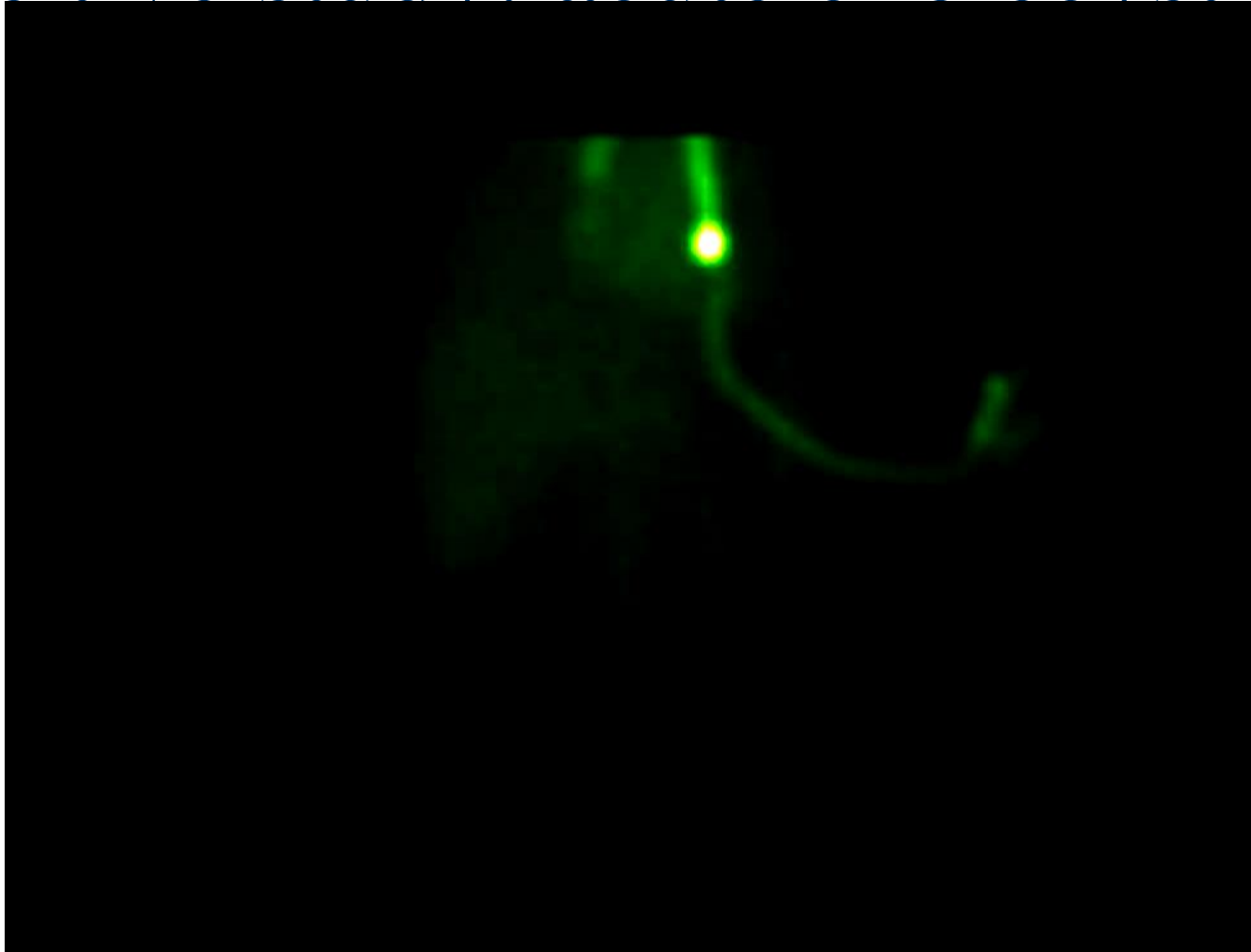
- When do we order the study? When US is inconclusive and we are still worried about cholecystitis
- What is the clinical question? Does the patient have cholecystitis?
 - Used if ultrasound (or CT) is inconclusive; good sensitivity
 - Can also be used to look for biliary patency, biliary atresia, gallbladder function, and biliary leaks
- What are we studying? Movement of bile through the biliary system



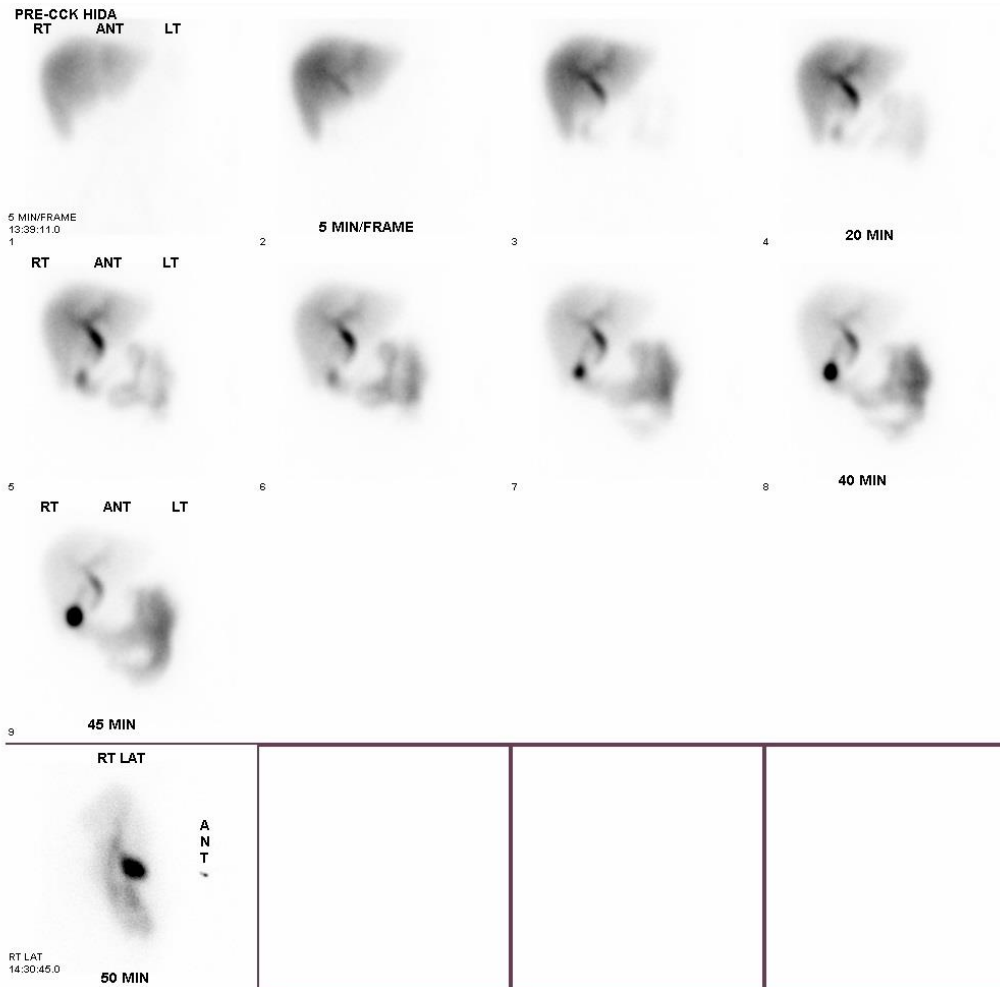
Positive study

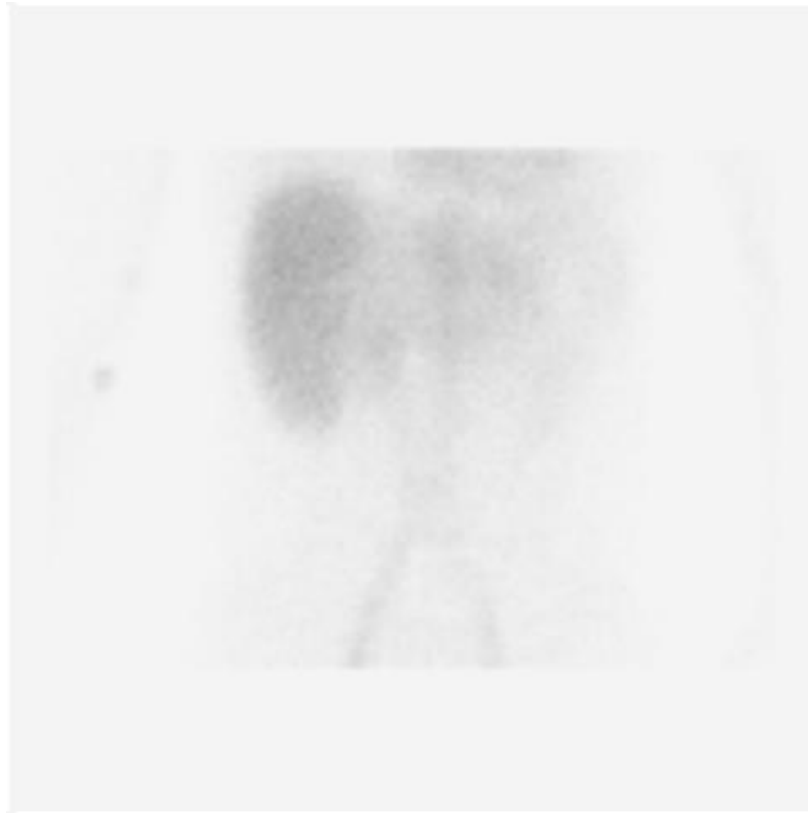


Positive study: acute cholecystitis



Negative study



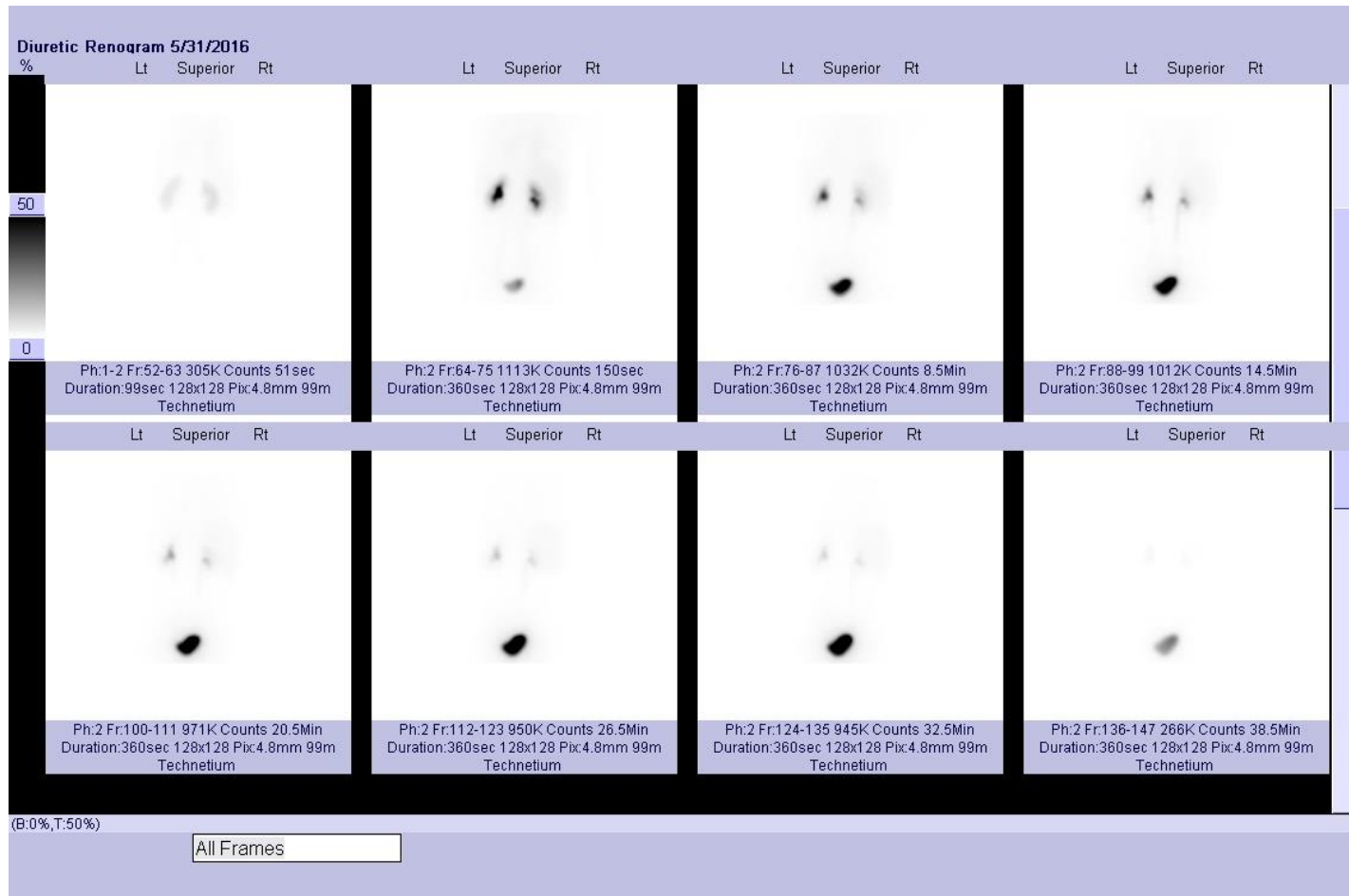

MAG-3 scan

- **When do we order the study?** Usually before or after urologic surgery to relieve obstruction
- **What is the clinical question?** Are the kidneys able to excrete urine, or is it stuck in the collecting system?
- **What are we studying?** Presence of functioning renal proximal tubules



Normal MAG-3: images



Normal MAG-3: graph

Table of Result Summary

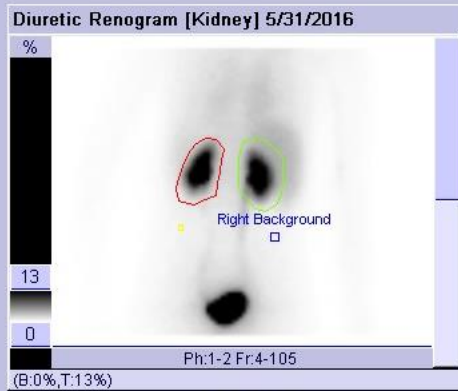
Parameters	Left	Right	Total
Split Function (%)	41.8	58.2	
Kidney Counts (cpm)	26536	36994	63530
Time of Max (min)	5.502	3.502	
Time of ½ Max (min)	9.670	7.413	
Time from Max to ½ Max (min)	4.168	3.910	

Table of Result Summary

Parameters	Left	Right	Total
Split Function (%)	41.8	58.2	
Kidney Counts (cpm)	26536	36994	63530
Time of Max (min)	5.502	3.502	
Time of ½ Max (min)	9.670	7.413	
Time from Max to ½ Max (min)	4.168	3.910	

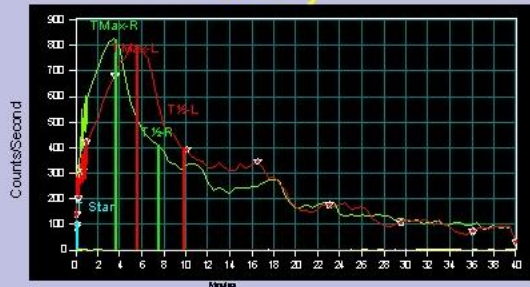
Table of Result Summary

Parameters	Left	Right	Total
Split Function (%)	32.8	67.2	
Cortical Counts (cpm)	5309.2	10860	16169



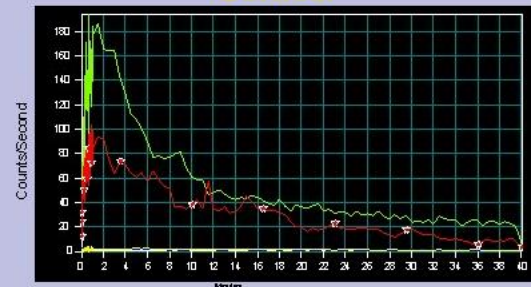Kidney

--Left--
--Right--



Cortical

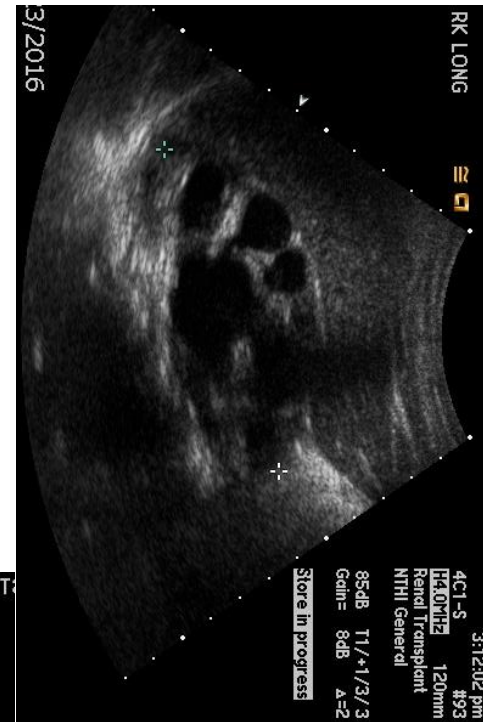
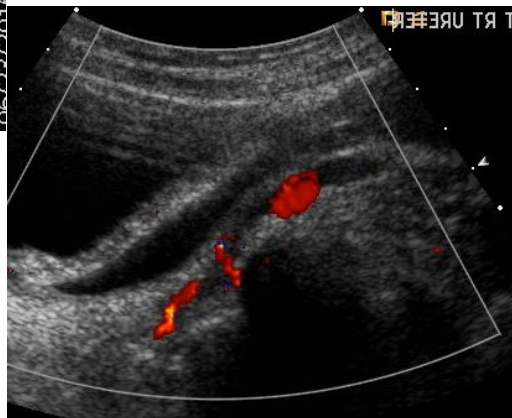
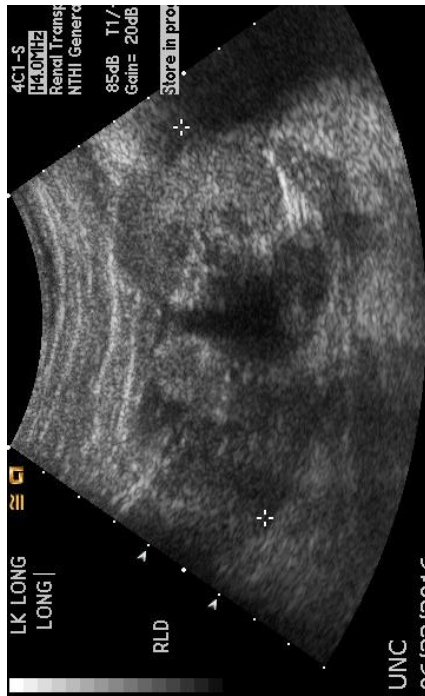--Left--
--Right--



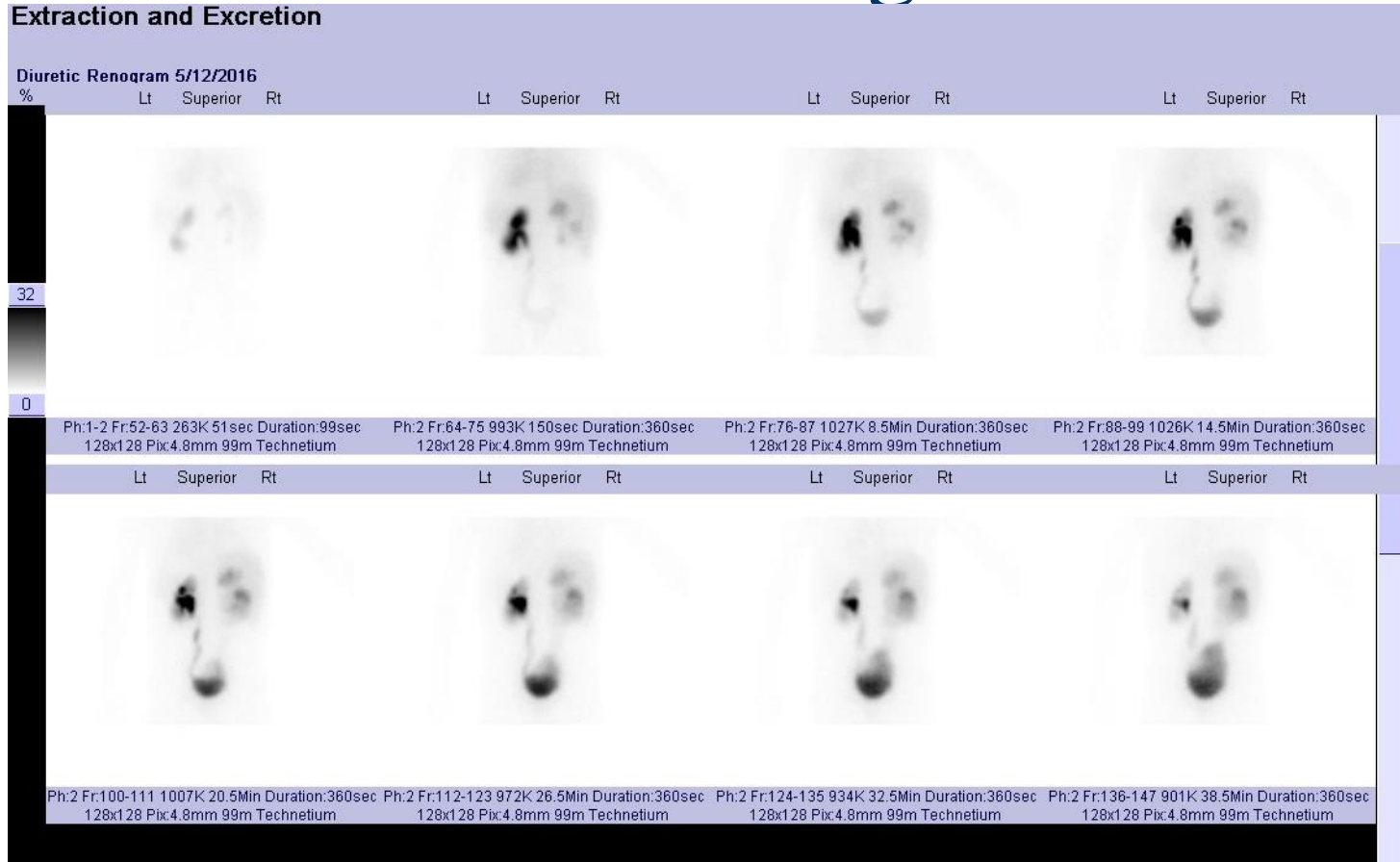
Normal MAG3-movie



Bilateral hydronephrosis (and unilateral hydroureter): obstruction?

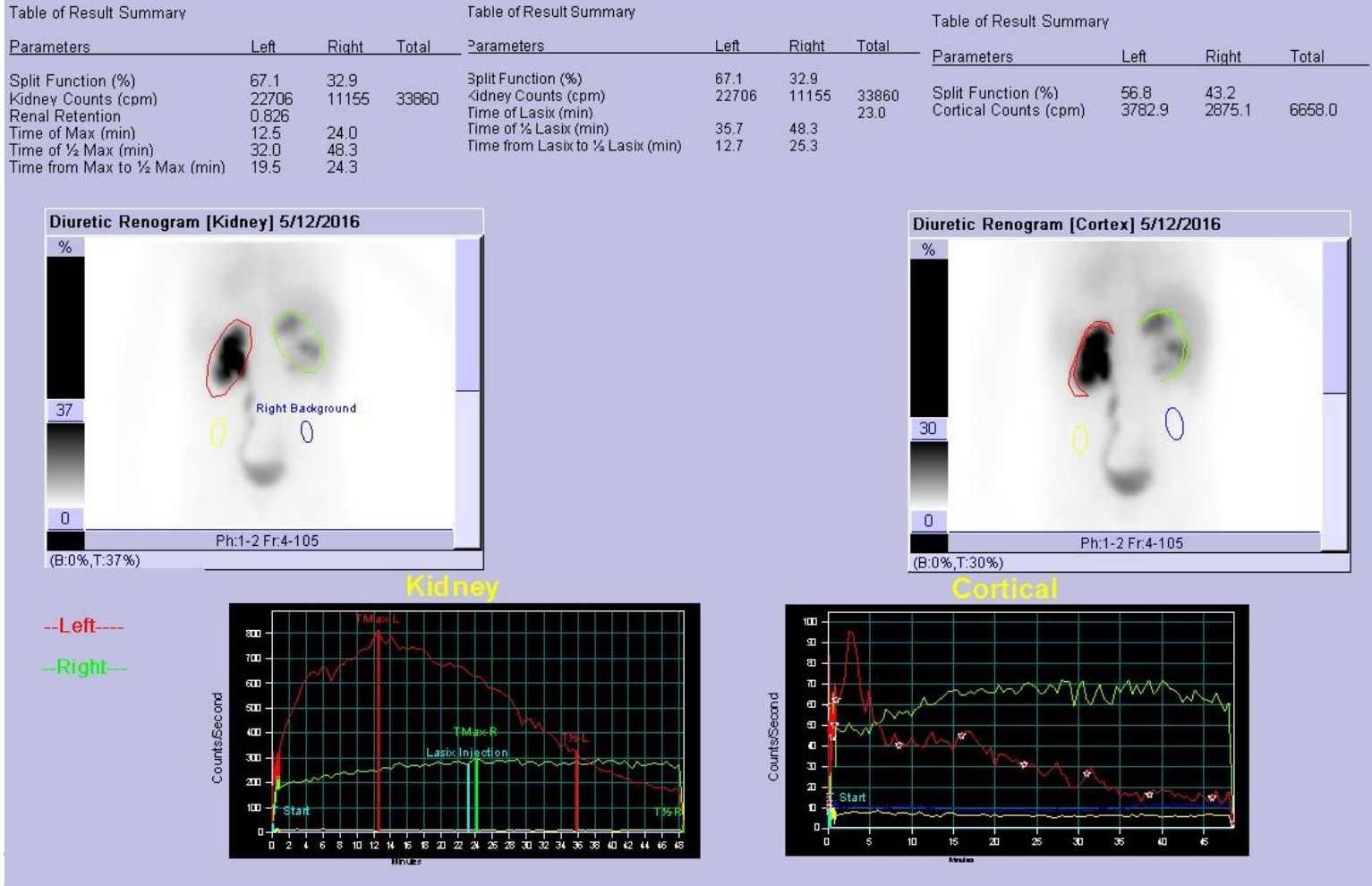


Obstructed (and partially obstructed) MAG-3: images



Obstructed (and partially obstructed)

MAG-3: graph



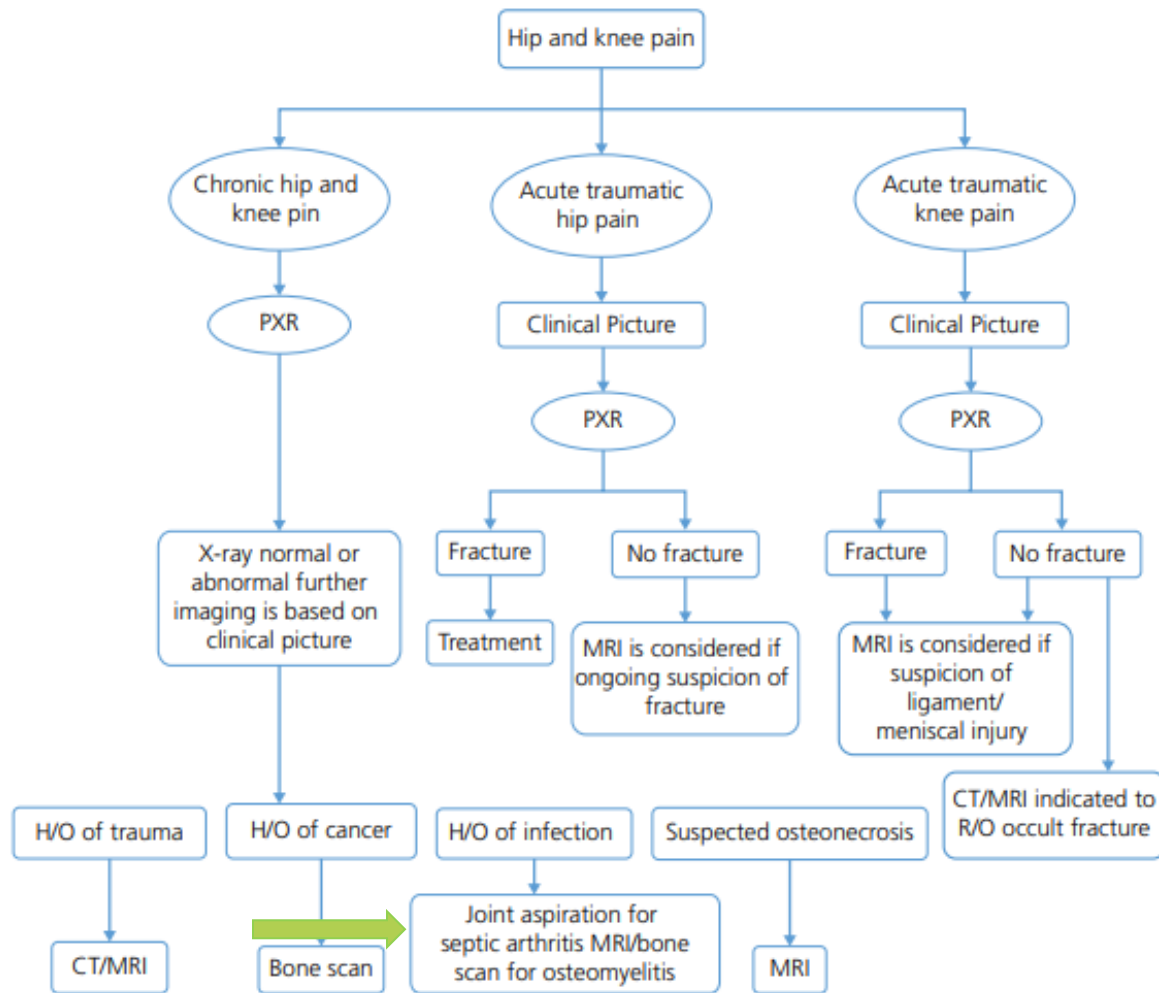
Obstructed (and partially obstructed) MAG-3: movie



Bone scan

- **When do we order the study?** Most commonly when staging breast or prostate cancer (which have metastases that may not be seen on CT)
 - Also has applications looking for osteomyelitis, joint prosthesis loosening, and spondyloylsis
- **What is the clinical question?** Are there metastases to bone?
 - It's also used in some orthopedic applications such as looking for osteomyelitis or joint prosthesis loosening
- **What are we studying?** New bone formation

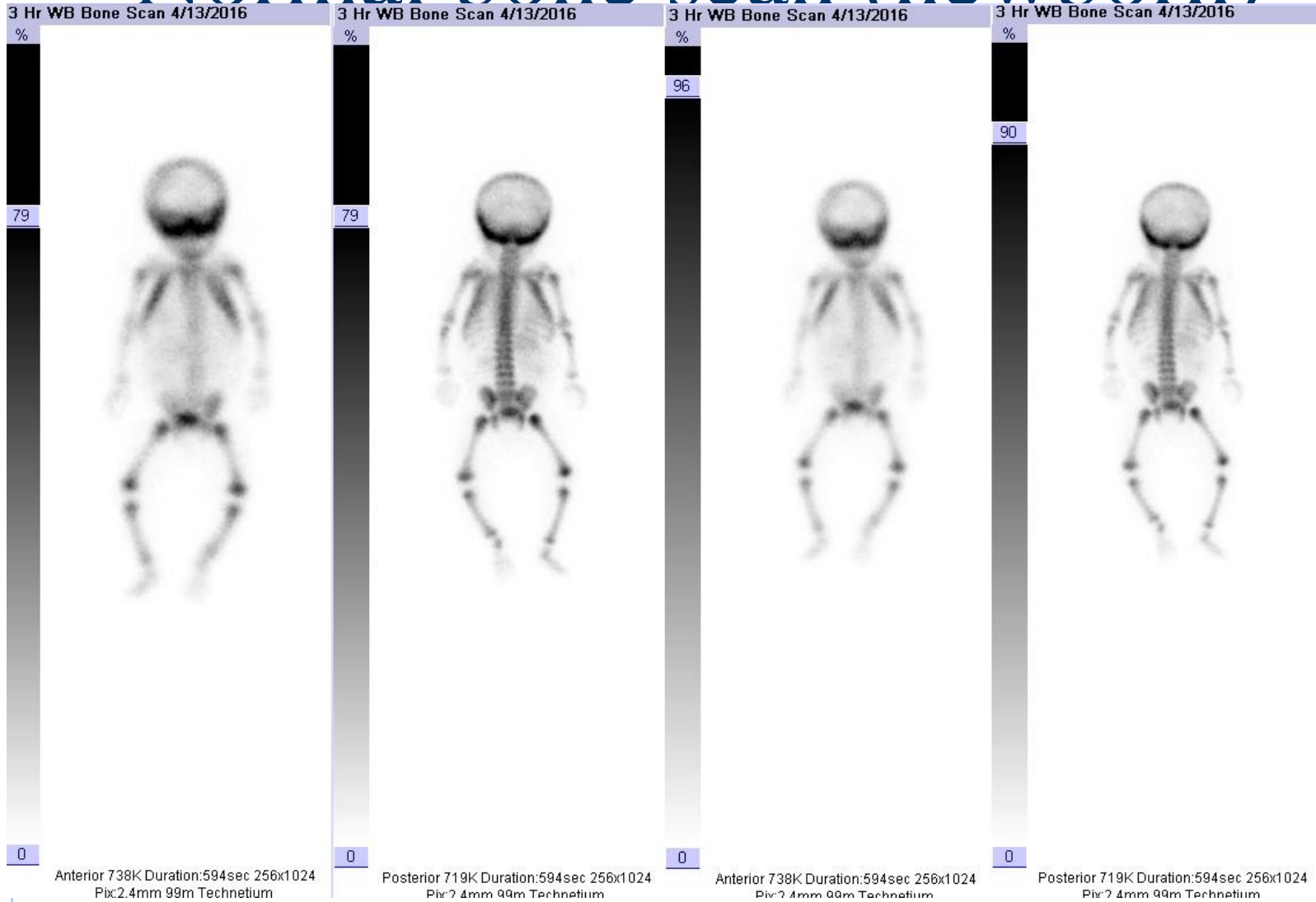




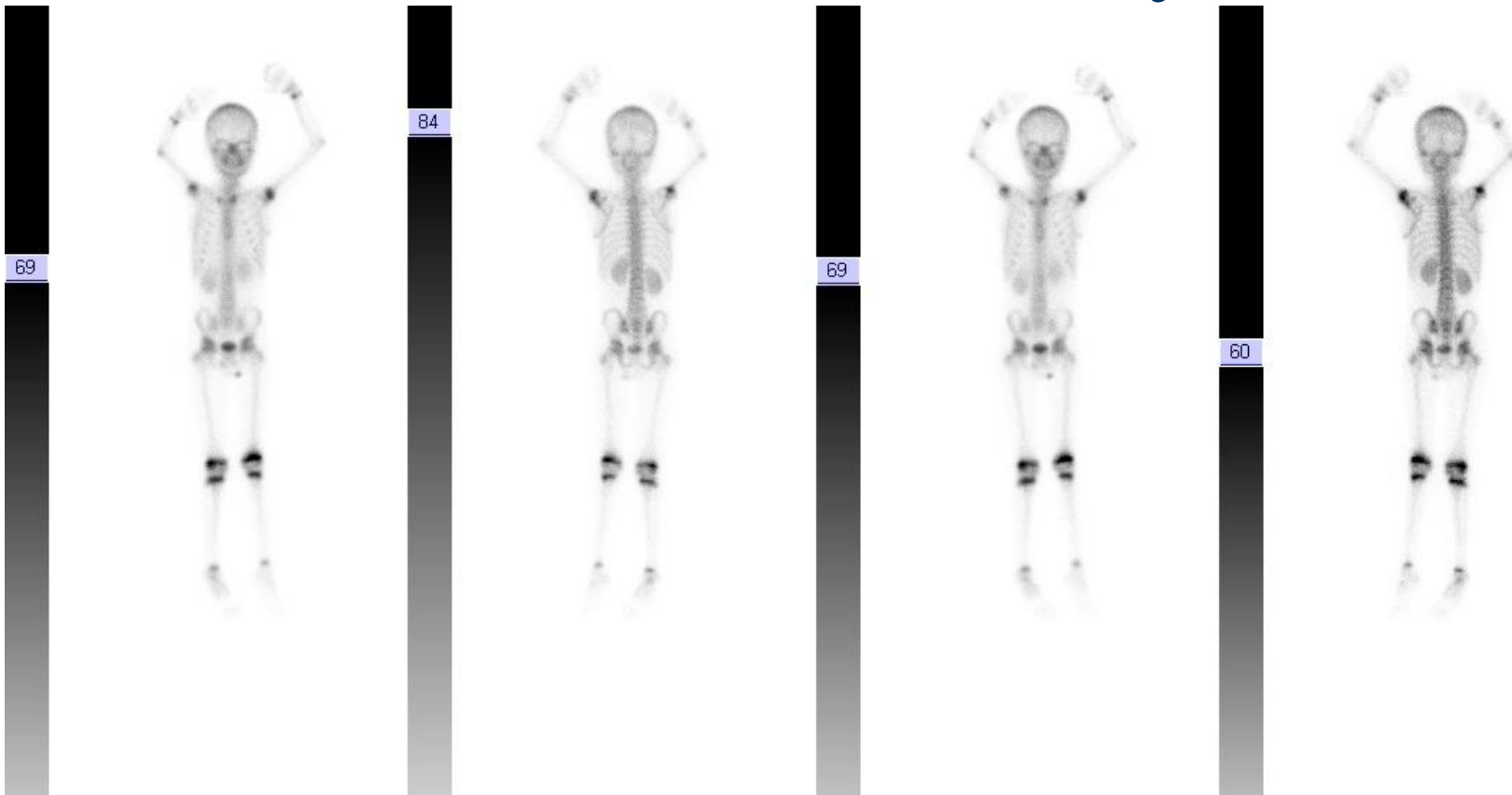
CT, computed tomography; MRI, magnetic resonance imaging.



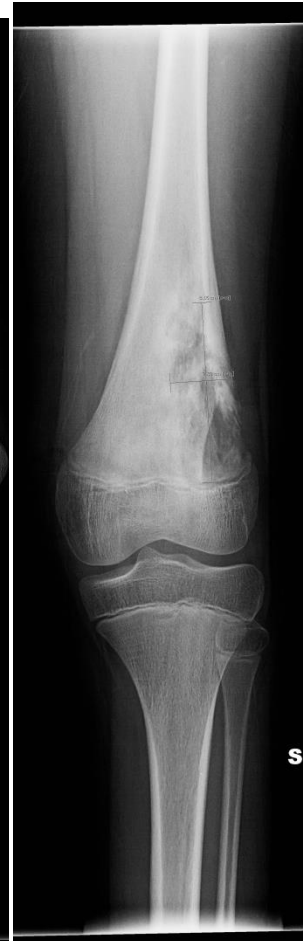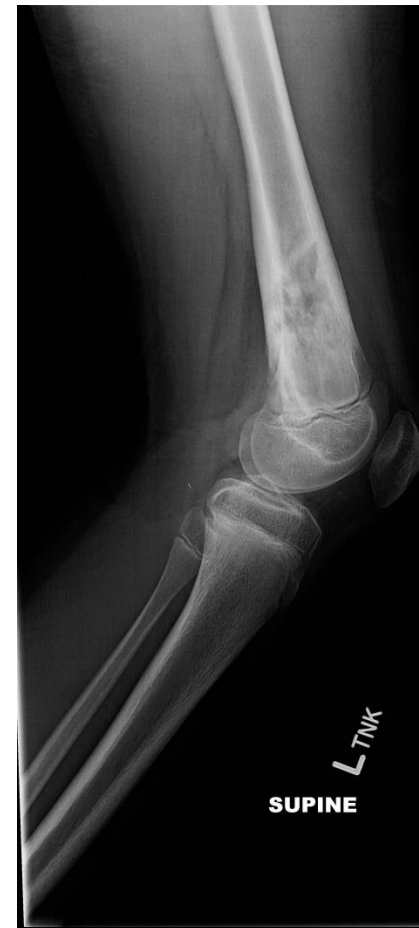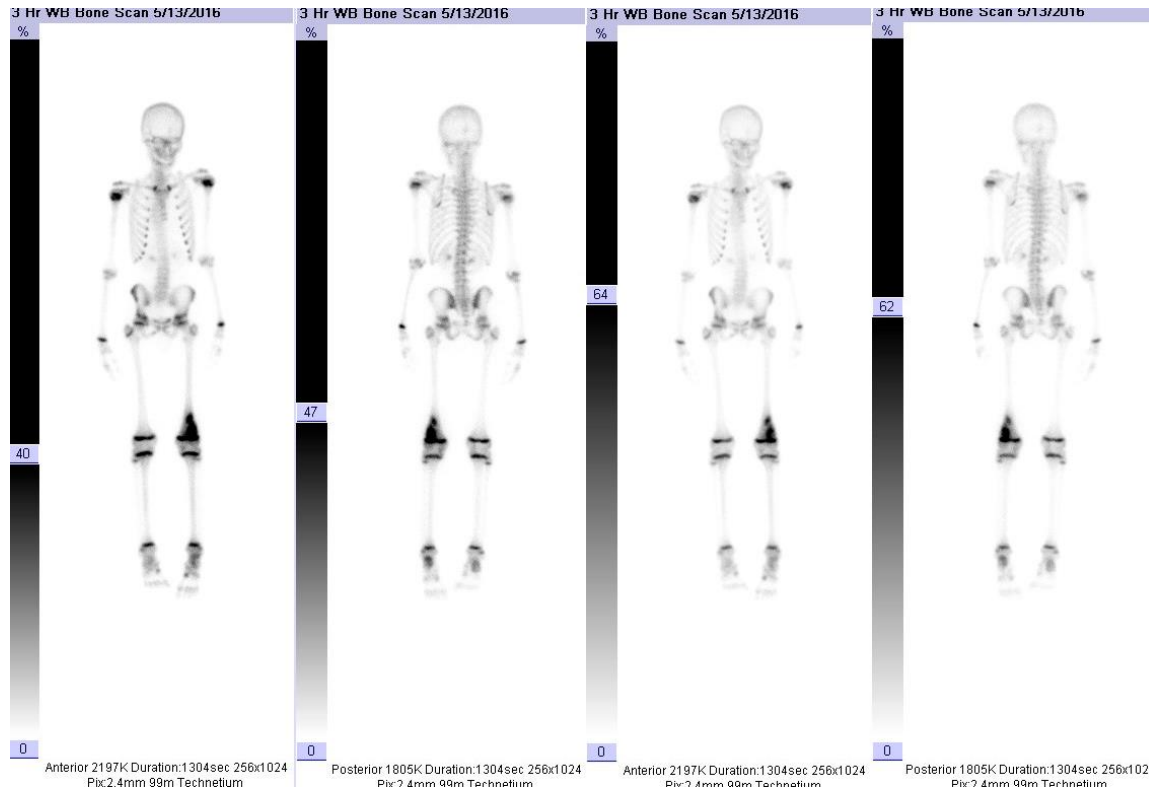
Normal bone scan (newborn)



Normal bone scan (11 yr old)



Positive bone scan (osteosarcoma)



Positive bone scan (diffuse mets)

