RADY 403 Case Presentation

Jessica Sibley, MS4
April 2019

UNC SCHOOL OF MEDICINE
Radiology

Focused patient history and workup

- 17 month old M presented to OSH (subsequently transferred to UNC)
- On presentation to OSH, patient had poor tone and was tachypneic and tachycardic. He was Flu A positive.
- Additional history:
  - Term birth at home
  - Unvaccinated with no visit to PCP since age 6 weeks
  - Was able to pull up and crawl until ~ 3 mos prior to admission to OSH, then stopped
  - Exclusively breastfed infant for 7 mos, then transitioned to vegan diet with hemp milk and some breastfeeding
    - Immediate concern for rickets given history and palpable left forearm callus
  - No pertinent family hx

List of pertinent imaging studies

- CXR and X-ray of LUE obtained upon initial OSH presentation
- Three pediatric skeletal surveys
  - First obtained on HD 2
  - Second obtained on HD 14
  - Third obtained HD 39 (after transfer to UNC)
- RUE radiographs from HD 19
- CXR obtained HD 47 (a few days before discharge)

Initial CXR obtained at OSH admission

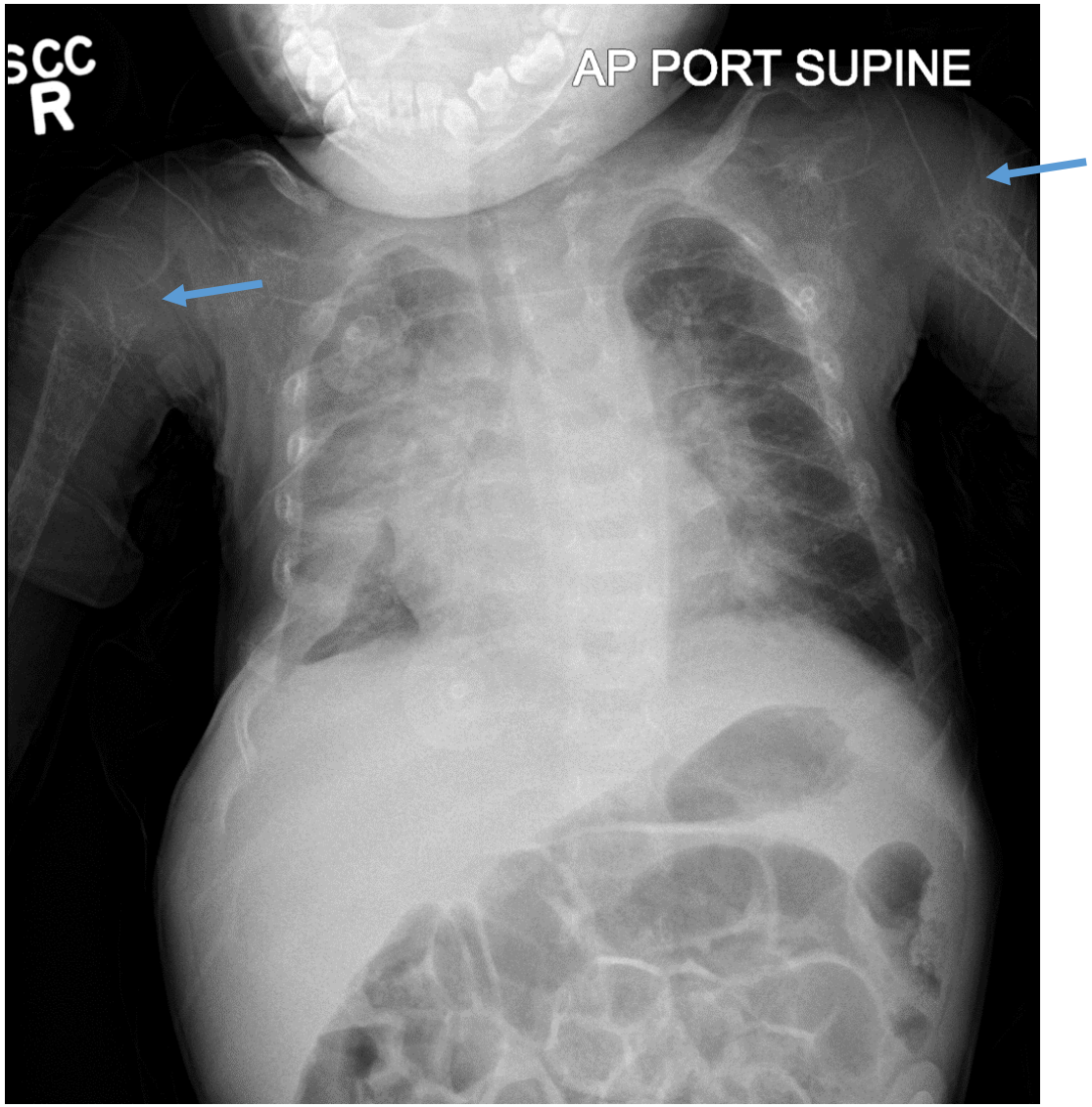

- Initial CXR revealed right lung consolidation and left perihilar opacities consistent with multifocal pneumonia
  - Flu A positive at admission
  - Possible superimposed bacterial pneumonia
- Demineralization apparent at proximal humeri (arrows)

Initial LUE radiograph obtained at OSH admission

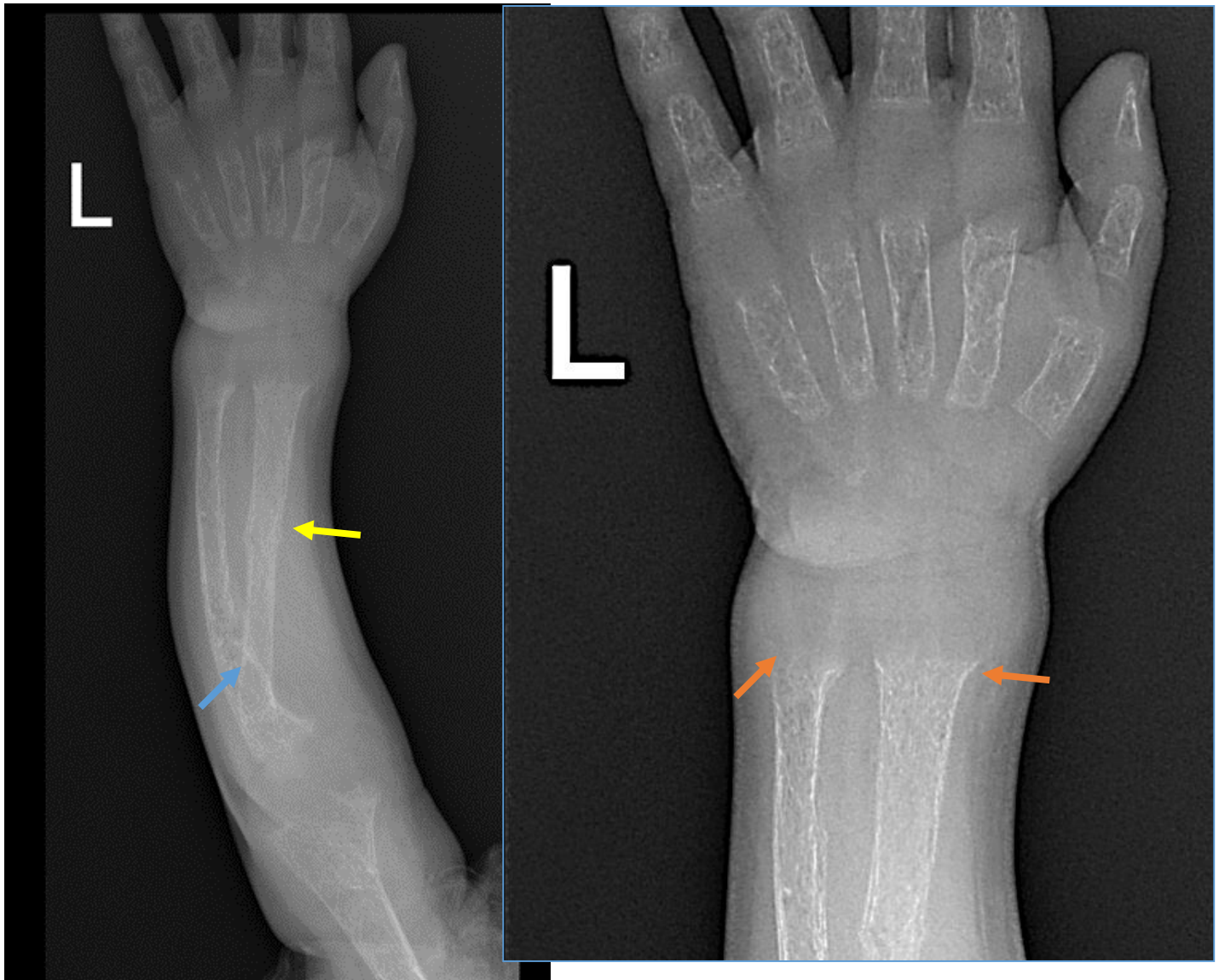

- LUE radiograph obtained due to palpable callus showed fractures of the left radius and left ulna
  - Skeletal survey ordered the following day showed no additional fractures.
- Initial LUE x-ray shows widening of the physis, demineralization of the metacarpals, and rachitic changes of the metaphyses

Second skeletal survey from OSH HD 14

- Second skeletal survey revealed additional fragility fractures:
  - Midshaft lucency of the right ulna
  - Midshaft periosteal reaction in the left fibula consistent with healing fracture
- Note the demineralization and metaphyseal changes

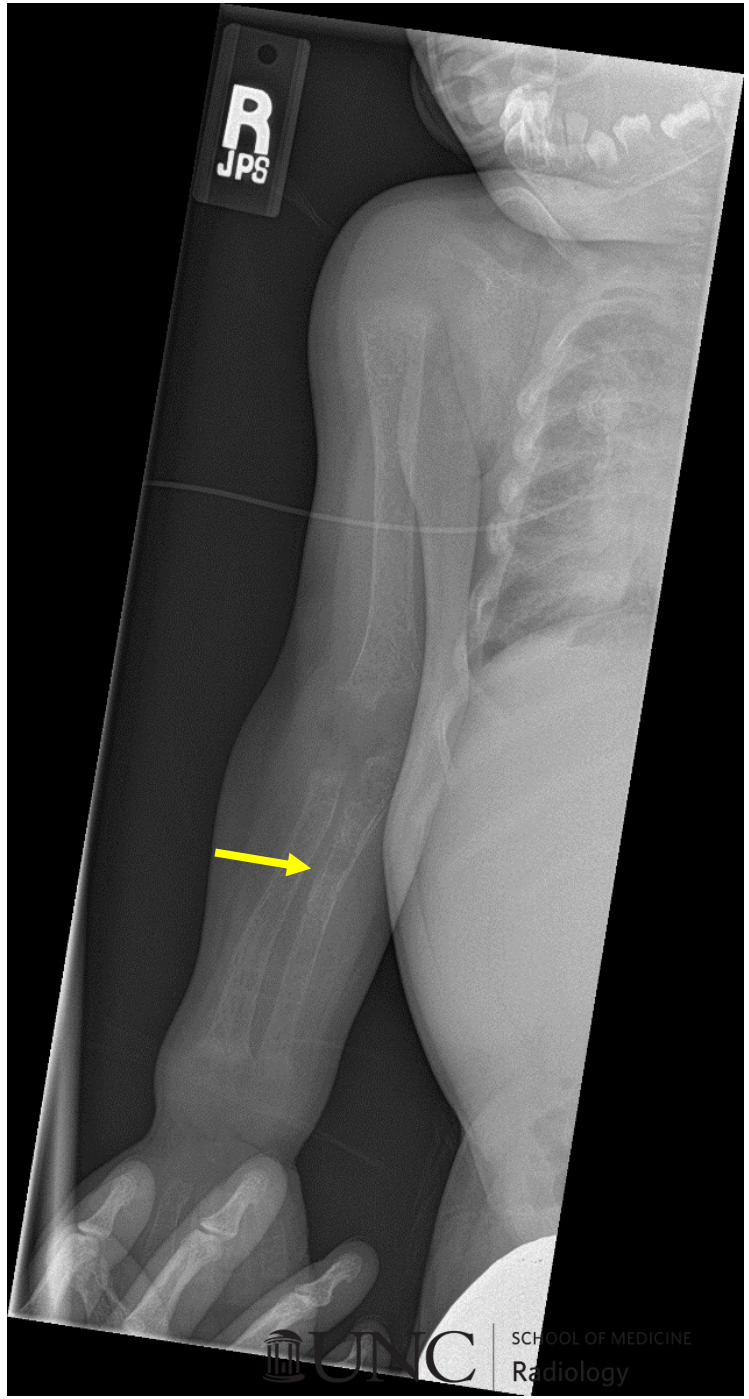

Second skeletal survey from OSH HD 14, also HD 19

- X-ray of the right foot showed a fracture of the first metatarsal
- Additional x-rays showed right humeral, right radial (not pictured), and right third metacarpal fractures

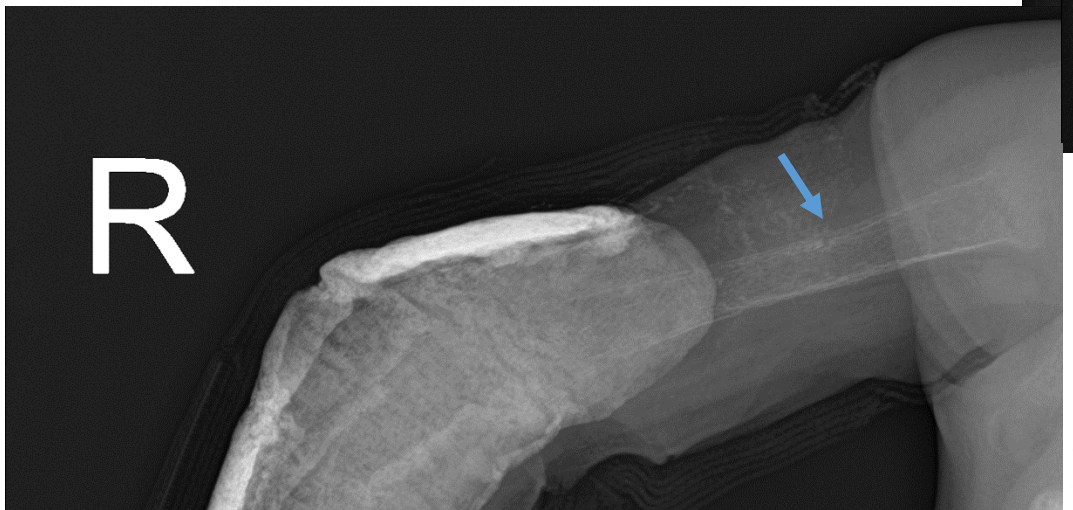

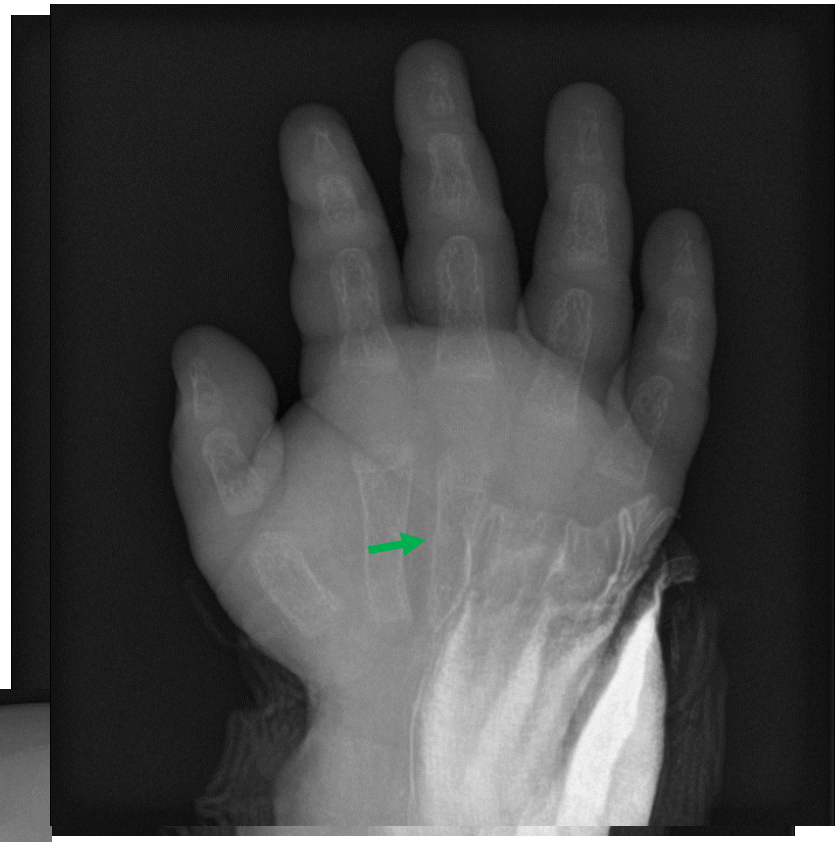

Repeat skeletal survey from OSH HD 39

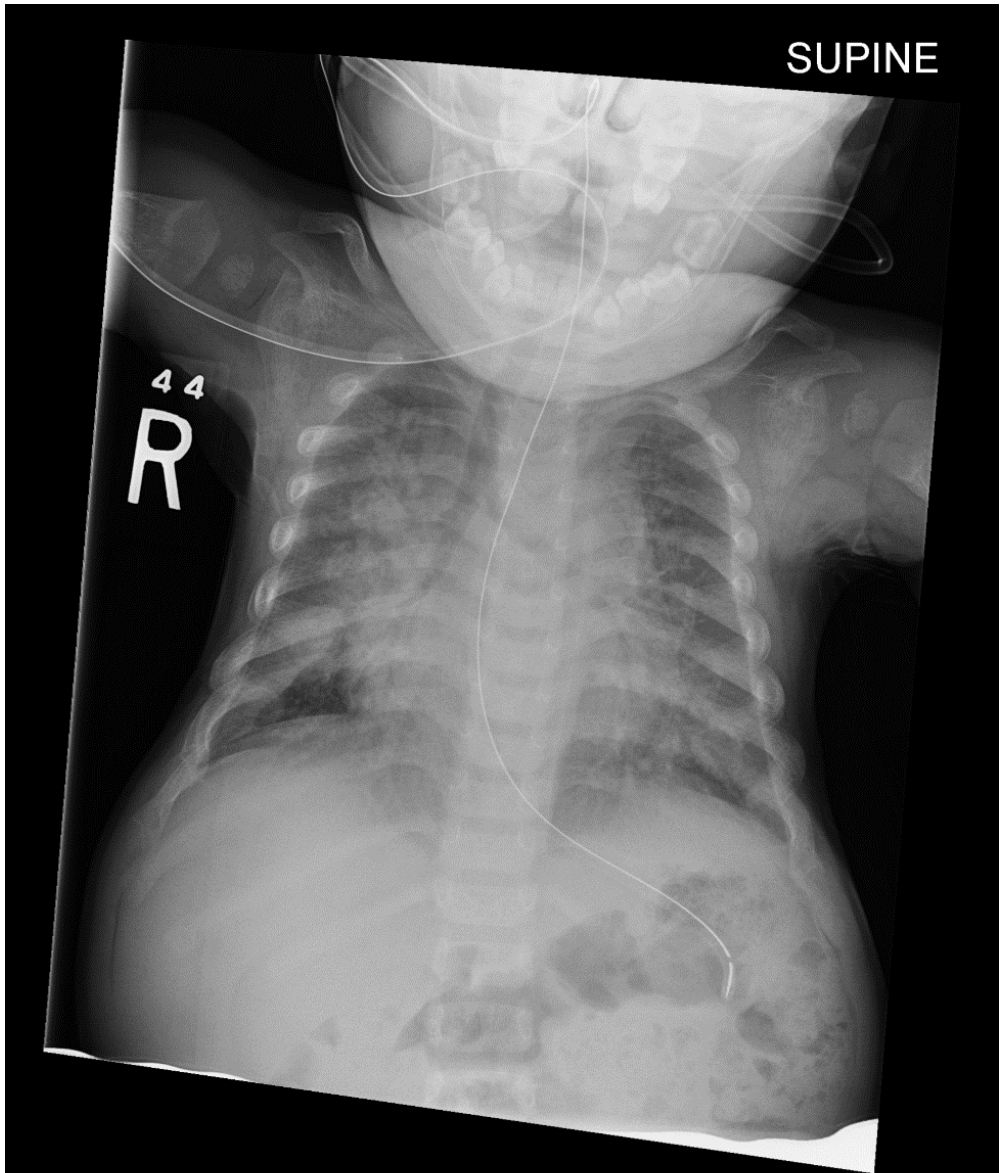

- Persistent pulmonary opacities
- Interval improvement in bone mineralization
- Healing of previously-appreciated left radial fracture

Repeat skeletal survey from OSH HD 39

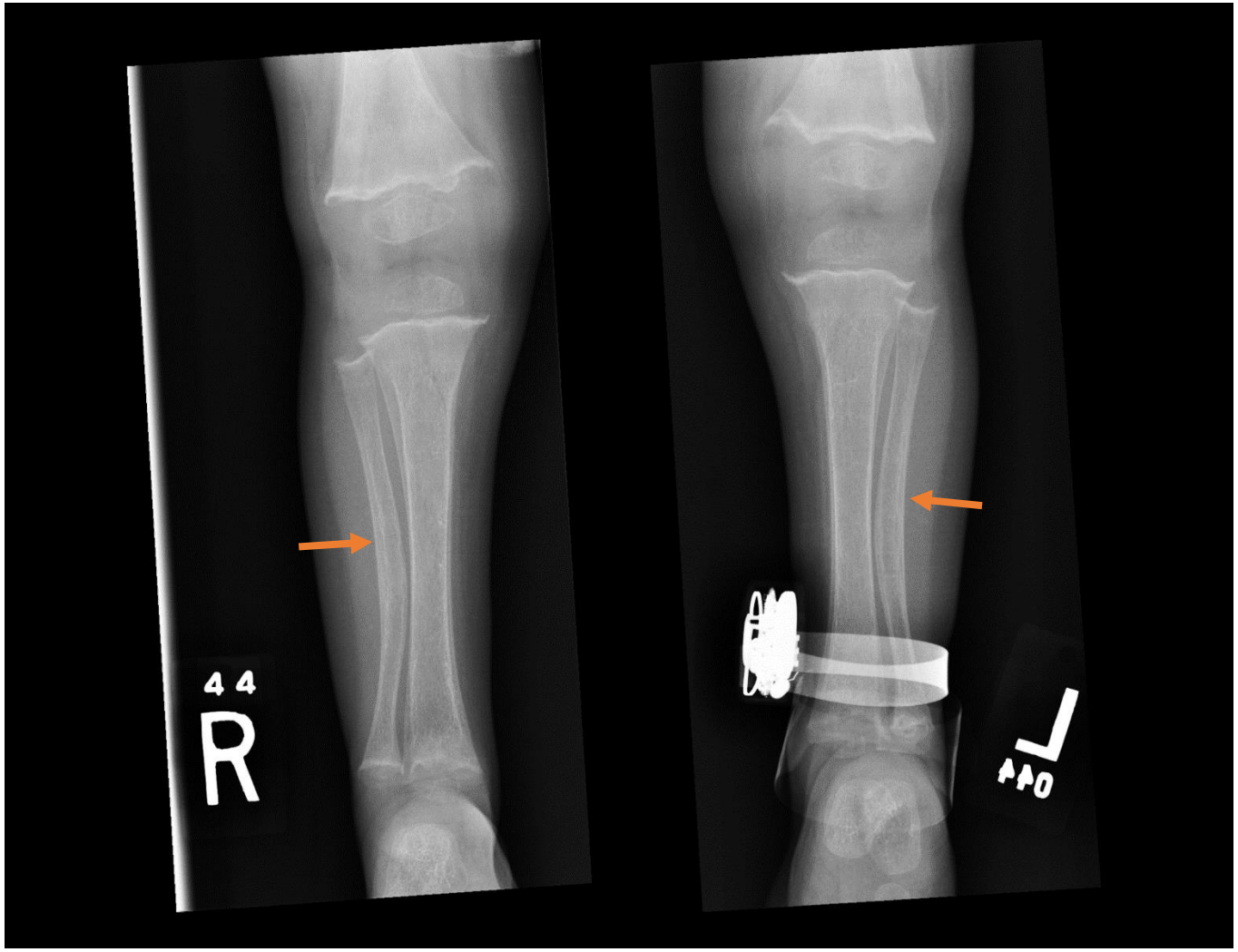

- Bilateral fibular bowing is apparent as well as periosteal reaction and improved bone mineralization

CXR from HD 47 (a few days prior to discharge)

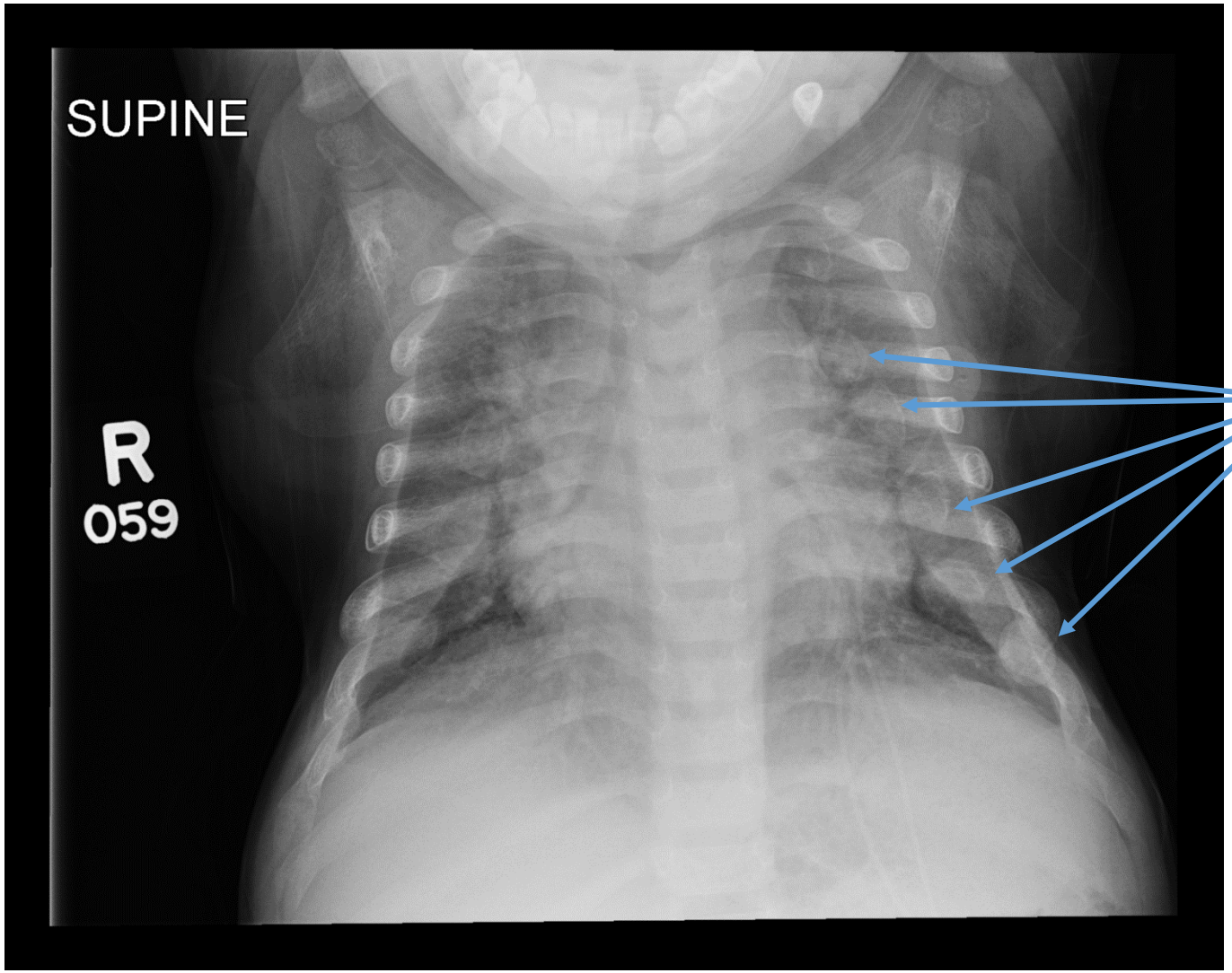

- Rachitic rosary first appeared on CXR obtained about two months after patient's initial presentation.

Rachitic rosary

Clinical course summary

- Prolonged stay at OSH (36 days) prior to transfer to UNC
  - PICU stay at OSH due to viral with possible superimposed bacterial pneumonia
  - Also found to have secondary hyperparathyroidism with low calcium, low phosphorus, elevated alkaline phosphatase, and vitamin D deficiency consistent with vitamin D deficiency rickets
  - Required NG feeds and O2 via LFNC upon transfer to UNC
- Multiple consultants involved at UNC: orthopedics, endocrinology, nutrition, and pulmonology
  - Improvement in endocrine labs and bone mineralization with targeted nutrition and supplementation
  - CXR concerning for persistent interstitial lung disease; negative sweat chloride test
- Pt discharged home with parents after greater than two month total hospitalization
  - Received routine vaccinations prior to discharge
  - Required CPAP on discharge (will follow up with pulmonology)

Discussion: types of rickets and approach

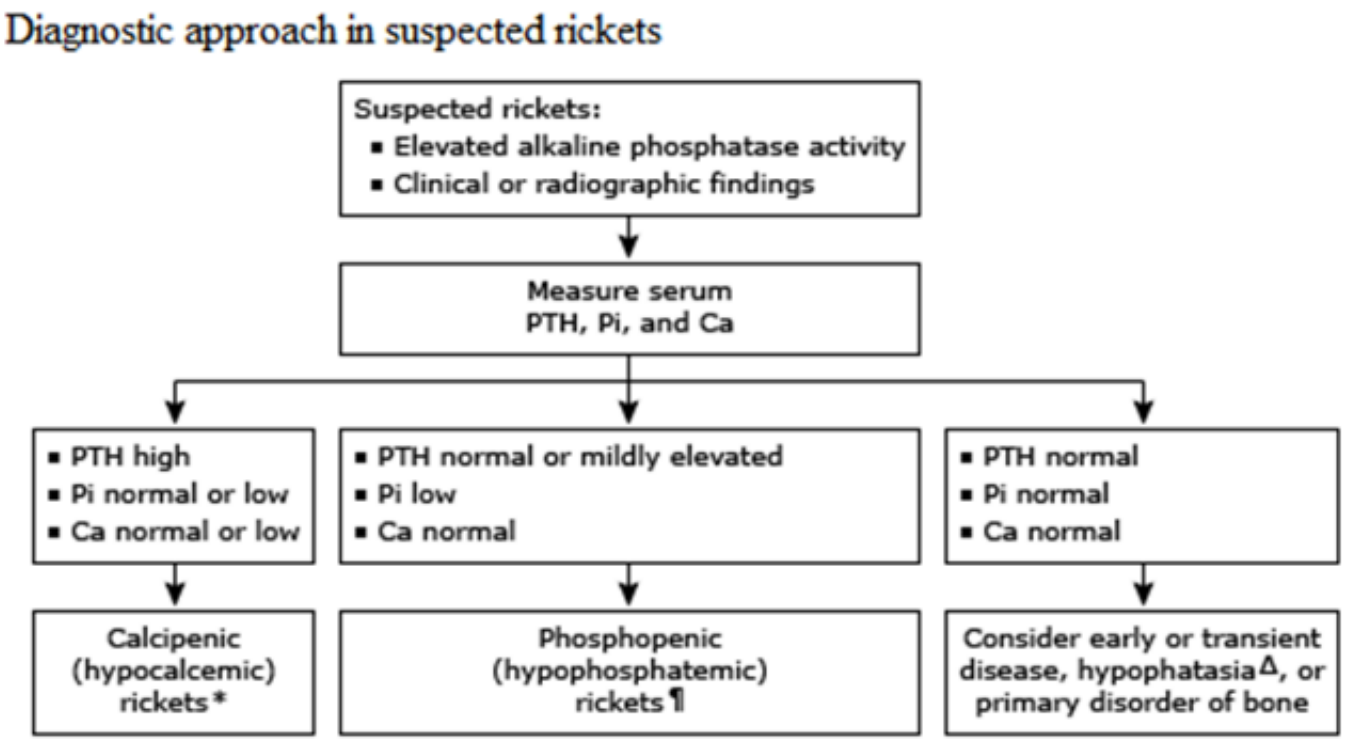

Rickets was historically divided into "calcipenic" and "phosphopenic" causes, a bit of a misnomer, as both often have low phosphorus.

Calcipenic rickets is more common and most frequently results from vitamin D deficiency.

Phosphopenic rickets is most often due to renal phosphate wasting.

Figure from Carpenter, T. Overview of rickets in children. Wolfsdorf, JI, ed. UpToDate. Waltham, MA: UpToDate Inc. https://www.uptodate.com (Accessed on April 23, 2019).

Shore RM & Chesney RW. Rickets: Part I. Pediatr. Radiol. (2013) 43: 140–151 at 142.

Discussion: vitamin D deficiency rickets and bone demineralization

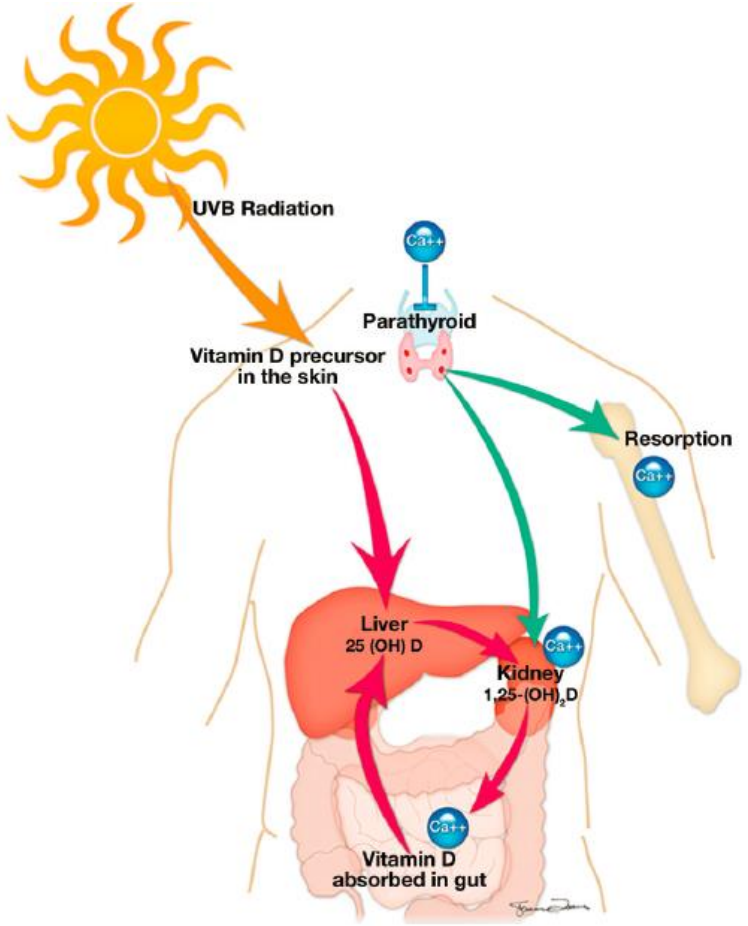

- In a low calcium state, parathyroid hormone levels increase and cause increased resorption of calcium from bone, leading to bone demineralization.
- Vitamin D enhances calcium absorption in the GI tract; thus, low vitamin D can lead to calcium deficiency.
- In patients (such as the patient in this case) with inadequate intake of calcium and vitamin D, effects are likely to be exacerbated.

Chang CY, Rosenthal DI, Mitchell DM, Handa A, Kattapuram SV, Huang AJ. Imaging Findings of Metabolic Bone Disease. RadioGraphics 2016; 36(6): 1871-1887 at 1874.

Discussion: three stages of rickets and radiographic findings

- Changes of rickets classically divided into three stages:
  - Stage I: radiographically silent with hypocalcemia and possible seizures, response of hyperparathyroidism, and resorption of calcium from bone
  - Stage II: radiographic evidence of rickets appears with physeal changes
    - return of normocalcemia with elevated PTH, elevated alkaline phosphatase and hypophosphatemia
  - Stage III: hypocalcemia, increased hyperparathyroidism, and overt clinical and radiographic manifestations of rickets

Shore RM & Chesney RW. Rickets: Part II. Pediatr Radiol (2013) 43:152–172 at 153.

Discussion: active and healing radiographic changes

Table 2: Radiographic Findings of Rickets

Body Part	Active Rickets	Healing Rickets
Extremity	Widened growth plate; irregularity and osteopenia along metaphyseal side of growth plate; flared, frayed, or fractured metaphysis; bowing; fracture	Widened growth plate (especially distal femoral), mild metaphyseal cupping, sclerosis along metaphyseal side of growth plate, bowing
Chest	Rachitic rosary, bell-shaped thorax	…
Skull	Flat occiput, widened sutures, squared appearance of skull, basilar invagination	…

Chang CY, Rosenthal DI, Mitchell DM, Handa A, Kattapuram SV, Huang AJ. Imaging Findings of Metabolic Bone Disease. RadioGraphics 2016; 36(6): 1871-1887 at 1875.

In this case, the patient had manifestations of active rickets at presentation and shortly before discharge (rachitic rosary) but was also beginning to show signs of healing rickets in the long bones.

Discussion: physeal changes in rickets

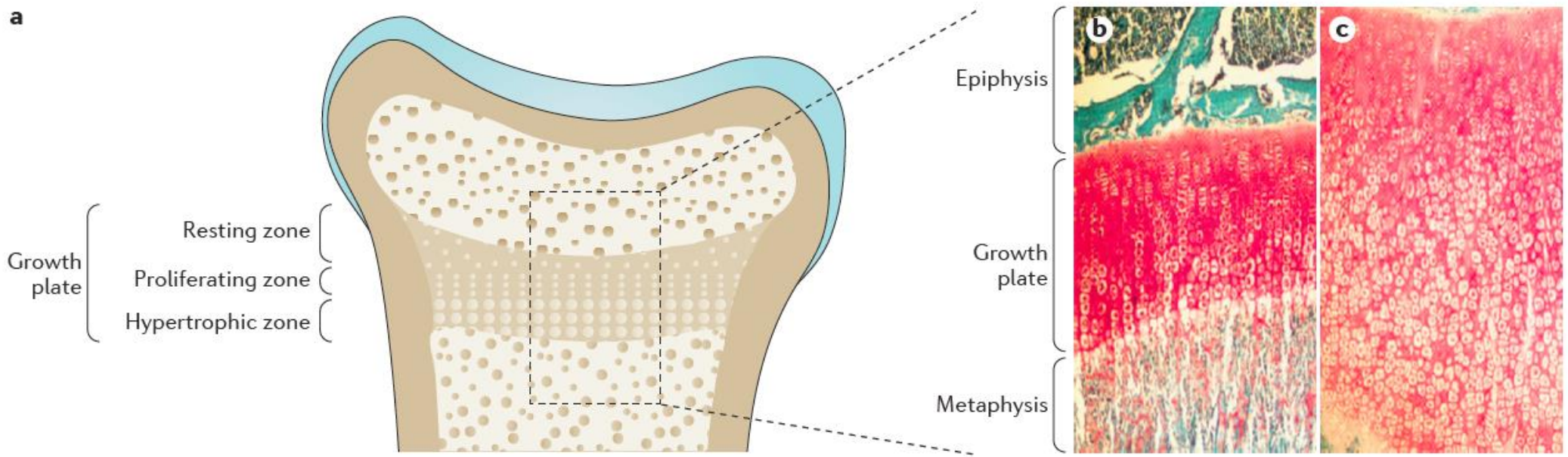

Carpenter TO, Shaw NJ, Portale AA, Ward LM, Abrams SA, Pettifor JM. Rickets. Nature Reviews 2017;4(17101):1-20 at p. 2, Fig. 1.

Normal growth plate

Rachitic growth plate with hypertrophic chondrocytes

Physeal abnormalities of rickets result from inability of chondrocytes to undergo phosphate-dependent apoptosis and poor mineralization.

Wrap-up

- Vitamin D deficiency is the most common cause of rickets in the U.S. and should be considered in children with failure to thrive/malnutrition and/or regression of developmental milestones.
- Early rickets is frequently clinically and radiographically silent.
- Radiographic changes of active rickets include fractures, osteopenia, metaphyseal fraying or flaring, and rachitic rosary. All were diagnosed in this patient.

References

- Carpenter TO, Shaw NJ, Portale AA, Ward LM, Abrams SA, Pettifor JM. Rickets. Nature Reviews 2017;4(17101):1-20.
- Carpenter, T. Overview of rickets in children. Wolfsdorf, JI, **ed.** UpToDate. Waltham, MA: UpToDate Inc. https://www.uptodate.com (Accessed on April 23, 2019).
- Chang CY, Rosenthal DI, Mitchell DM, Handa A, Kattapuram SV, Huang AJ. Imaging Findings of Metabolic Bone Disease. RadioGraphics 2016; 36(6): 1871-1887.
- Shore RM & Chesney RW. Rickets: Part I. Pediatr Radiol (2013) 43: 140–151.
- Shore RM & Chesney RW. Rickets: Part II. Pediatr Radiol (2013) 43:152–172.