RADY 401 Case Presentation

Kristen Blanton

June 2019

UNC SCHOOL OF MEDICINE
Radiology

Focused patient history and workup

Initial Presentation

2-year-old male presents to PCP with abdominal distension and 6-8 episodes of diarrhea daily for the last year. No significant medical history.

1 Week later

Presents with vomiting, lethargy, and 4 lb weight loss

→ Admitted for dehydration and hypokalemia

→ **Abdominal x-ray** shows dilated bowel

→ **Contrast enema** yields distended colon without fecal material. Rectal biopsy negative for Hirschsprung disease

Continued patient workup

3 Weeks later

Continues to have problems feeding and failure to thrive

→ GI surgery team attempts to place G-tube and discovers "peach"-sized mass in the retroperitoneum.

→ CT Abdomen Pelvis with IV contrast

→ FDG-PET scan with CT

→Bone marrow and mass biopsy negative

4 Weeks later

Suspect neuroblastoma

→Biopsy confirms diagnosis (but it is not neuroblastoma)

List of imaging studies

- Abdominal radiograph
- Contrast enema (not pictured)
- CT Abdomen and Pelvis with IV Contrast
- FDG-PET Scan with CT

Abdominal radiograph

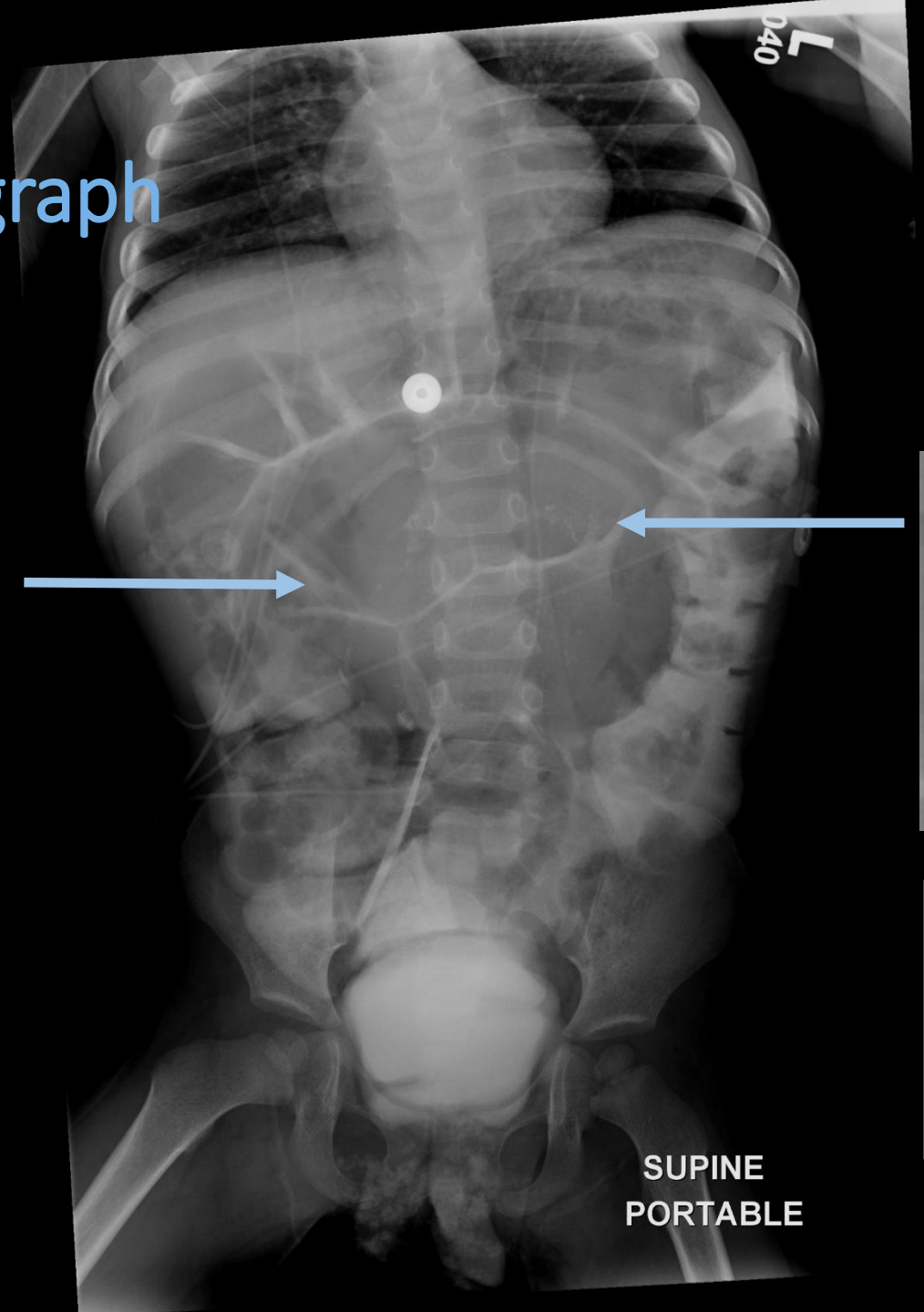

Dilated Bowel Loops

Calcifications

Note: We can see contrast in the descending colon and sigmoid colon. This is likely from a prior study.

CT Abdomen and Pelvis with IV Contrast

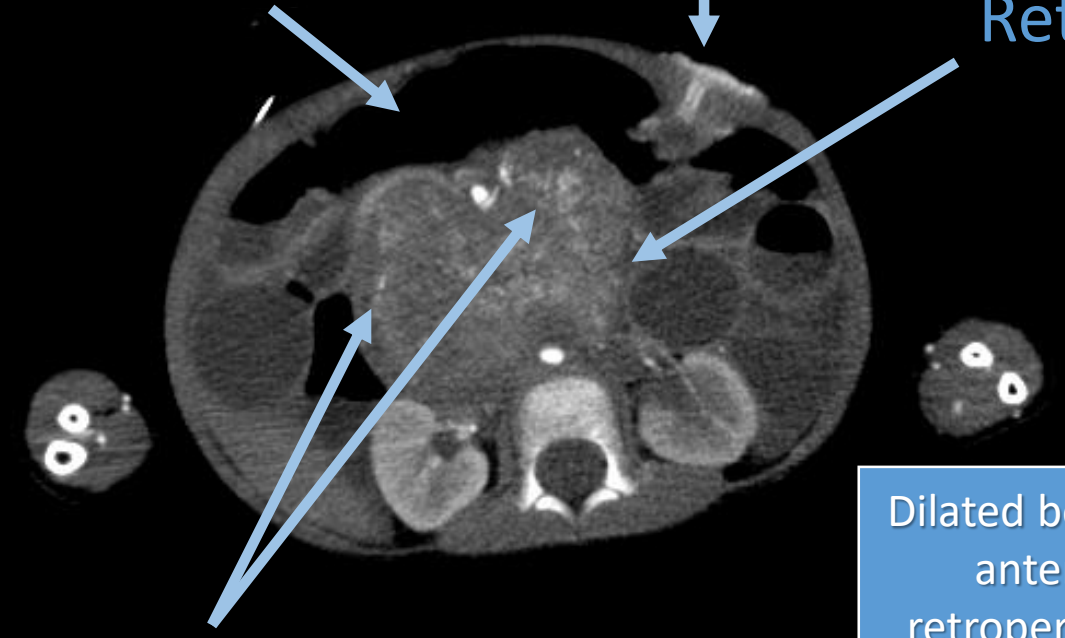

Dilated bowel loops are anterior to the retroperitoneal mass. Calcifications are more readily seen (than on the plain radiograph).

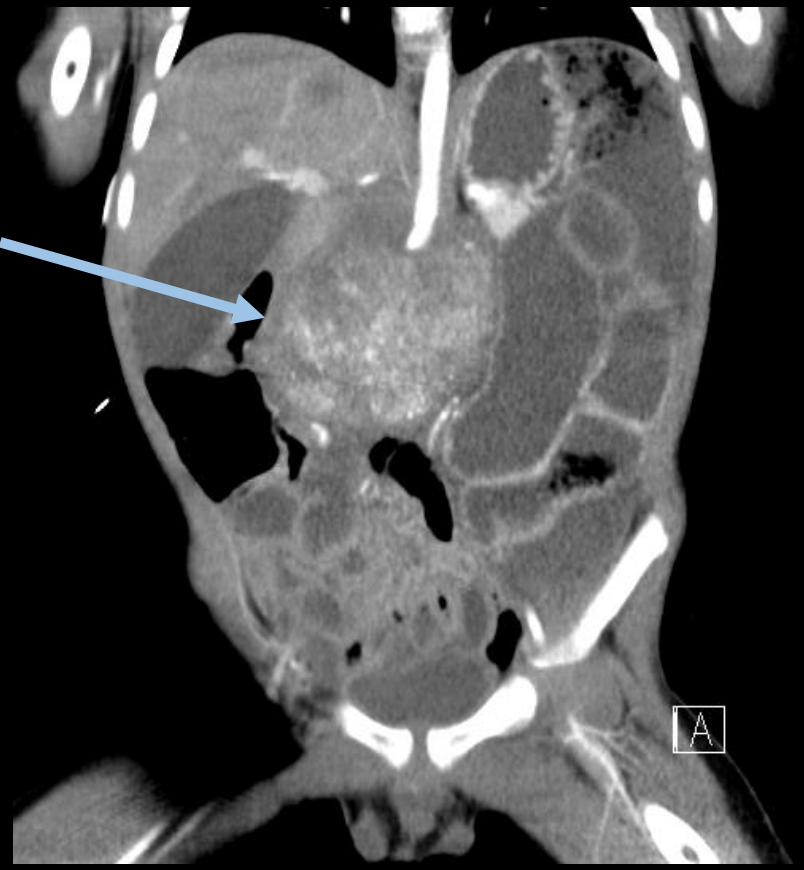

PET with CT Scan

Sparing of the vessels

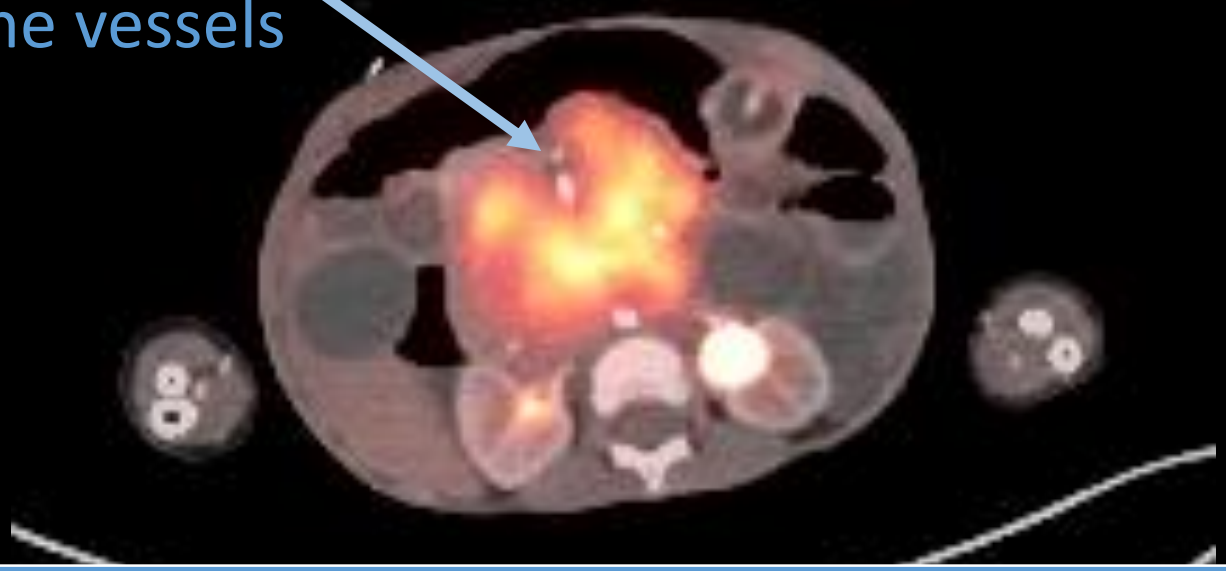

Avid uptake of the retroperitoneal mass with sparing of the SMA and descending aorta together suggest that the mass may be folding around important structures as opposed to invasive growth.

Adrenals with low uptake

Intact adrenal glands with low uptake bilaterally suggest that this is NOT the primary tumor source.

Uptake of the kidneys, bladder, brain and liver are all normal in this case.

Neuroblastic Tumors

- Neuroblasts are immature sympathetic cells of neural crest origin which differentiate into ganglion and Schwann cells
- More often found in children and more often malignant
- Locations: adrenal gland, retroperitoneum and posterior mediastinum
- Symptoms: Pain, abdominal distension, wt. loss and neuro deficits
- Radiological findings: heterogeneous mass +/- calcifications



Staging of Neuroblastic Tumors

INRG SS

Assessment made prior to surgery

Stage	Description
L1	Local tumor with IDRF = 0
L2	Local tumor with IDRF ≥ 1
M	Mets anywhere
MS	Mets to skin, liver or BM (< 18 mo)

***IDRF = Image Defined Risk Factors**

Bone marrow biopsy and PET scan were negative for distant metastasis so this case is likely grade L2 given the radiologic findings.

Table 1A. IDRF – Image Defined Risk Factors in neuroblastic tumors

Ipsilateral tumor extension within two body compartments:	Neck-chest, chest-abdomen, abdomen-pelvis
Neck:	Tumor encasing carotid and/or vertebral artery and/or internal jugular vein Tumor extending to base of skull Tumor compressing the trachea
Cervico-thoracic junction:	Tumor encasing brachial plexus roots Tumor encasing subclavian vessels and/or vertebral and/or carotid artery Tumor compressing the trachea
Thorax:	Tumor encasing the aorta and/or major branches Tumor compressing the trachea and/or principal bronchi Lower mediastinal tumor, infiltrating the costo-vertebral junction between T9 and T12
Thoraco-abdominal:	Tumor encasing the aorta and/or vena cava
Abdomen/pelvis:	Tumor infiltrating the porta hepatis and/or the hepatoduodenal ligament Tumor encasing branches of the superior mesenteric artery at the mesenteric root Tumor encasing the origin of the coeliac axis, and/or of the superior mesenteric artery Tumor invading one or both renal pedicles Tumor encasing the aorta and/or vena cava Tumor encasing the iliac vessels Pelvic tumor crossing the sciatic notch
Infiltration of adjacent organs/structures:	Pericardium, diaphragm, kidney, liver, duodeno-pancreatic block and mesentery

Table 1B. Conditions to be recorded, but NOT considered IDRFs:

Multifocal primary tumors
Intraspinal tumors (with or without symptoms of spinal cord compression. For staging of patients with intraspinal tumors: see text)
Pleural effusion (with or without malignant cells)
Ascites (with or without malignant cells)

Patient treatment

- Biopsy confirms ganglioneuroma
- Patient awaits excision of mass

Standard Treatment and Prognosis for Neuroblastic Tumors

Neuroblastic Tumor Subtype	Cells	Prognosis	Treatment
Neuroblastoma	Immature (malignant)	Poor	Surgery and chemo +/- bone marrow transplant
Ganglioneuroblastoma	Immature and mature (malignant)	Intermediate	Surgery and chemo
Ganglioneuroma	Mature (benign)	Excellent	Surgery

Imaging discussion

- Initial abdominal radiograph – appropriate
  - To evaluate for suspected small bowel obstruction in a child while minimizing radiation exposure
- Contrast enema (water soluble) – appropriate
  - To evaluate for distal bowel obstruction in child
  - R/o appendicitis, hirschsprung's, meconium plug, atresia (or f/u if still suspected)
- CT Abdomen and Pelvis with Contrast – appropriate
  - To evaluate the retroperitoneal mass (suspected Neuroblastoma)
- PET scan – appropriate
  - To identify tumor location. Alternatively could have used MIBG (rather than FDG) tracer

Approximate Cost of Imaging Studies

Imaging	Radiation exposure*	Cost
Abdominal x-ray	0.7 mSv	$23 - $380
Contrast enema with Fluoro	8 mSv	$242 - $620
CT Abdomen and Pelvis	10 mSv	$889 - $4,050
PET scan with CT	up to 25 mSv	$1,526 - $3,738

*Exposure is approximated for an adult.

Imaging discussion for MIBG-PET Scan

- ^{123}Iodine metaiodobenzyl guanidine (^{123}I-MIBG) is used for diagnostic workup of neuroblastoma
  - MIBG, an analog of norepinephrine (NE), is taken up by NE transporters and accumulates in cells.
  - > 90% of NB are MIBG avid; however, other tumors can have this uptake pattern (e.g. NB, GNB, GN, pheo, carcinoid, medullary thyroid). This means MIBG cannot definitively differentiate among these tumors.
- Sensitivity (90%) and Specificity (88%) for neuroblastoma, but MIBG uptake is variable for ganglioneuroma.
- Regardless of the tracer used, confirm via primary biopsy, bone marrow biopsy or catecholamine metabolites.

UNC Top Three

- With the presence of heterogeneous mass in the adrenal glands, retroperitoneum, or posterior mediastinum (especially in a child), suspect neuroblastic tumor.
- Ganglioneuroma is a rare but benign tumor that presents similarly to neuroblastoma.
- ^{123}I-MIBG can be used to identify various tumors of neural crest origin (NE uptake), but particularly neuroblastoma.

References

Monclair T, Brodeur GM, Ambros PF, et al. The International Neuroblastoma Risk Group (INRG) staging system: An INRG Task Force report. *J Clin Oncol*. 2009;27(2):298-303. doi:10.1200/JCO.2008.16.6876

G.M. B, J. P, F. B, et al. Revisions of the international criteria for neuroblastoma diagnosis, staging, and response to treatment. *J Clin Oncol*. 1993;11(8):1466-1477.

Murphey MD, Carroll JF, Flemming DJ, Kransdorf MJ. From the Archives of the AFIP OBJECTIVES. *RadioGraphics*. 2004;24:1433-1466.

Decarolis B, Simon T, Krug B, et al. Treatment and outcome of Ganglioneuroma and Ganglioneuroblastoma intermixed. *BMC Cancer*. 2016;16(1):1-12. doi:10.1186/s12885-016-2513-9

College of Radiology A. ACR-SPR practice guideline for the performance of pediatric fluoroscopic contrast enema examinations. In: Practice guidelines & technical standards 1997. Revision 2016. 2016;1076(Revised 2008):1-14.

Shohet, MD,PhD, Nuchtern, MD. Clinical Presentation, Diagnosis and Staging Evaluation of Neuroblastoma. Post TW, ed. UpToDate. Waltham, MA: UpToDate Inc. https://www.uptodate.com/contents/epidemiology-pathogenesis-and-pathology-of-neuroblastoma?search=neuroblastoma&source=search_result&selectedTitle=3~122&usage_type=default&display_rank=3 Accessed on June 16, 2017.

Consumer Fair Price Search. Healthcare Bluebook website. https://www.healthcarebluebook.com/ui/consumerfront. Accessed June 16, 2019.

Radiation Exposure from Medical Exams and Procedures. Health Physics Society, Specialists in Radiation Safety website. http://hps.org/documents/Medical_Exposures_Fact_Sheet.pdf. Updated January 2010. Accessed June 16, 2019.