RADY 403 Case Presentation:
Vascular Rings - Double Aortic Arch

Katie Butler, MS4
July 2018

Ed. John Lilly, MD

UNC SCHOOL OF MEDICINE Radiology

History and Workup

- Post-term BB born via SVD with initial Apgars of 4 and 5
  - required PPV due to excessive secretions
- Transferred to local NICU at 21 hours of life for **biphasic** stridor, increased WOB, and wheezing
- Transferred to UNC NICU on day 4 of life after multiple oxygen desaturations, worse with feeding
  - Treated with broad spectrum abx, sepsis workup negative
  - DDx: laryngomalacia or compression
  - Consults: Pediatric ENT, Pediatric Pulmonology

History and Workup

- Post-term BB born via SVD with initial Ap
  - required PPV due to excessive secretion
- Transferred to local NICU at 21 hours of lif increased WOB, and wheezing
- Transferred to UNC NICU on day 4 of life a desaturations, worse with feeding
  - Treated with broad spectrum abx, sepsi
  - DDx: laryngomalacia or compression
  - Consults: Pediatric ENT, Pediatric Pulm

Differential for stridor in a newborn

compression: vascular rings, bronchogenic cyst, mediastinal mass, Marfan Syndrome (enlargement of the ascending aorta), enlargement of the pulmonary artery (congenital absence of the pulmonary valve), malpositioning of the descending aorta (midline descending aorta-carina-compression syndrome), enlargement of the left atrium, narrow thoracic inlet. These result in airway compression from congenital problem

intrinsic malacia: from long term nature of compression (which can cause persistent symptoms even after airway decompressed extrinsically)

Timeline of imaging studies

- Day 1 of life
  - CXR
- Day 5 of life
  - Echocardiogram
  - Barium Swallow
- Day 6 of life
  - Repeat Echocardiogram
  - Modified Barium Swallow Study
- Day 7 of life
  - CTA

Imaging studies - Plain Chest Radiograph

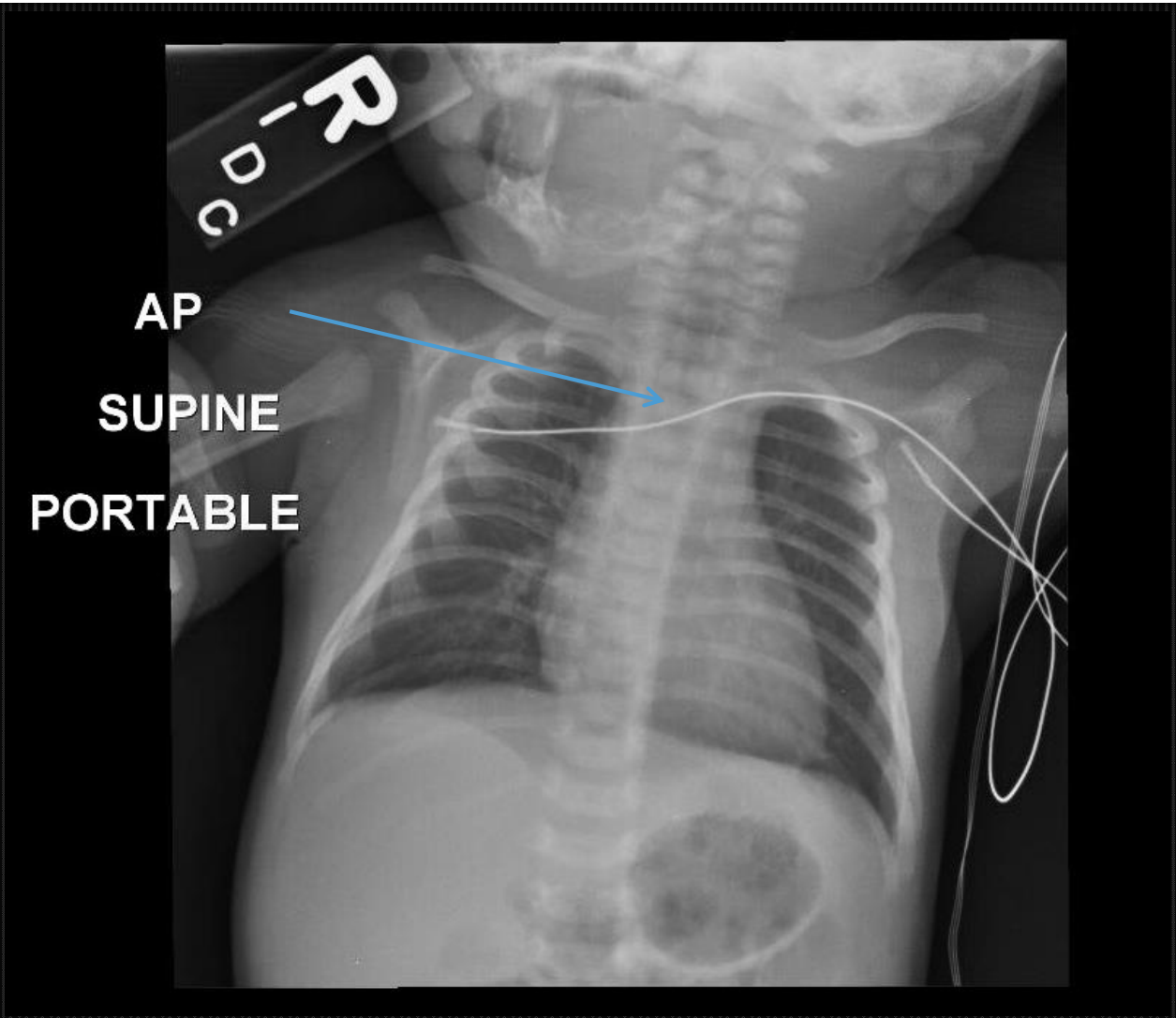

Findings:
- Slight tracheal deviation to the left
- Otherwise, unremarkable

Imaging studies - Barium Swallow

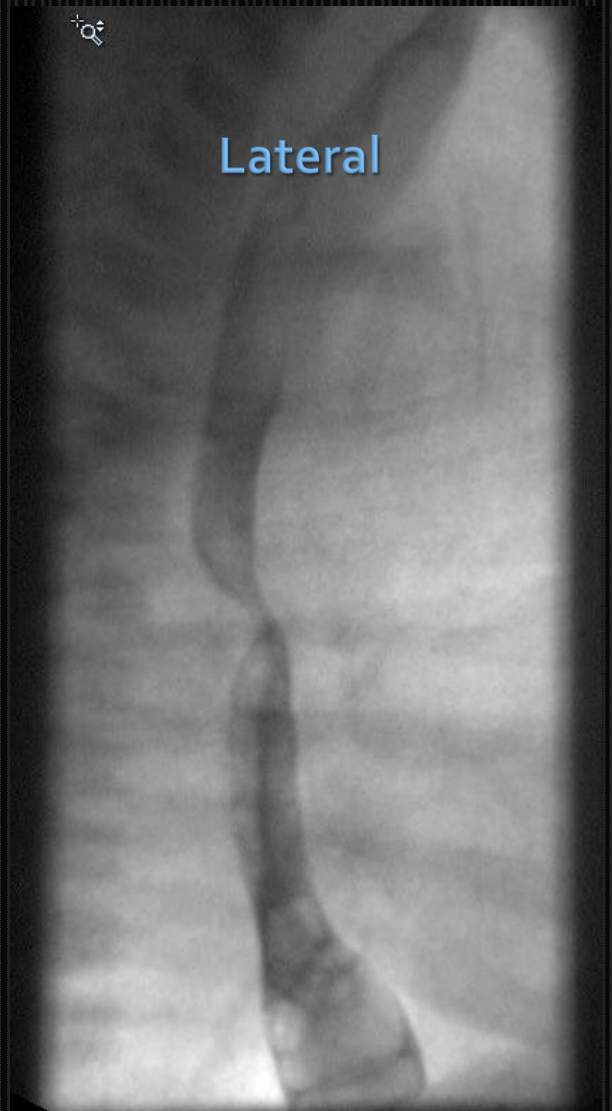

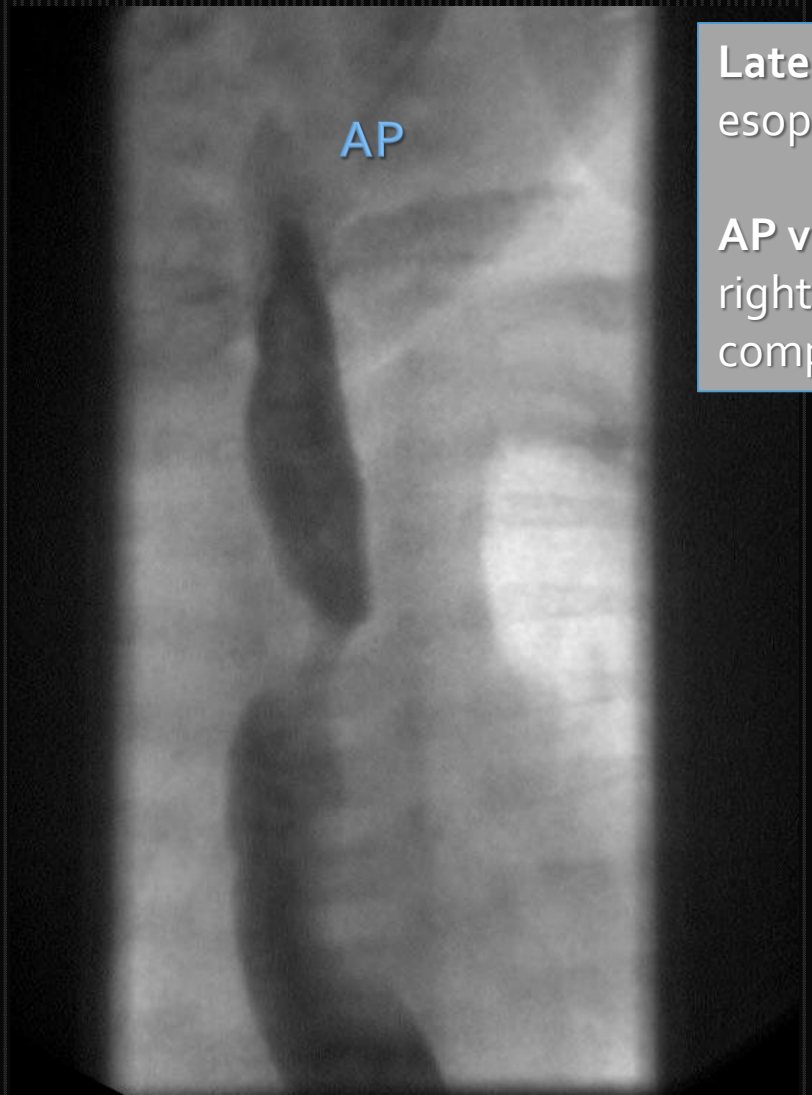

Lateral view: posterior narrowing of the esophagus

AP view: esophageal narrowing again noted, right sided compression superior to left sided compression

Imaging studies - CTA

Axial CTA images – with IV contrast from thoracic inlet to hemidiaphgrams, 2mm slices

- Double aortic arch with more dominant right arch
- Narrowing at the distal trachea

Superior

Inferior

Imaging studies - CTA

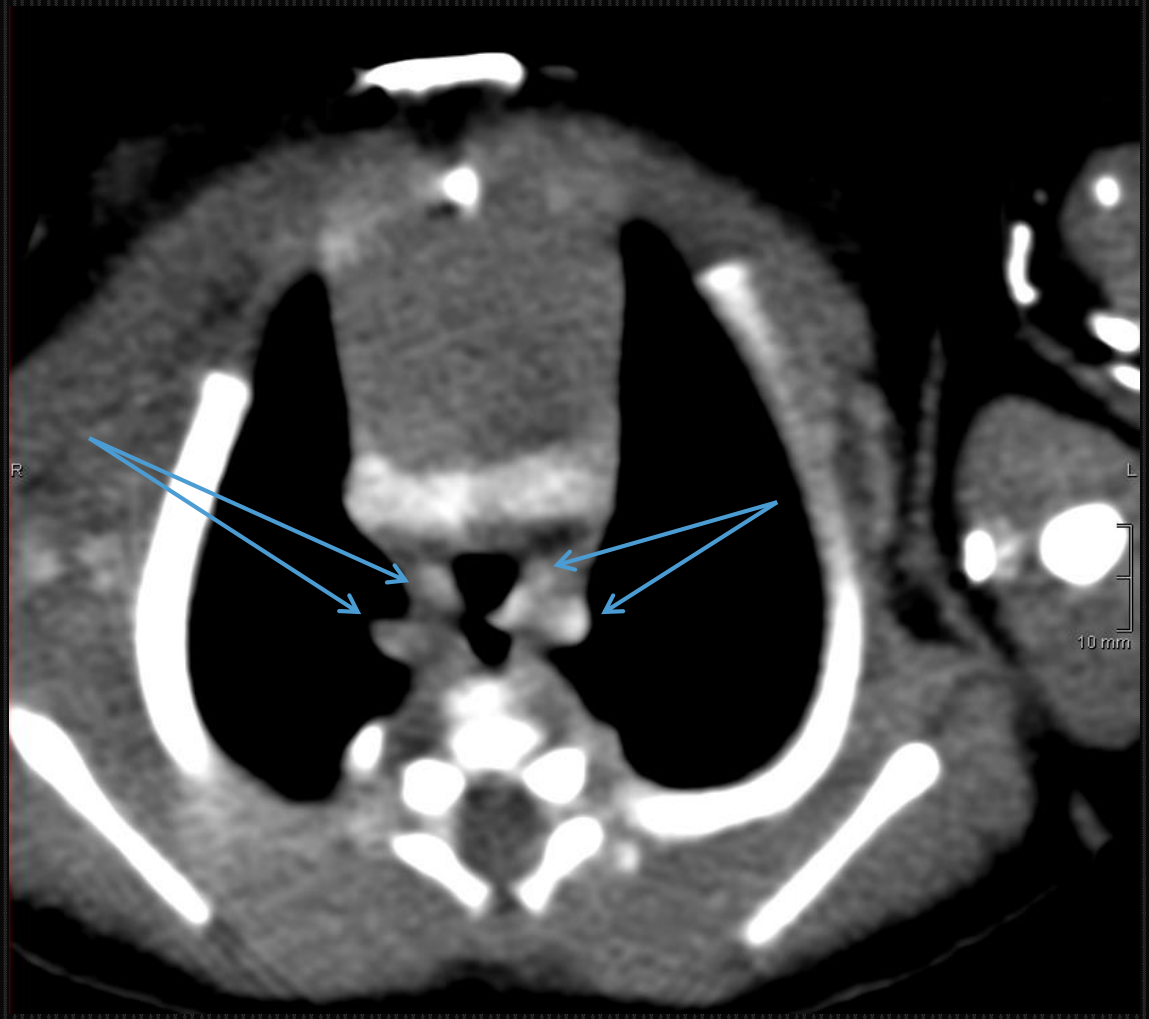

Axial image

- Left common carotid and left subclavian originate from left arch
- Right common carotid and right subclavian originate from dominant right arch

Imaging studies - CTA

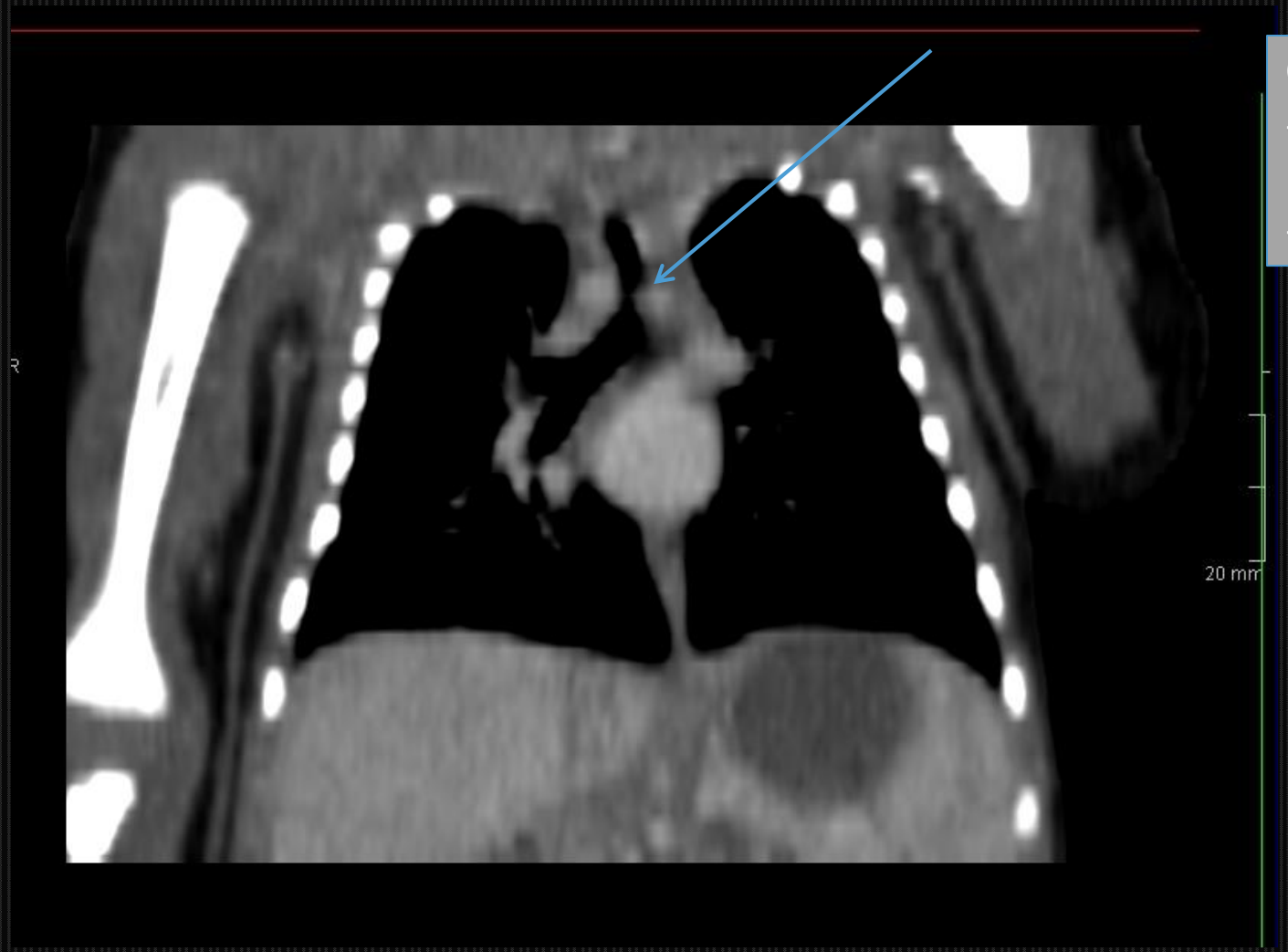

Coronal Image

- Marked narrowing at the trachea from double aortic arch
- Right arch slightly more superior

Imaging studies - Chest X-Ray (Post-Op)

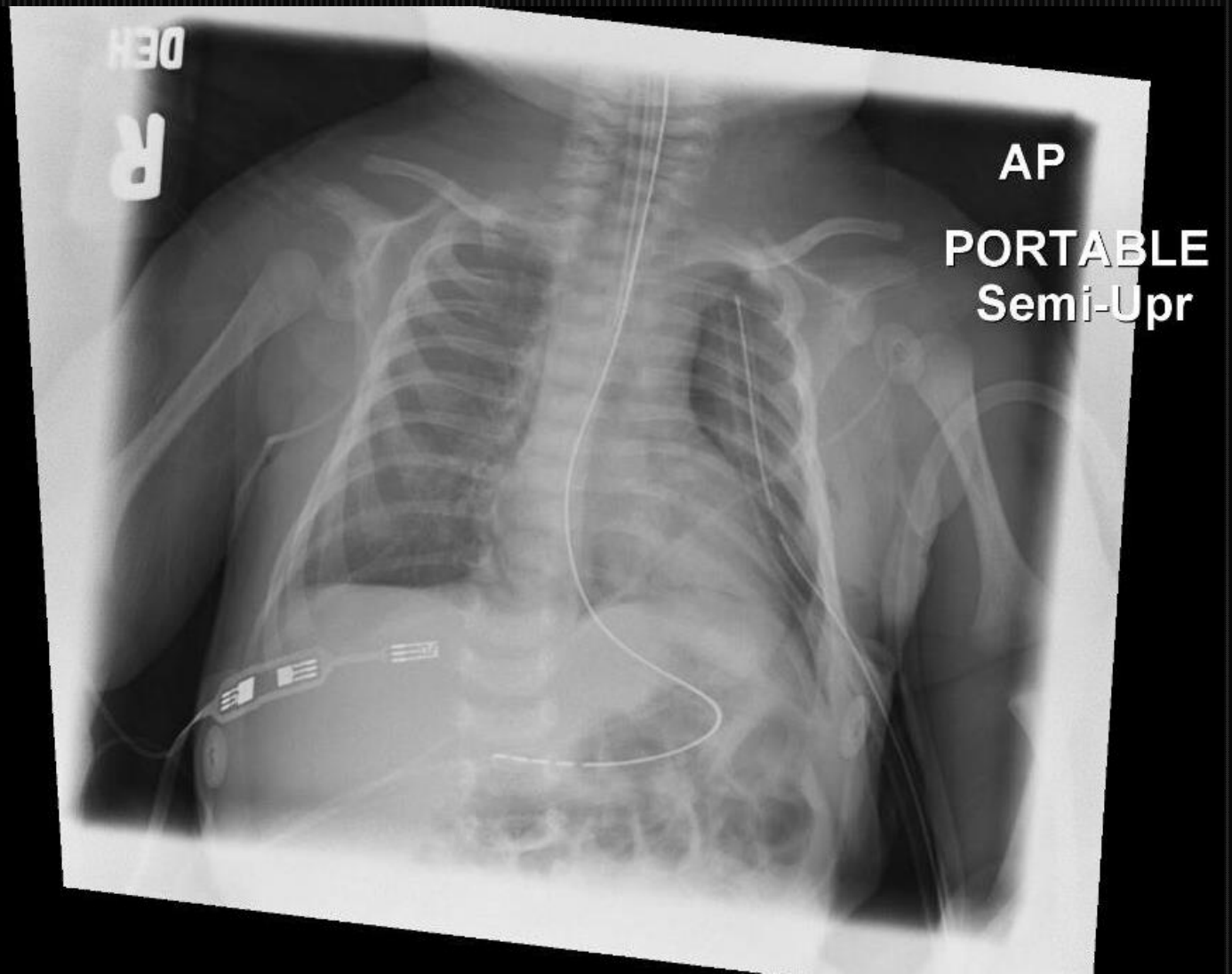

Findings: s/p left lateral thoracotomy

- Left-sided chest tube
- Trace subcutaneous emphysema on the left
- Medial pneumothorax
- Enteric tube courses below diaphragm
- ET tube above the carina

Patient treatment or outcome

- Day 7 of life: CTA showed definitive findings of vascular ring secondary to right dominant double aortic arch
- Day 8 of life: Pediatric CT Surgery
  - Division of vascular ring and PDA ligation
- PICU course complicated by tracheomalacia with reactive component, remained intubated for 2 weeks and improved with steroids and inhaled B2 agonists
- Readmitted around 10 weeks of age for persistent tracheomalacia and respiratory failure secondary to parainfluenza
  - Re-intubated, underwent tracheostomy, and now on minimal vent settings but with unsuccessful trach collar trials to date

Imaging studies - Chest X-Ray (age 12 weeks)

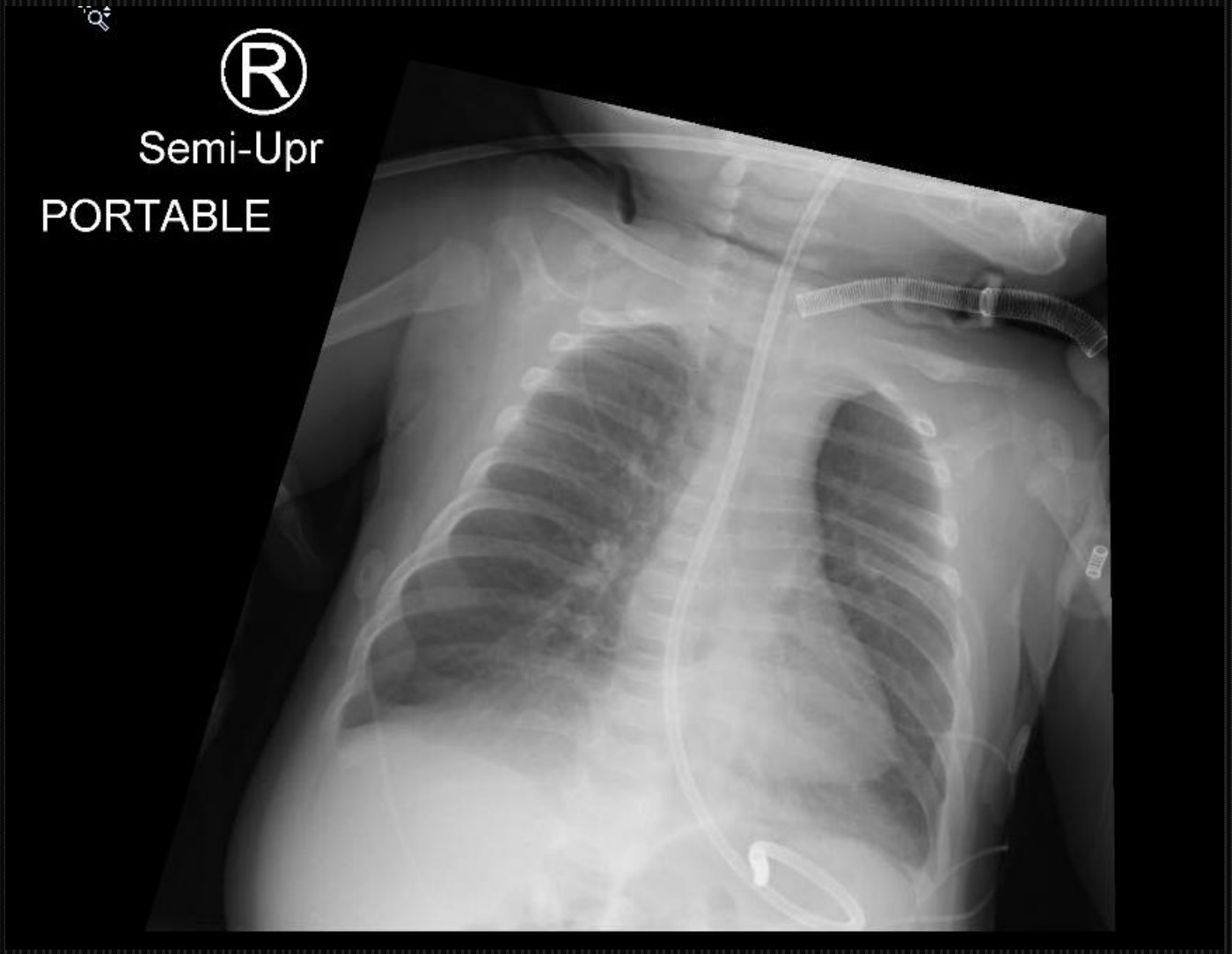

Findings: s/p tracheostomy

- Tracheostomy cannula, proximal location likely due to head positioning
- Trace bilateral pleural effusions
- Left > right basilar streaky opacities consistent with atelectasis

Discussion - Vascular Rings

- Double Aortic Arch
  - Congenital anomaly – persistence of left and right 4th aortic arches
  - Most common vascular ring
  - Presents soon after birth
  - Compress trachea anteriorly and esophagus posteriorly
  - Right arch is usually dominant, more cephalad
  - Treatment: left thoracotomy with left arch ligation

Discussion - Vascular Rings

- Anomalous Origin of the Left Pulmonary Artery (Pulmonary Sling)
  - Left pulmonary artery arises from the right pulmonary artery
  - Asymmetric lung inflation on chest radiographs
- Right Aortic Arch with Aberrant Left Subclavian Artery
  - Persistent ductus ligament completing the ring, +/- midline descending aorta, Kommerell diverticulum (dilation subclavian artery)
- Innominate Artery Compression Syndrome
  - Innominate artery arises more to the left plus crowding from the thymus causes a spectrum of tracheal compression from mild to severe
  - Lateral radiographs show indentation of the anterior aspect of the trachea at the level of thoracic inlet

Discussion - Imaging Workup for Vascular Rings

- Plain Chest Radiograph: 1st study with PA and lateral views
- Echo: identify other cardiac lesions, syndromes
- Barium Swallow: replaced by CTA or MRA

- CTA (cost: $259-$1800+) versus MRA (cost: $566 - $3291): best at assessing the vascular anatomy
  - CTA: approximate effective radiation dose - 12 mSv, comparable to natural background radiation - 4 years
  - Risk of radiation versus risk of sedation/anesthesia

References

- Donnelly, Lane F. *Fundamentals of Pediatric Radiology*. 2nd ed., Elsevier, 2016.
- Shah RK, Mora BN, Bacha E, et al. The presentation and management of vascular rings: an otolaryngology perspective. Int J Pediatr Otorhiolaryngol 2007; 71:57.
- Radiological Society of North America, et al. "Patient Safety - Radiation Dose in X-Ray and CT Exams." *Patient Safety*, www.radiologyinfo.org/en/info.cfm?pg=safety-xray.