RADY 401 Case Presentation

Samuel Wurzelmann MS3

June 2018

Ed. John Lilly, MD

UNC SCHOOL OF MEDICINE Radiology

Focused patient history and workup

- 69 yo male with PMH Benign Prostatic Hypertrophy (BPH), HTN, DM, coronary angioplasty, and 1 year hx of urinary retention presents for prostate artery embolization (PAE)
- T 97.7F, BP 142/80, HR 88, SpO2 95%
- Pt previously failed trial of void (TOV), FLOMAX (tamsulosin), terazosin (both are alpha-1 blockers -> relax prostatic smooth muscle)
- Reliant on urinary catheter for 1 year
  - Episodes of hematuria and catheter trauma

Focused patient history and workup

- 69 yo male with PMH BPH, HTN, DM, and 1 year hx of urinary retention pres embolization (PAE)
- T 97.7F, BP 142/80, HR 88, SpO2 95%

Trial of Voids: measures bladder emptying -> fail if post-void residual >1/2*pre-void volume

Tamsulosin and Terazosin: alpha-1 blocker -> relaxes prostatic smooth muscle

- Pt previously failed trial of void (TOV), FLOMAX (tamsulosin), terazosin (both are alpha-1 blockers -> relax prostatic smooth muscle)
- Reliant on urinary catheter for 1 year
  - Episodes of hematuria and catheter trauma

List of imaging studies

- Imaging studies not recommended by American Urologic Association for diagnosing BPH[1]
  - Diagnosis is clinical
  - Can use transrectal or transabdominal US to measure prostate volume[2]
- CT urography to evaluate hematuria
  - CT of abdomen and pelvis, with and without contrast
- Imaging during PAE: Ultrasound, Fluoroscopy

Imaging studies indicated by American College of Radiology

- Hematuria[3] (*rating; relative radiation level*):
  - CT abdomen and pelvis without and with IV contrast (*9; 4*)
- Suspected BPH with Lower Urinary Tract Symptoms[4]
  - US Pelvis (bladder and prostate) transabdominal (*6; 0*)
  - US Kidney retroperitoneal (*5; 0*)
  - MRI pelvis without IV contrast (*3; 0*)
  - X-ray intravenous urography (*2; 3*)

Clinical Condition: Hematuria

Variant3: All patients except those described in variant 1 or 2.

Radiologic Procedure	Rating	Comments	RRL*
CT abdomen and pelvis without and with IV contrast	9	CT urography. Must include high-resolution imaging during excretory phase.	☢☢☢☢
CT abdomen and pelvis without IV contrast	6		☢☢☢☢
X-ray retrograde pyelography	6	For patient with contraindication to iodinated contrast or strong suspicion of urothelial lesion, to clarify abnormality suspected on CT or IVU.	☢☢☢
CT abdomen and pelvis with IV contrast	5	This procedure may be appropriate but there was disagreement among panel members on the appropriateness rating as defined by the panel's median rating.	☢☢☢☢
US kidneys and bladder retroperitoneal	5		O
MRI abdomen and pelvis without and with IV contrast	5	MR cont	
MRI abdomen and pelvis without IV contrast	4		
Arteriography kidney	2		
X-ray abdomen and pelvis (KUB)	2		
X-ray intravenous urography	1		

Rating Scale: 1,2,3 Usually not appropriate; 4,5,6 May be appropriate; 7,8,9 Us

Clinical Condition: Lower Urinary Tract Symptoms: Suspicion of Benign Prostatic Hyperplasia

Radiologic Procedure	Rating	Comments	RRL*
US pelvis (bladder and prostate) transabdominal	6	Consider this procedure after patient voids to measure residual urine. If there is significant residual urine, an evaluation of upper tracts is indicated. This procedure gives an estimate of prostate size and bladder wall thickness. It can also measure intravesical prostate protrusion.	O
US kidney retroperitoneal	5	The appropriateness rating could be higher for this procedure if significant residual urine is present or if renal insufficiency is present to evaluate for hydronephrosis.	O
MRI pelvis without IV contrast	3	MRI can determine prostate size, urinary bladder wall thickness, and hydronephrosis.	O
X-ray intravenous urography	2	The appropriateness rating could be higher for this procedure if significant residual urine is present. In patients with stones, hematuria, or atypical history, the study may be warranted. CT urography has replaced IVU in some centers.	☢☢☢
MRI pelvis without and with IV contrast	2		O
Voiding cystourethrography	2	Consider this procedure in men younger than age 50 with symptoms.	☢☢
X-ray abdomen	2	Other imaging studies are more useful.	☢☢
US pelvis (prostate) transrectal	2	Resistive indices have been shown to be elevated in BPH and to decrease after transurethral vaporization of the prostate, suggesting that resistive indices can be used to evaluate severity of BPH and monitor therapy. This procedure can assess for intravesical prostate protrusion.	O
X-ray retrograde urethrography	1	This procedure does not assess prostate size.	☢☢☢
CT abdomen and pelvis without and with IV contrast	1		☢☢☢☢
CT abdomen and pelvis without IV contrast	1		☢☢☢☢
CT abdomen and pelvis with IV contrast	1		☢☢☢☢

Rating Scale: 1,2,3 Usually not appropriate; 4,5,6 May be appropriate; 7,8,9 Usually appropriate

*Relative Radiation Level

Imaging studies from PACS 1

- CT Urography; axial plane (9/2017)
- Findings?

Imaging studies from PACS 1

- CT Urography; axial plane (9/2017)
- Findings? enlarged prostate → estimated 350 gm
  - Average prostate size in grams = 11 gm; Large is considered > 50 gm [5]
  - No further imaging performed to measure prostate volume

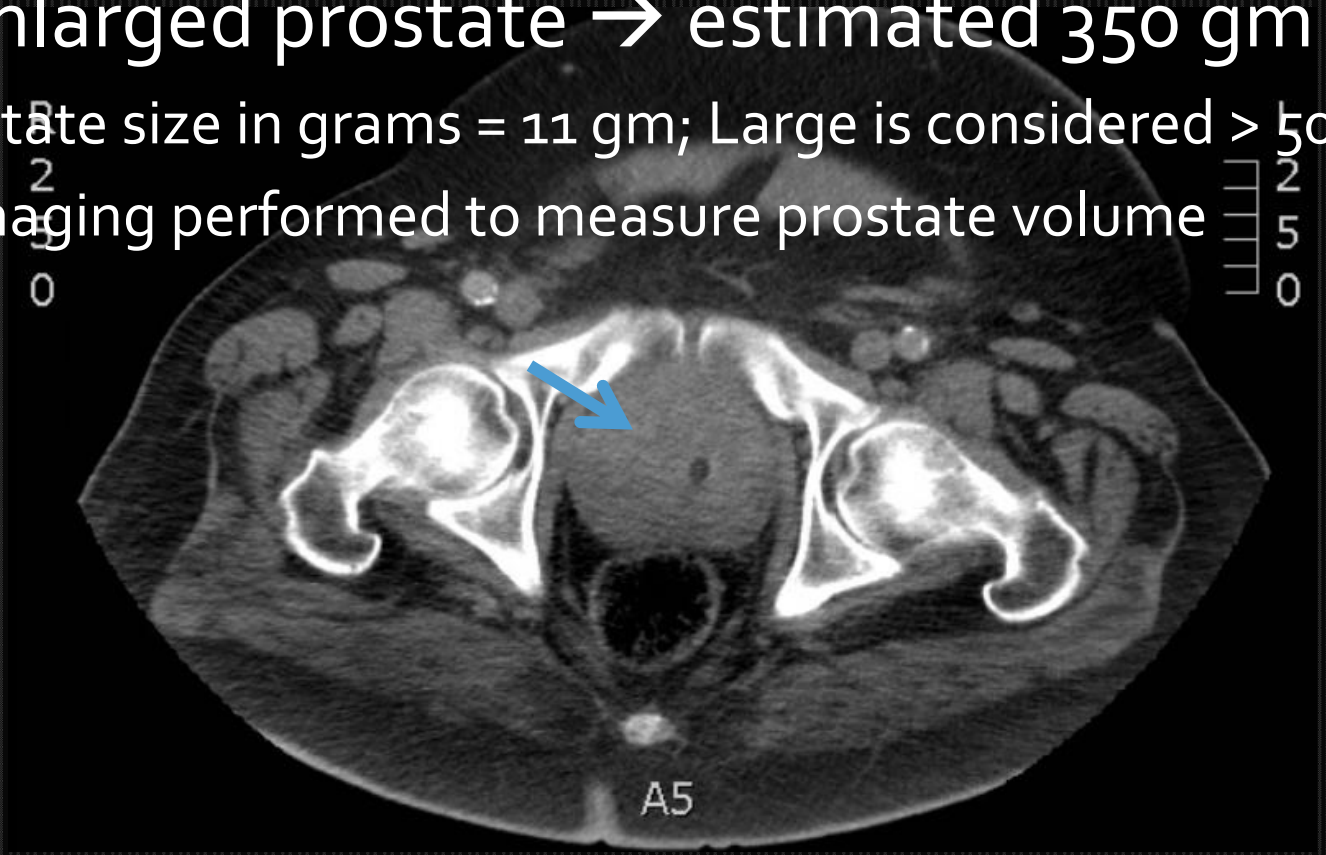

Patient treatment: Prostate Artery Embolization (PAE)

- PAE is treatment for refractory BPH
- Goal: Block vascular supply to prostate causing ischemic necrosis and subsequent volume reduction of prostate, thereby relieving urinary symptoms[6]
- Anatomy and vasculature[7]:

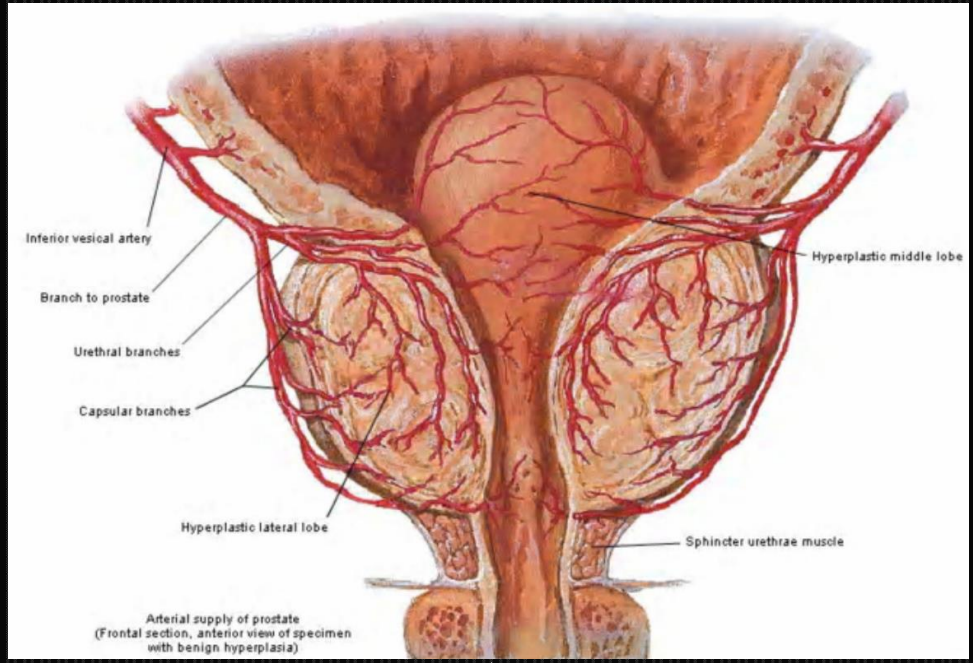

Patient treatment: Prostate Artery Embolization (PAE)

- Improvement compared to baseline in:
  - International Prostate Symptom Score (IPSS)
  - Maximal urinary flow (Qmax)
  - Quality of Life
  - Prostate volume
- Compared to transurethral resection of prostate (TURP) or open prostatectomy, PAE exhibits:
  - Decreased invasiveness and morbidity
  - PAE good option for poor surgical candidates
- In randomized comparative trials, PAE was considered inferior to TURP or prostatectomy in IPSS, Qmax, and prostate volume[7]

Patient treatment: The Procedure

- Diagnostic catheter enters left radial artery. Advances to right internal iliac artery.
- A J-tip Direxion microcatheter was inserted into right anterior lateral prostatic artery arising from vesicle-prostatic trunk.

- 100 mcg nitroglycerin injection for arterial dilation.
- Digital subtraction angiography (DSA) performed to determine optimal catheter position from embolization.

- Embolization performed with 100-300 micrometer Gel-Beads until stasis was achieved.

- Same procedure repeated on left side for left anterior lateral prostatic artery.

- 42.8 minutes total under fluoroscopy

Fluoroscopy and Procedure Diagrams

Fluoroscopy, with C-arm[8]: Real-time viewing of catheters and arterial blood flow, with use of contrast

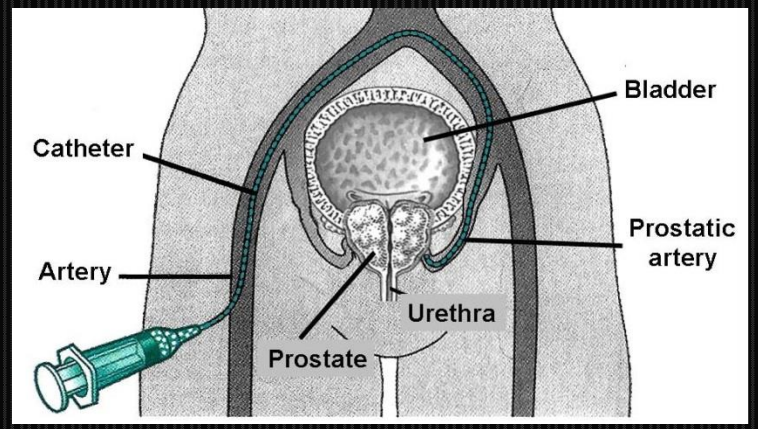

Prostatic Artery Embolization[9]: Minimally invasive

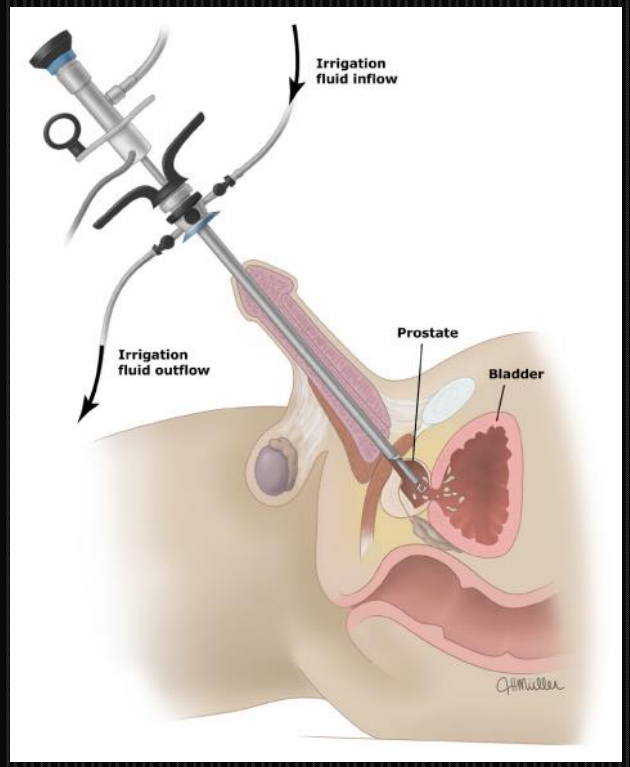

Standard surgery for BPH[10]: Transurethral Resection of the Prostate

Imaging studies from PACS 1

- Ultrasound: evaluation of left radial artery.
- Findings?

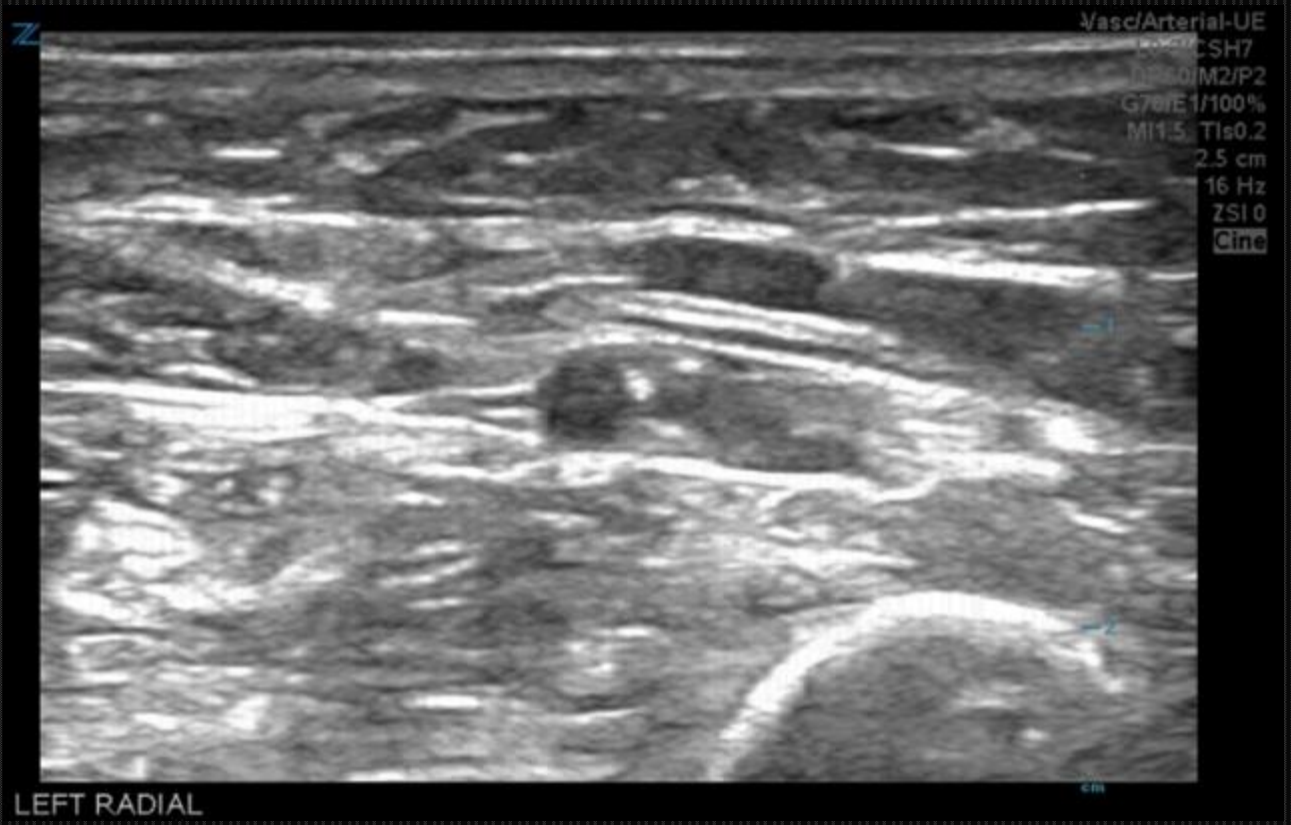

Imaging studies from PACS 2

- Ultrasound: evaluation of left radial artery.
- Findings? Patent radial artery, for initial catheter entry

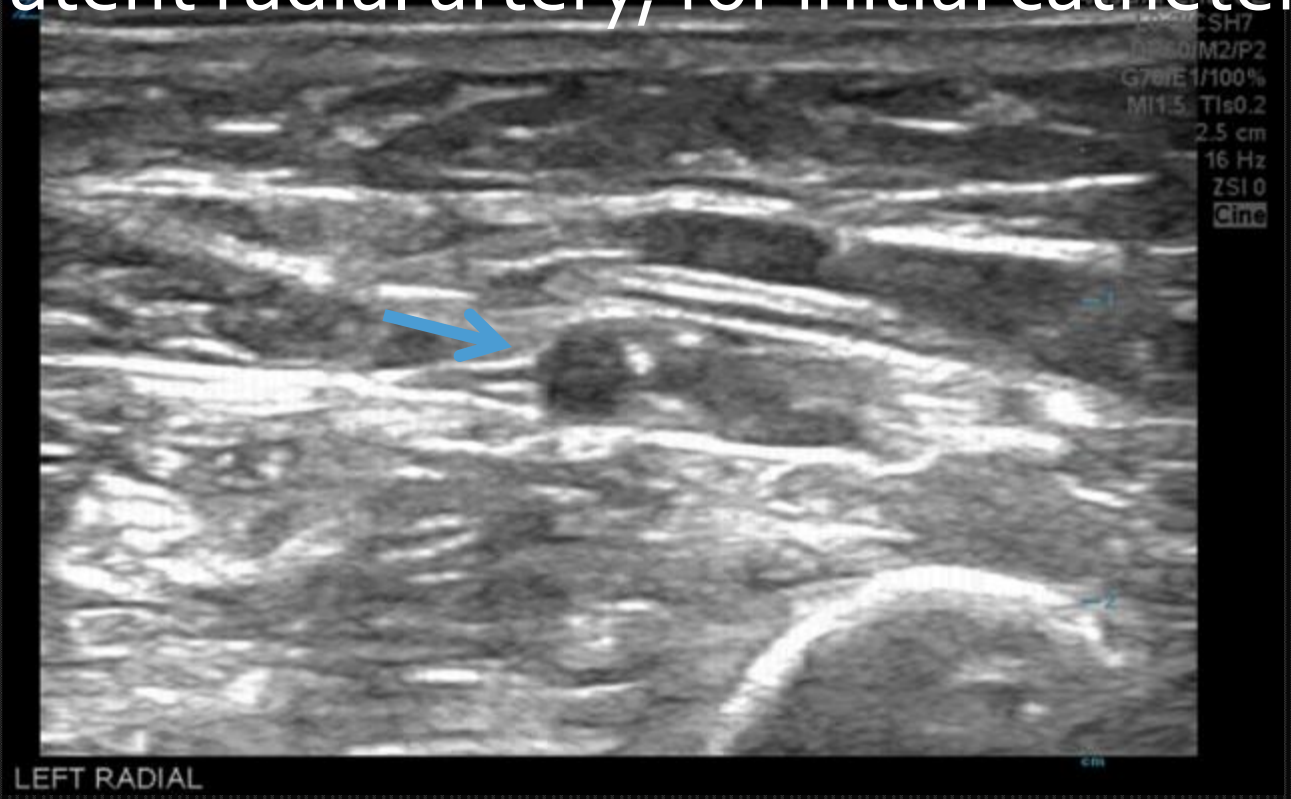

Imaging studies from PACS 3.a.

- Fluoroscopy: Right pelvis
- What do we see?

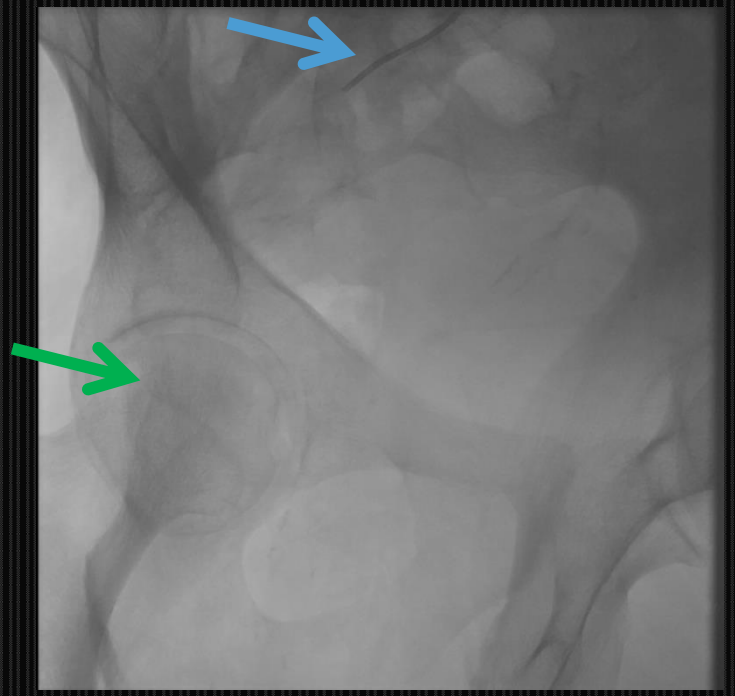

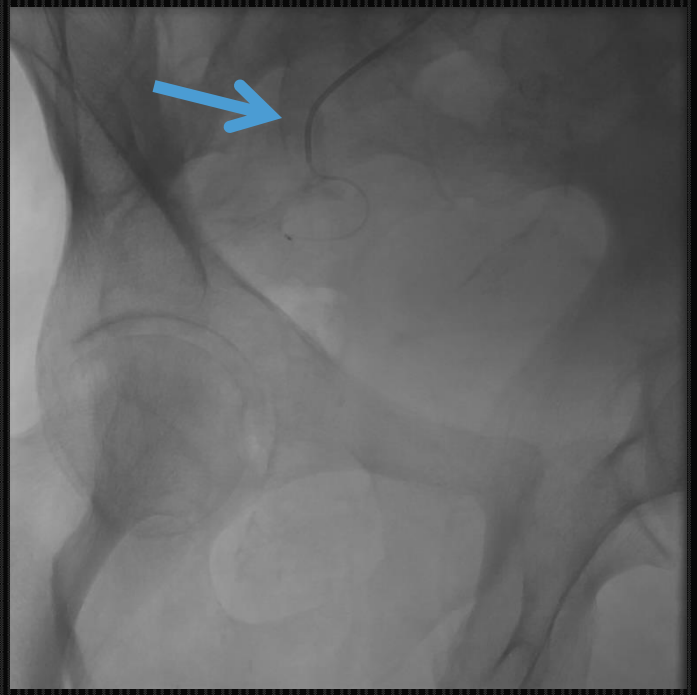

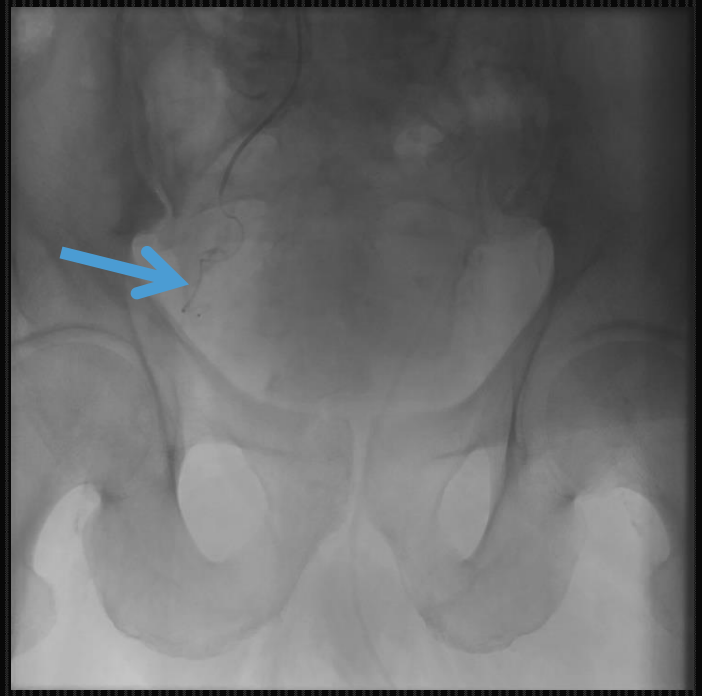

Imaging studies from PACS 3.a.

- Fluoroscopy: Right pelvis
- What do we see?

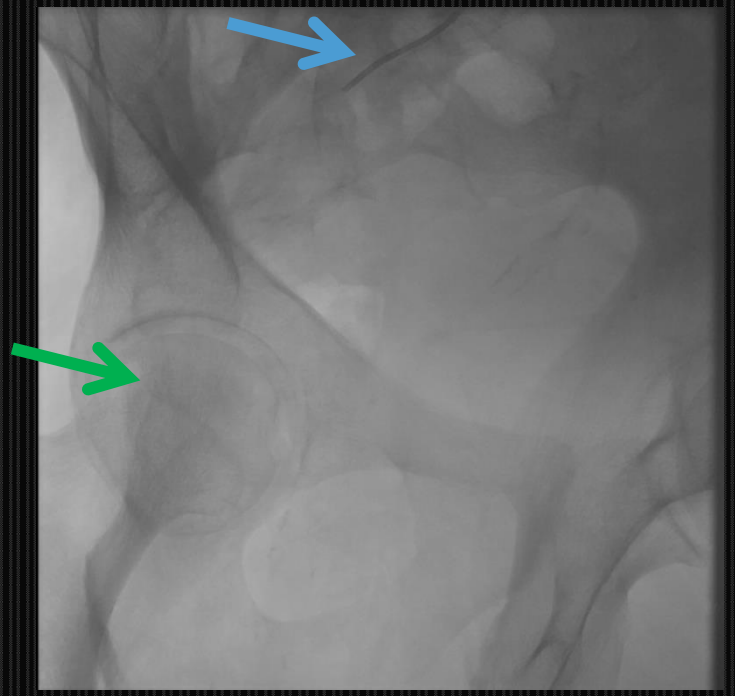

Catheter in common iliac artery (blue arrow).
Femoral head (green arrow).
Right anterior oblique angle.

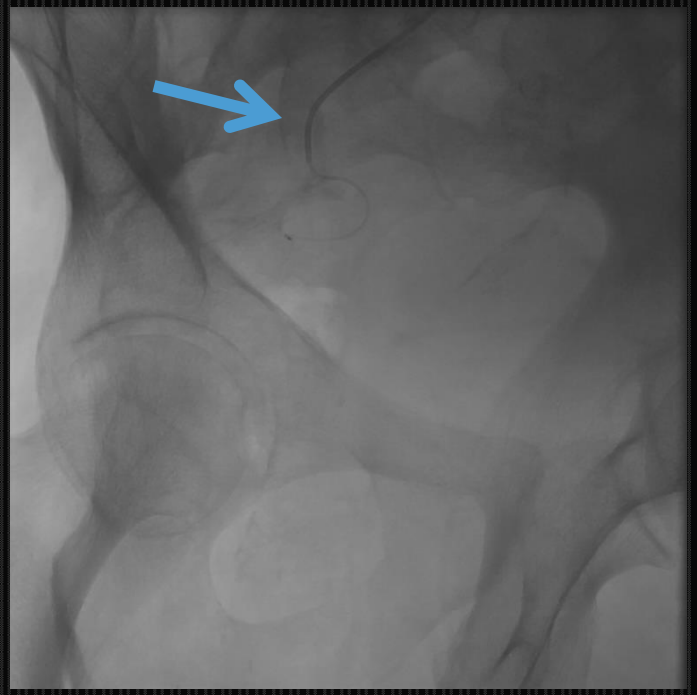

Catheter advancing to right internal iliac artery.
Right anterior oblique angle.

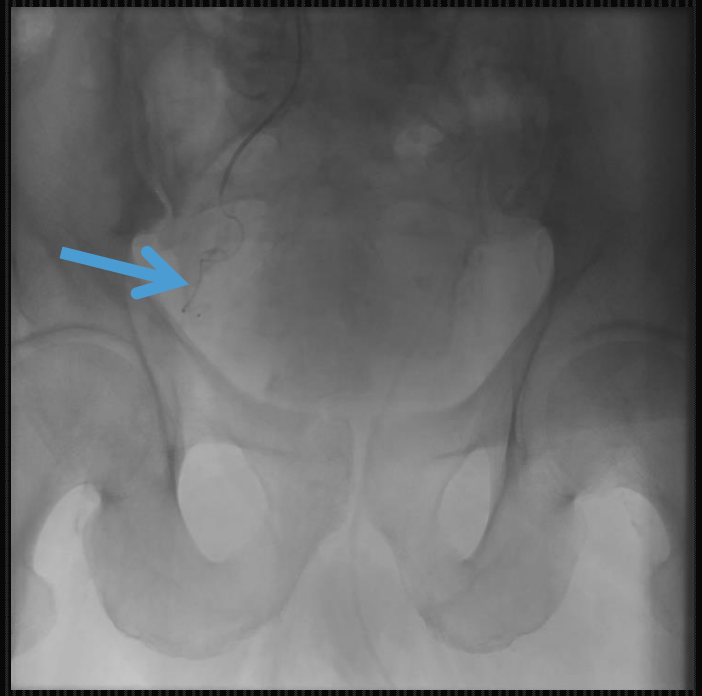

Catheter advancing to right inferior vesicular artery and prostatic artery.
Coronal plane.

UNC SCHOOL OF MEDICINE Radiology

Imaging studies from PACS 3.b.

- Fluoroscopy with contrast: Right pelvis, coronal plane
- What do we see?

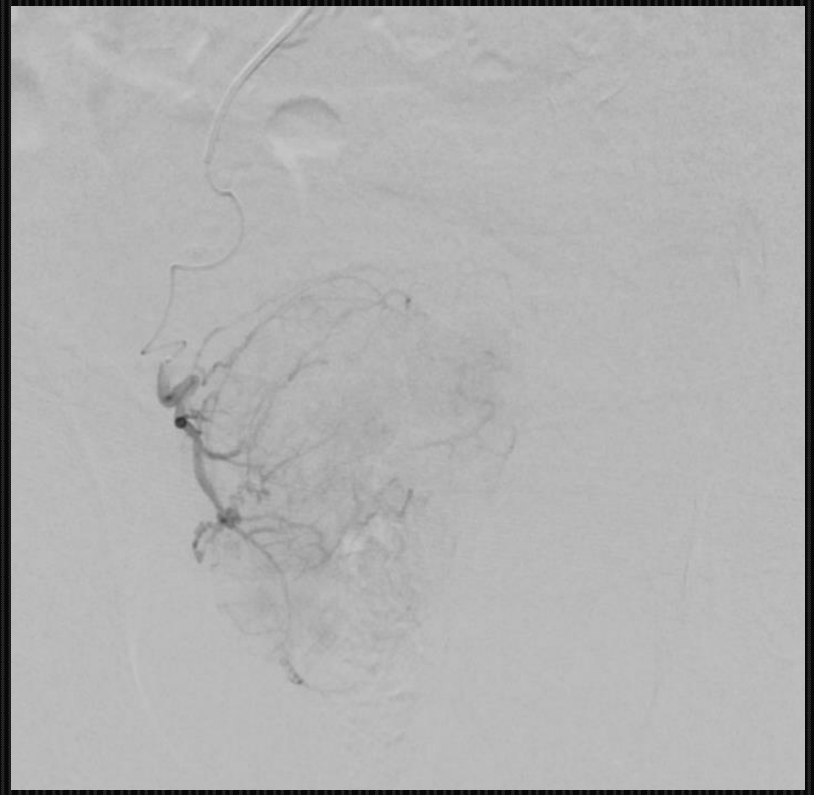

Imaging studies from PACS 3.b.

- Fluoroscopy with contrast: Right pelvis, coronal plane
- What do we see?

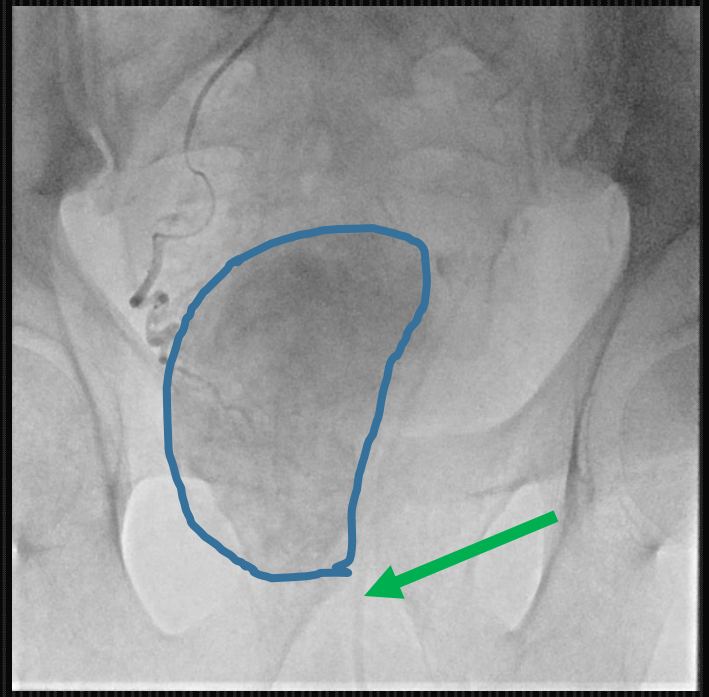

Fluoroscopy of Pelvis with contrast injection at site of Gel-bead injection.
Right lateral prostate lobe (blue outline).
Note hemi-hypertrophy of right prostate, and catheter (green arrow).

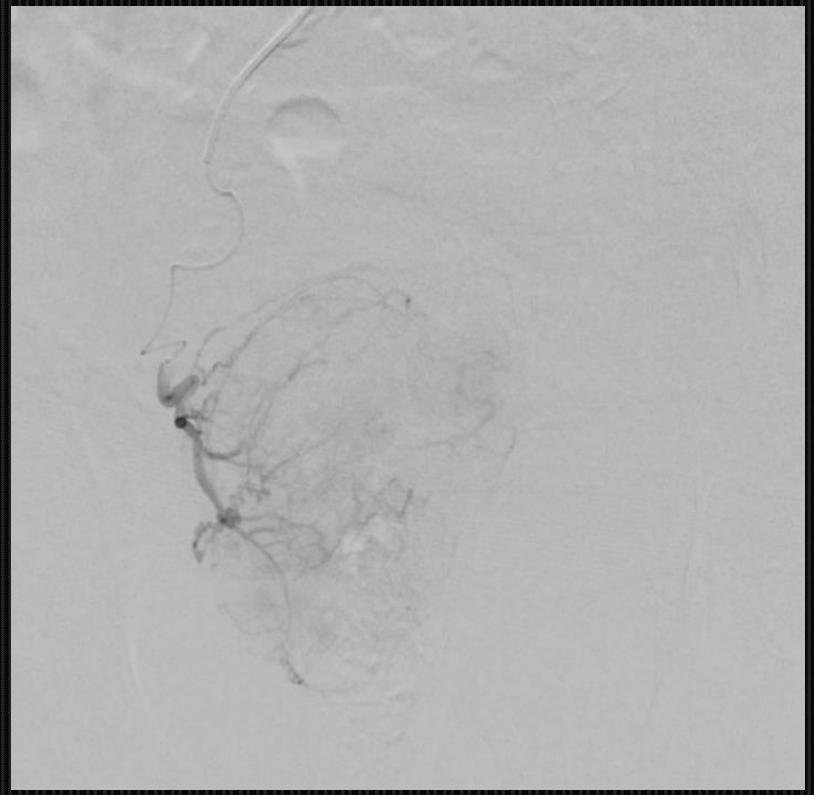

Digital Subtraction Angiography of right pelvis, illustrating prostatic artery branches.

Imaging studies from PACS 4

- Fluoroscopy without and with contrast: Left pelvis
- What do we see?

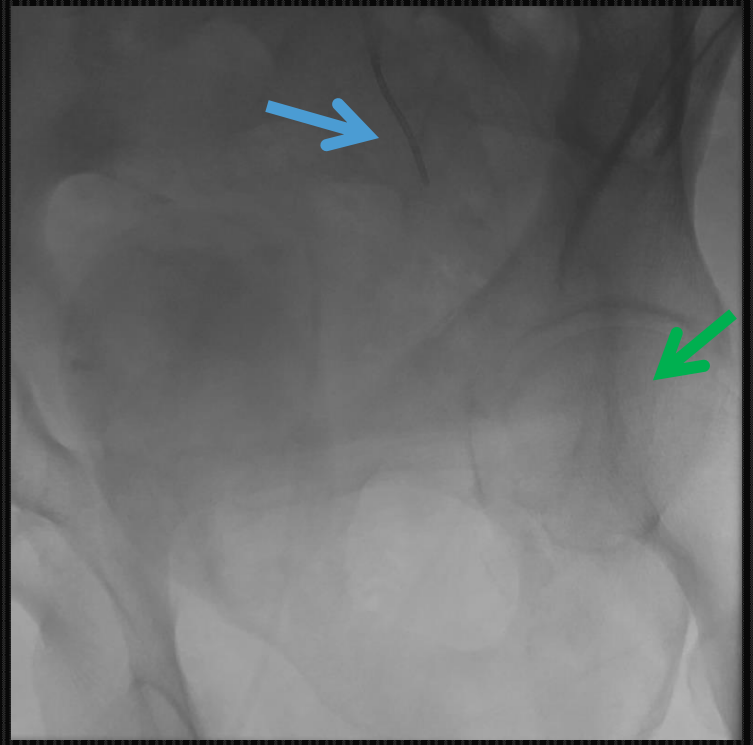

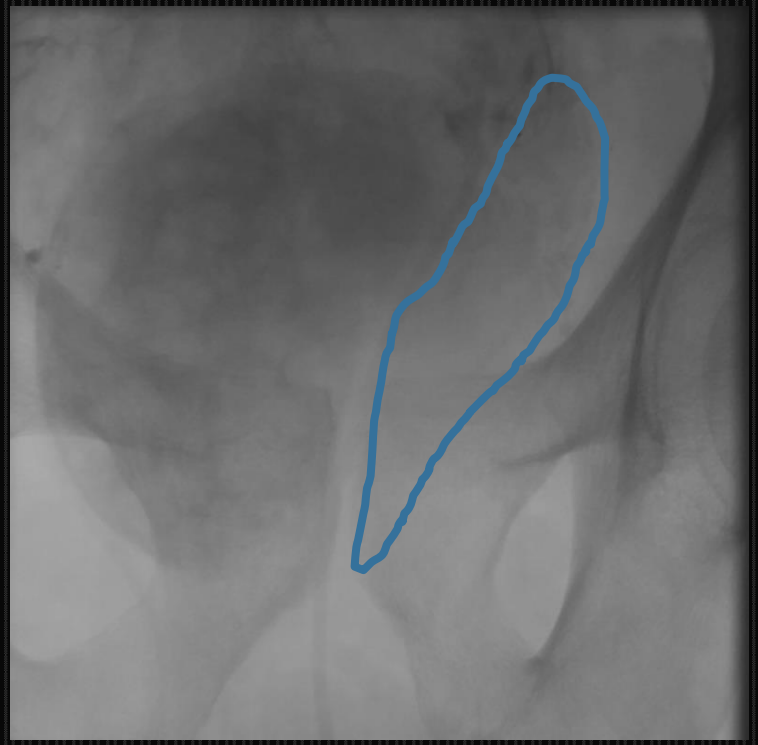

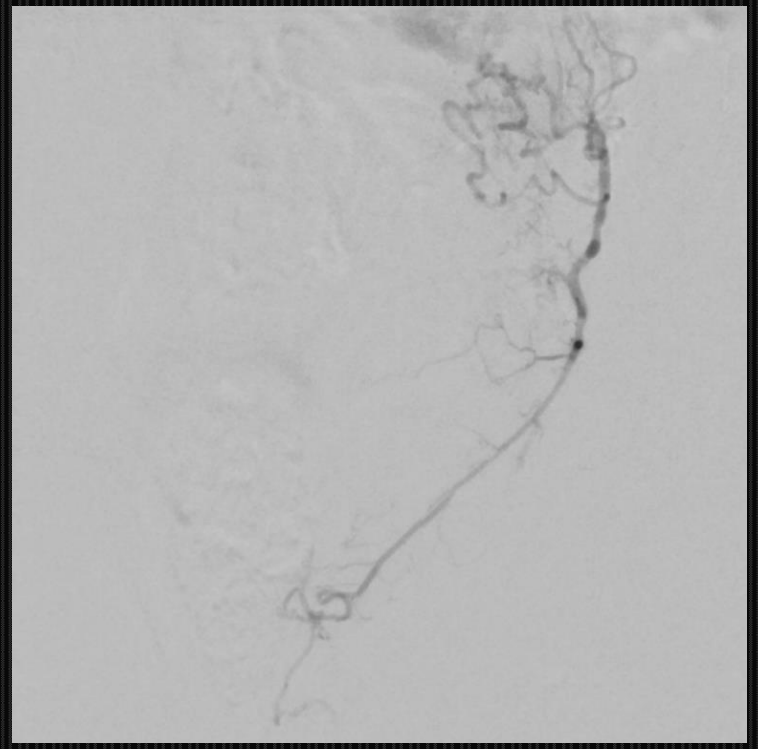

Imaging studies from PACS 4

- Fluoroscopy without and with contrast: Left pelvis
- What do we see?

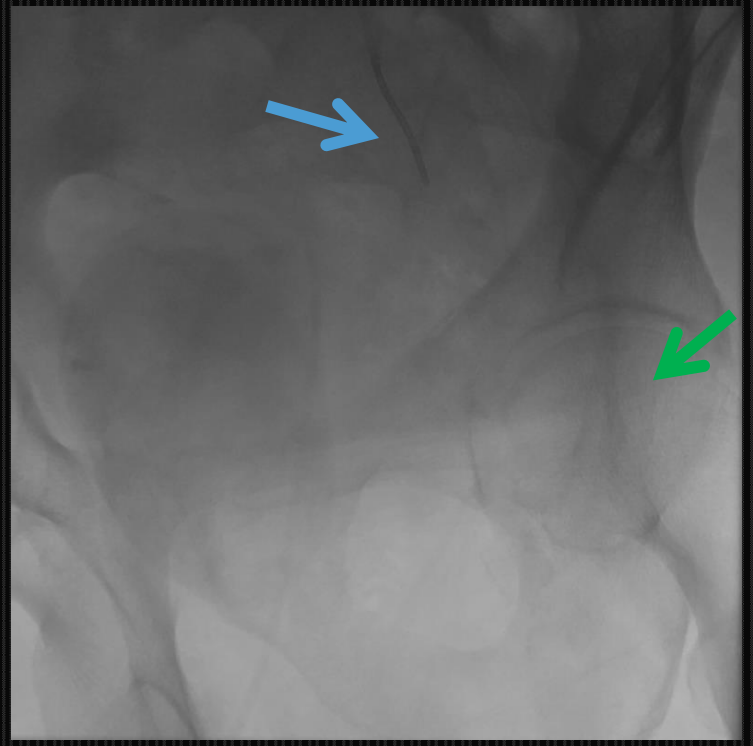

Catheter advancing in left internal iliac artery (blue arrow).
Left femoral head (green arrow)
Left anterior oblique angle.

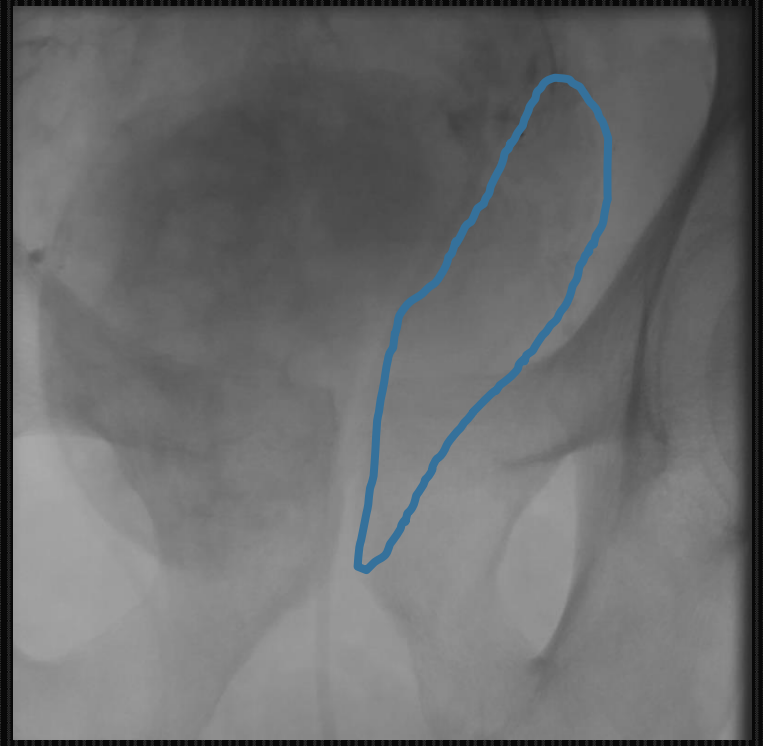

Contrast injection at site of Gel-bead injection.
Left lateral prostate lobe (blue outline)
Coronal plane.

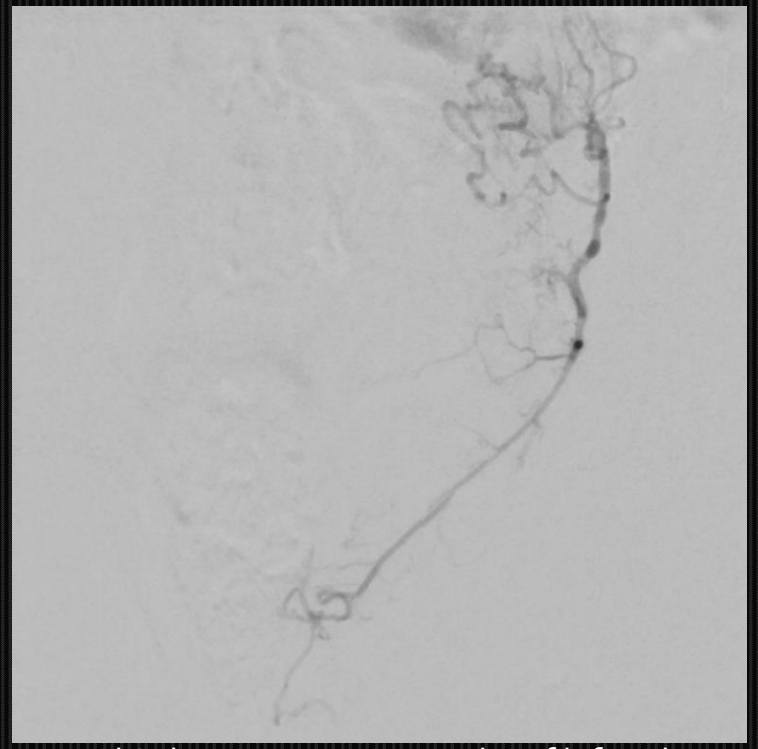

Digital Subtraction Angiography of left pelvis, illustrating prostatic artery branches.

UNC SCHOOL OF MEDICINE Radiology

Imaging discussion 1: Correct imaging?

- Was the correct imaging done for the patient?
  - Diagnostic Imaging:
  - CT urography for hematuria = correct
  - Did not perform ultrasound = correct. No further imaging was required to assess BPH

  - Procedural Imaging:
  - Ultrasound = necessary to confirm radial artery patency
  - Fluoroscopy = necessary for real-time imaging of relevant structures during PAE

Imaging discussion 2: Classic Imaging Findings

- CT urography; axial plane

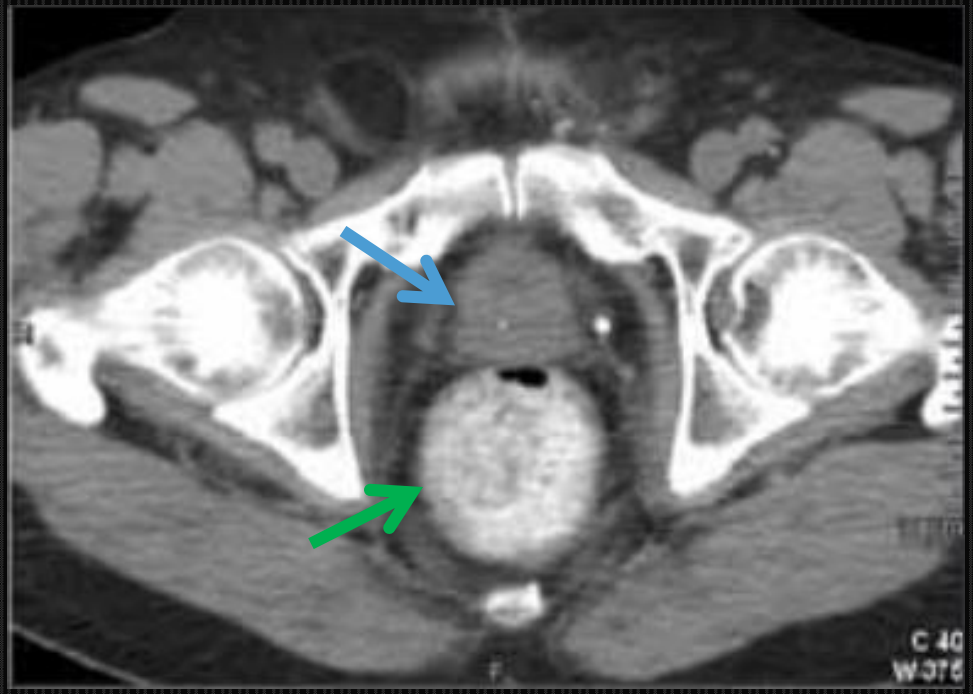

Normal sized prostate (blue arrow)
Colon (green arrow)[11]

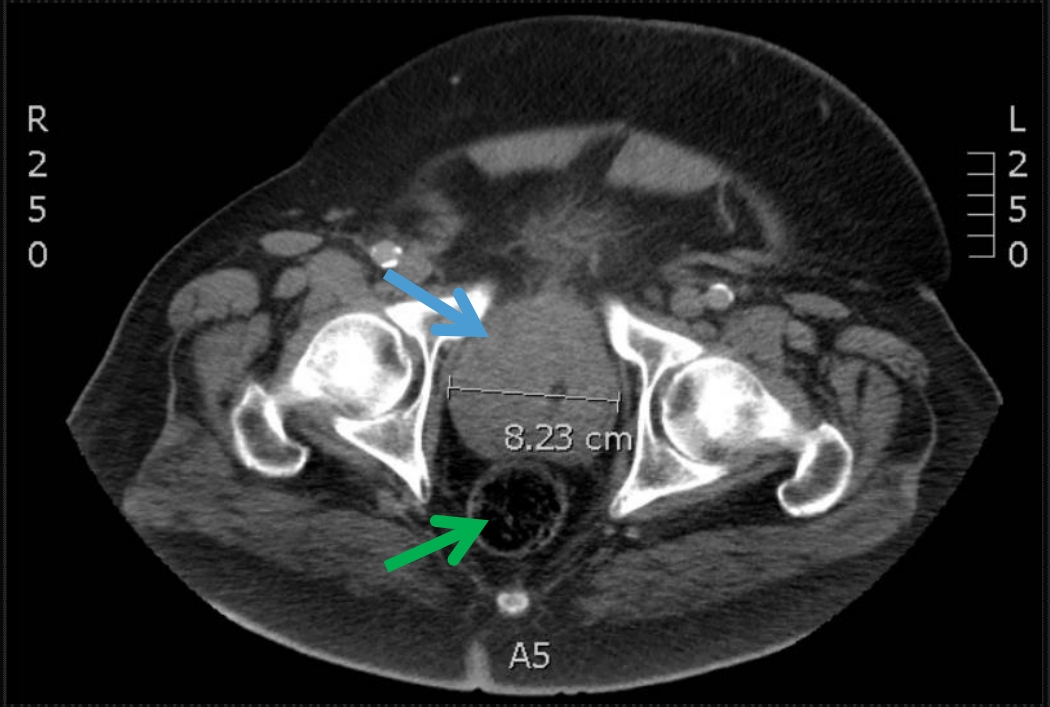

Patient's Prostate with BPH (blue arrow)
Colon (green arrow)

Imaging discussion 3: CT of Abdomen and Pelvis

- CT of Abdomen and Pelvis
  - Sensitivity and specificity:
    - Imaging not utilized for diagnosis of BPH. BPH is typically a clinical diagnosis without imaging.
  - Cost: $1,039[11]
  - Radiation doses: 14.8 mSv[12]

Imaging discussion 4: PAE

- PAE procedure, including ultrasound and fluoroscopy imaging
  - Sensitivity and specificity: Not applicable
  - Cost: $1678.14
    - Including intraprocedural supplies, anesthesia, nursing, staff
    - TURP cost for comparison: $5338.31
      - Difference in costs primarily due to longer hospital stay for TURP: 1.38 d, vs 0.125 d for PAE[13]
  - Radiation doses:
    - 450.7 Dose Area Product(DAP) ($Gy \cdot cm^2$) per procedure
      - DAP indicates radiation absorbed by a specific tissue
      - ≈ 180 mSv[14] (≈ 12 CTs)
      - 71.5%: digital subtraction angiography; 19.9%: fluoroscopy; 8.6%: cone-beam CT
    - Ultrasound for artery patency: no radiation exposure
    - Average time under fluoroscopy: 30.9 minutes[15]

Wrapping Up: Test Yourself

- What is the average size of a prostate in grams?
- Name three surgical procedures for treating benign prostatic hyperplasia:
- Which of those procedures is
  - More effective?
  - Less expensive?
  - Less invasive?

Wrapping Up: Test Yourself

- What is the average size of a prostate in grams? 11 gm
- Name three surgical procedures for treating benign prostatic hyperplasia: PAE, TURP, prostatectomy
- Which of those procedures is
  - More effective? TURP, prostatectomy
  - Less expensive? PAE
  - Less invasive? PAE

References

1. Abdi, H, A Kazzazi, ST Bazargani, B Djavan, and S Telegrafi. 2013. "Imaging in Benign Prostatic Hyperplasia: What Is New?" *Current Opinion in Urology* 23 (1). https://doi.org/0.1097/MOU.0b013e32835abd91.
2. Benway, MD, Brian, and Gerald Andriole. n.d. "Prostate Biopsy." Edited by Jerome Richie. UpToDate. UpToDate. July 12, 2017. https://www.uptodate.com/contents/prostate-biopsy?search=prostate%20biopsy&source=search_result&selectedTitle=1~61&usage_type=default&display_rank=1.
3. 2014. "ACR Appropriateness Criteria: Hematuria." American College of Radiology. American College of Radiology. 2014. https://acsearch.acr.org/docs/69490/Narrative/.
4. 2014. "ACR Appropriateness Criteria: Lower Urinary Tract Symptoms." American College of Radiology. American College of Radiology. 2014. https://acsearch.acr.org/docs/69368/Narrative/
5. Cunningham, MD, Glenn, and Dov Kadmon, MD. 2017. "Clinical Manifestations and Diagnostic Evaluation of Benign Prostatic Hyperplasia." Edited by Michael O'Leary, MD. UpToDate. UpToDate. October 31, 2017. https://www.uptodate.com/contents/clinical-manifestations-and-diagnostic-evaluation-of-benign-prostatic-hyperplasia?search=bph%20diagnosis&source=search_result&selectedTitle=1~150&usage_type=default&display_rank=1#H5.
6. Cunningham, MD, Glenn, and Dov Kadmon, MD. 2018. "Transurethral Procedures for Treating Benign Prostatic Hyperplasia." Edited by Michael O'Leary, MD and Jerome Richie, MD. UpToDate. UpToDate. January 8, 2018. https://www.uptodate.com/contents/transurethral-procedures-for-treating-benign-prostatic-hyperplasia?search=prostate%20artery%20embolization&source=search_result&selectedTitle=1~150&usage_type=default&display_rank=1#H1613477544.
7. n.d. "Prostate Artery Anatomy Blood Supply To The Prostate." Human Body Anatomy. Human Body Anatomy. Accessed June 15, 2018. https://humanbodyanatomy.co/prostate-artery-anatomy/prostate-artery-anatomy-blood-supply-to-the-prostate-human-anatomy-lesson/.
8. 2018. "Fluoroscopy." U.S. Food and Drug Administration. U.S. Food and Drug Administration. March 3, 2018. https://www.fda.gov/Radiation-EmittingProducts/RadiationEmittingProductsandProcedures/MedicalImaging/MedicalX-Rays/ucm115354.htm.
9. 2017. "Prostatic Artery Embolization." CLIS: Center for Laser and Interventional Surgery. CLIS. 2017. http://beirutclis.com/portfolio-item/prostatic-artery-embolization/.
10. 2018. "Transurethral Resection of the Prostate (TURP)." UpToDate. UpToDate. January 8, 2018. https://www.uptodate.com/contents/image?topicKey=8093&search=&source=outline_link&imageKey=SURG%2F72119.
11. n.d. "CT Scan of Abdomen & Pelvis with Contrast." MD Save. MD Save. Accessed June 15, 2018. https://www.mdsave.com/procedures/ct-scan-of-abdomen-and-pelvis-with-contrast/d781f5c4.
12. Nawfel, Richard, Philip Judy, Robert Schleipman, and Stuart Silverman. 2004. "Patient Radiation Dose at CT Urography and Conventional Urography." *Radiology* 232 (1). https://doi.org/10.1148/radiol.2321030222.
13. Bagla, S, J Smirniotopoulos, J Orlando, and R Piechowiak. 2017. "Cost Analysis of Prostate Artery Embolization (PAE) and Transurethral Resection of the Prostate (TURP) in the Treatment of Benign Prostatic Hyperplasia." *Cardiovascular and Interventional Radiology* 40 (11). https://doi.org/10.1007/s00270-017-1700-7.
14. Nickoloff, Edward, and Zheng Feng Lu. 2008. "Radiation Dose Descriptors: BERT, COD, DAP, and Other Strange Creatures" 28. https://doi.org/10.1148/rg.285075748.
15. Andrade, G, HJ Khoury, WJ Garzon, F Dubourcq, MF Bredow, LM Monsignore, and DG Abud. 2017. "Radiation Exposure of Patients and Interventional Radiologists during Prostatic Artery Embolization: A Prospective Single-Operator Study." *Journal of Vascular and Interventional Radiology* 28 (4). https://doi.org/10.1016/j.jvir.2017.01.005.