RADY 401 Case Presentation

Christina Rizk

June 2018

Ed. John Lilly, MD

UNC SCHOOL OF MEDICINE Radiology

Focused patient history and workup

- 33 yo male with history of sarcoidosis
- Diagnosed in 2015 via chest CT and bronchoscopy w/ biopsy at WakeMed
- Has pulmonic, ocular, and splenic involvement.
- Presented to pulmonologist for follow up
  - Ordered imaging and blood work to reassess sarcoid activity and determine utility of trail of alternative immunosuppressant

List of imaging studies

- CT Chest w/o contrast

Imaging studies from PACS 1

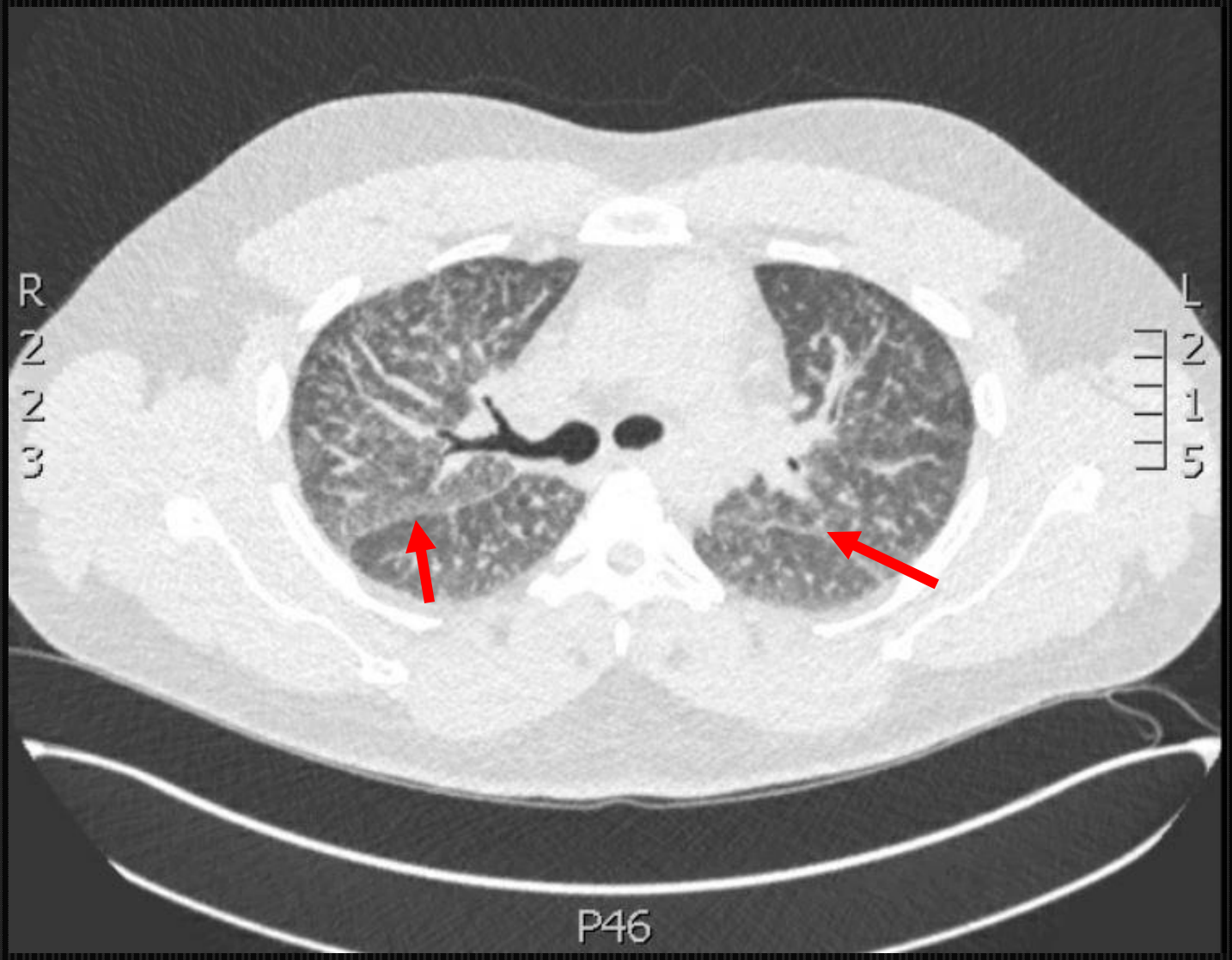

Non contrast CT, axial

There are extensive bilateral linear and nodular opacities along the bronchovascular distribution, most consistent with sarcoidosis
Extensive bilateral reticulonodular pulmonary parenchymal opacities, most consistent with given history sarcoidosis

Imaging studies from PACS 2

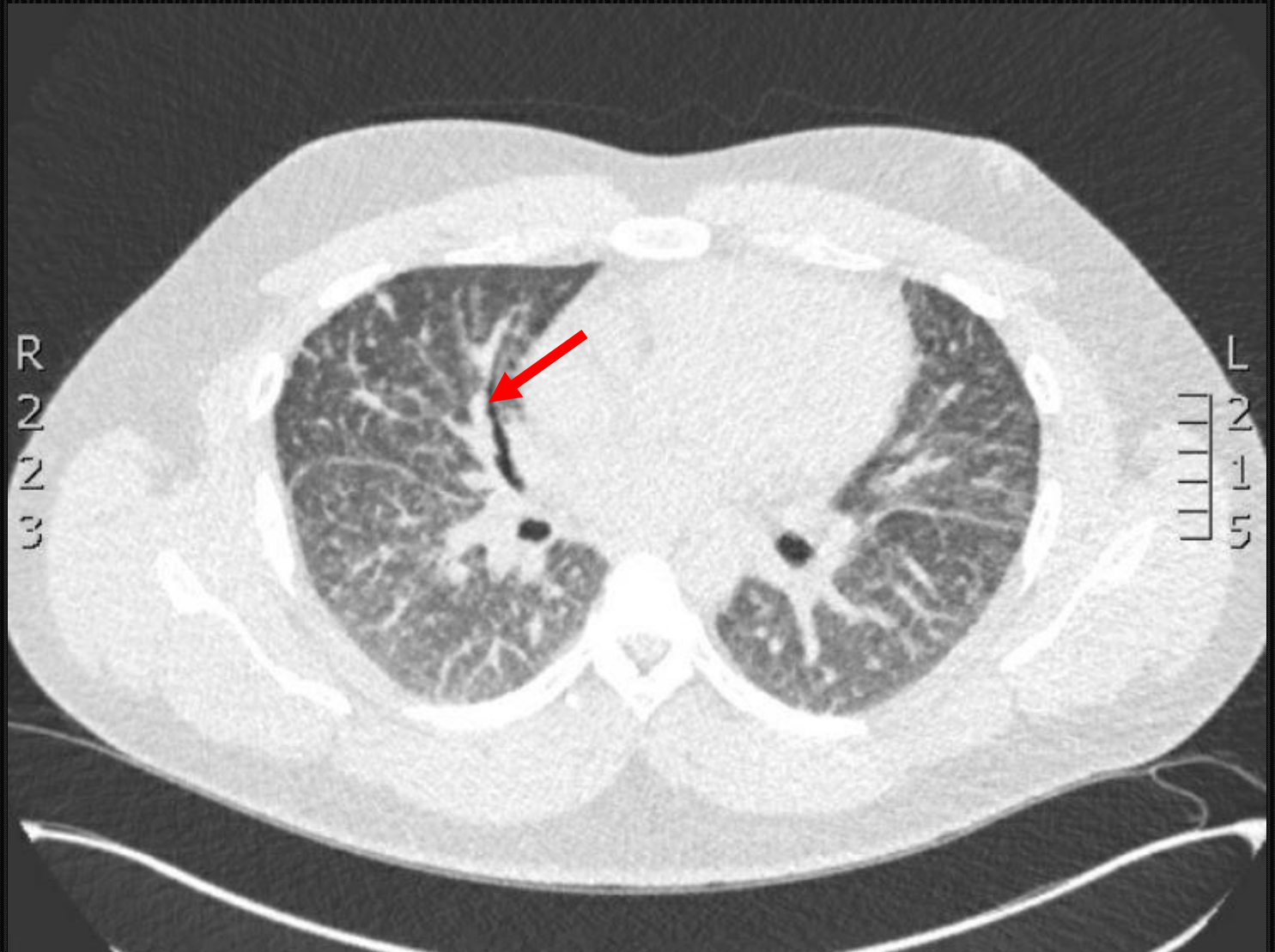

Non contrast CT, axial

More nodules everywhere, affecting airways

Patient treatment or outcome

- Currently on prednisone 20 mg daily, Qvar 80 mcg 2 puffs BID, and albuterol PRN
  - Feels less dyspneic
  - Still having some episodes of cough and wheezing
- Failed trial of MTX last year
- Considering different immunosuppressive drug

Correct Imaging Test?

- Initial Imaging[1]:
  - Chest X-ray
  - High Resolution Chest CT to evaluate abnormalities seen on CXR
- Monitoring Disease Activity
  - Active Disease
    - Chest x-ray every 12 months[1]
    - HRCT as indicated by symptoms or other tests [1,2]
    - CT not recommended for routine use for monitoring disease due to increased radiation hazard in young patients [2]
  - Inactive Disease
    - No imaging indicated[1]

Classic CXR Findings

HILAR LYMPHADENOPATHY[2]

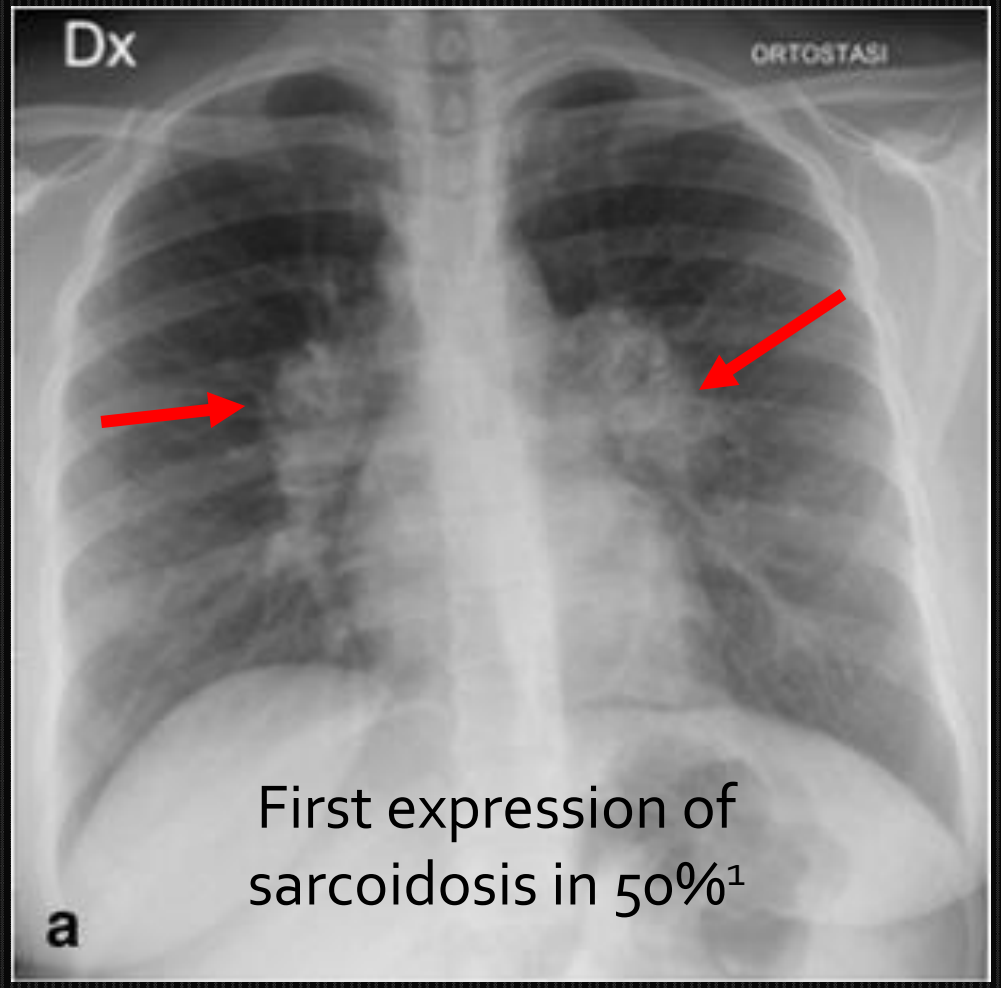

First expression of sarcoidosis in 50%[1]

RETICULAR OPACITIES [1]

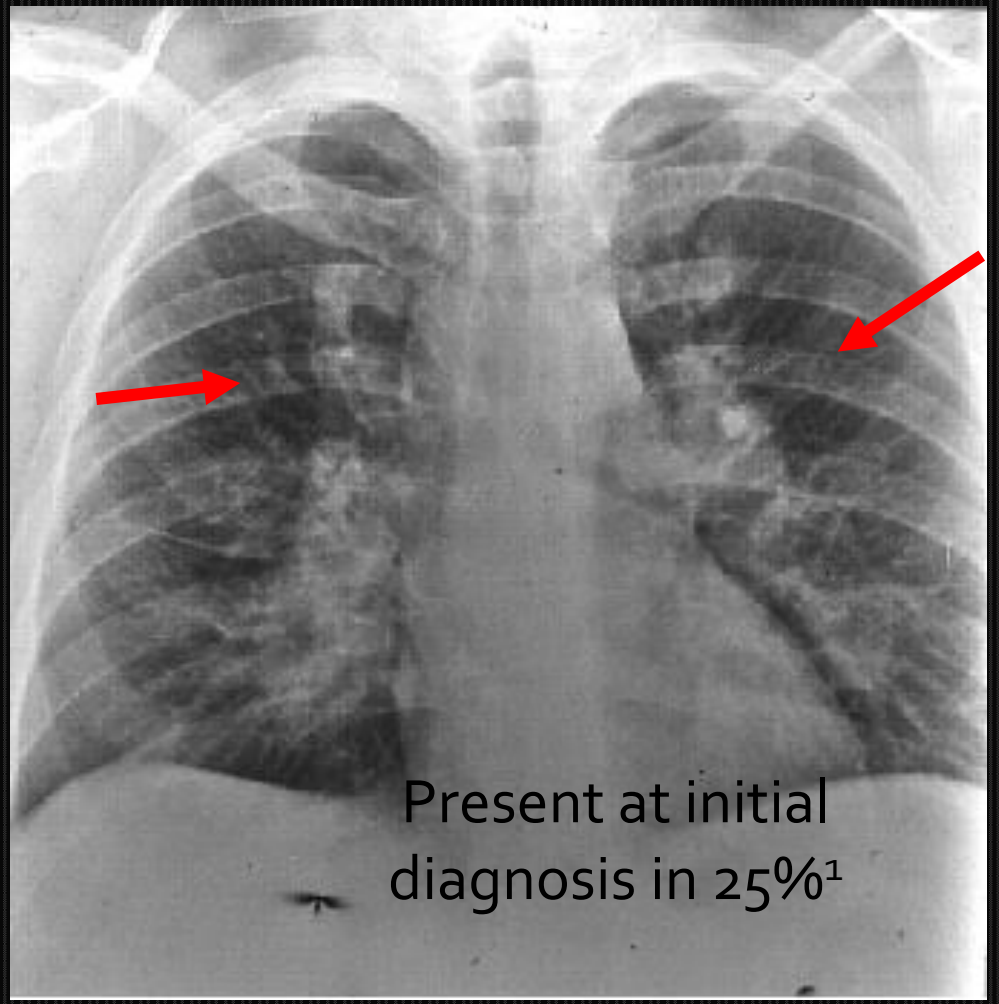

Present at initial diagnosis in 25%[1]

Classic Chest CT Findings

LYMPHADENOPATHY[5]

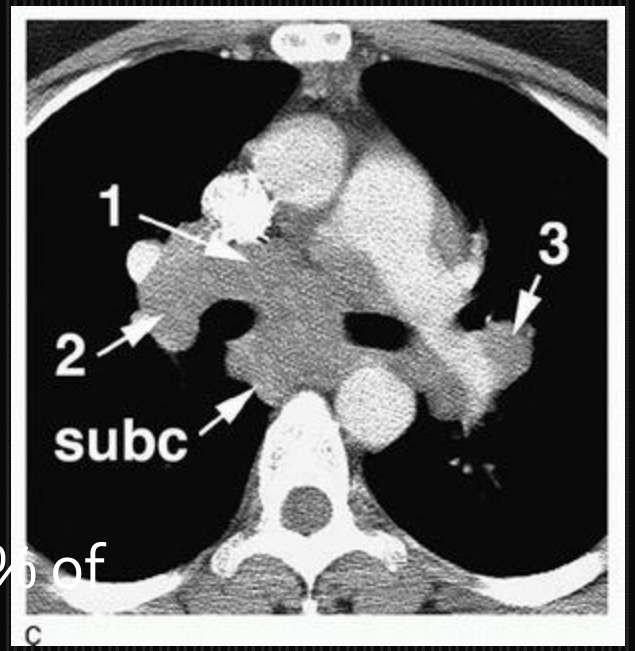

Seen in >80% of patients[5]

1. Right paratracheal
2. Right hilum
3. Left hilum
4. Subcarinal

LYMPH NODE CALCIFICATION[5]

Seen in 25-50% of cases[5]

Classic Chest CT Findings

Nodules[5,7]

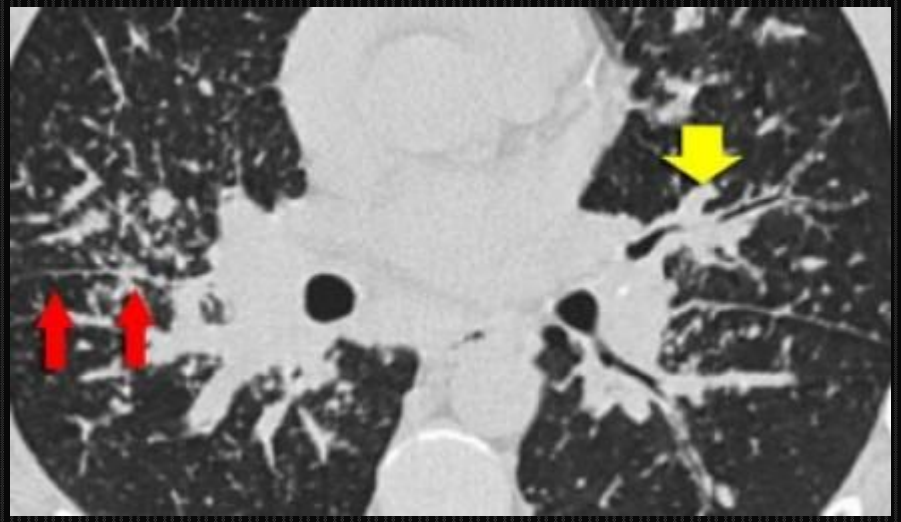

A

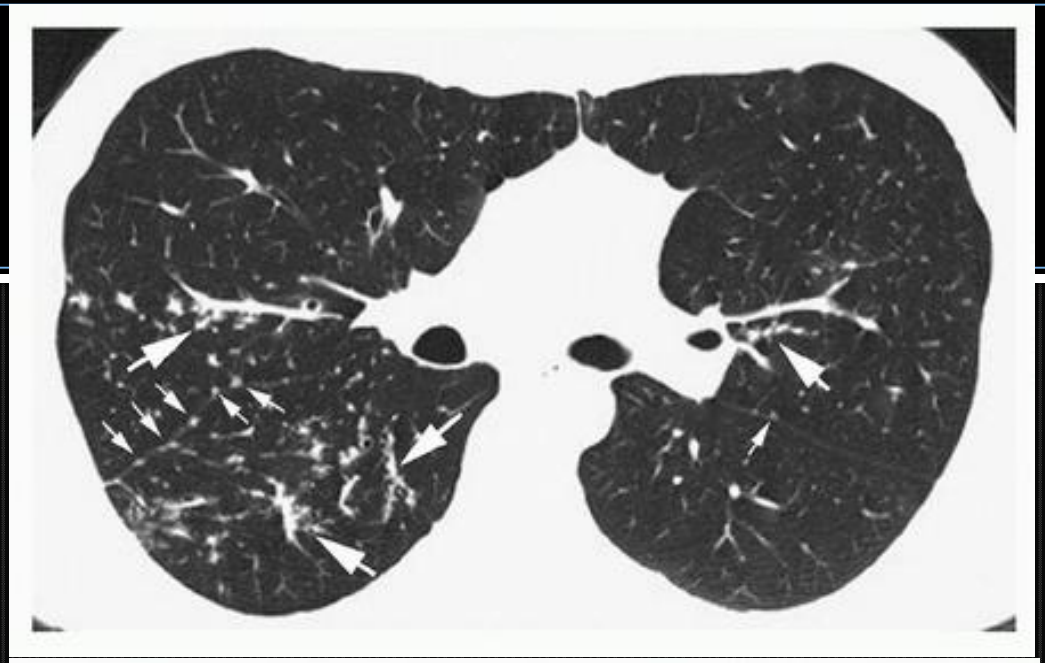

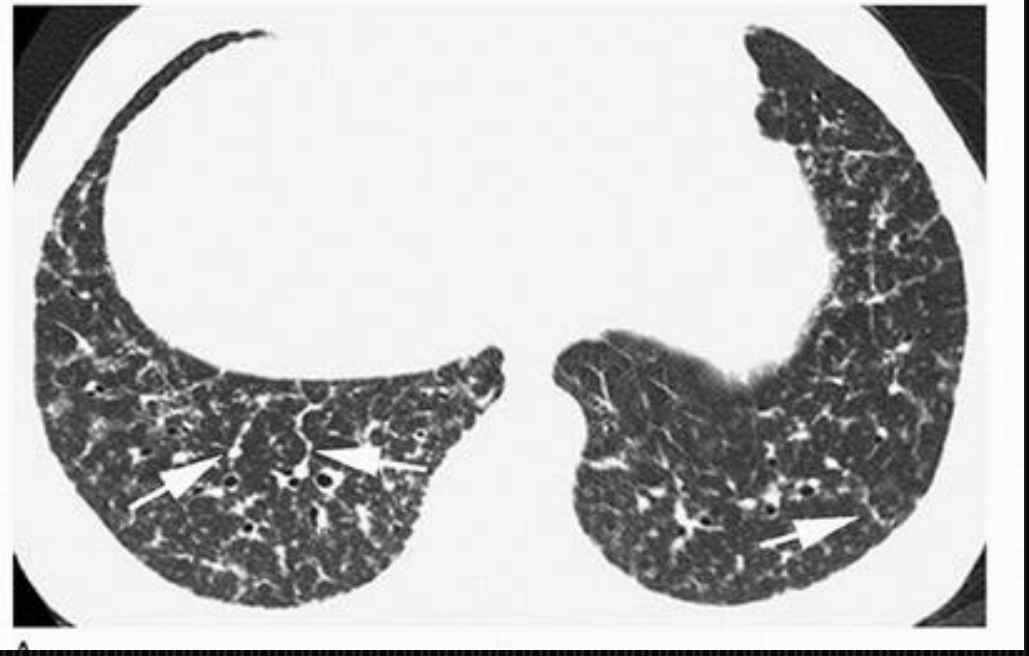

B

C

Commonly in perilymphatic distribution [5,7]

- Sub pleural surfaces and fissures (A,B)
- Interlobular septa (C)
- Bronchovascular bundle (A,B)

Classic Chest CT Findings

Bronchial Abnormalities[5,7]

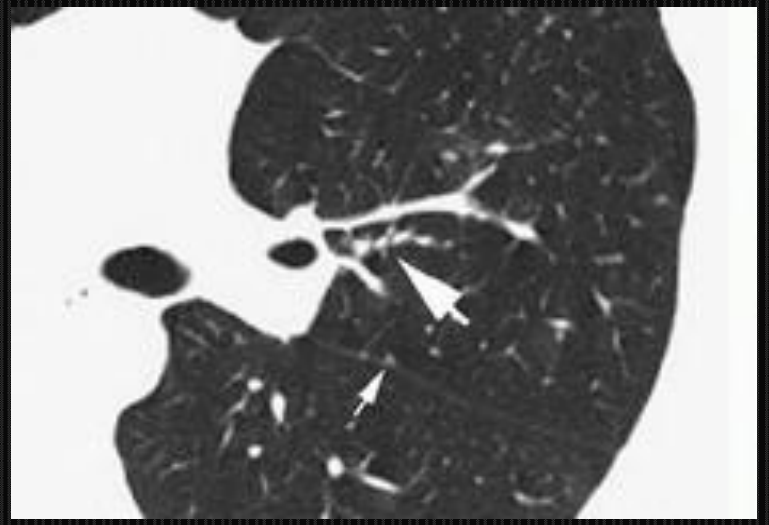

In as many as 65% of patients[5]

- Nodular bronchial wall thickening
- Small Endobronchial lesions

Sensitivity and Specificity

- Chest X-ray[8]
  - Sensitivity: 30%
  - Specificity: 85%
- Chest CT w/o contrast[8]
  - Sensitivity: 90%
  - Specificity: 86%

Costs and Radiation Doses

- Chest X-ray
  - Costs: $130-$280 [4]
  - Radiation Dose: 0.02 mSv[6]
- Chest CT w/o contrast
  - Costs: $470-$1,050 [4]
  - Radiation Dose: 8.2 mSv[3]

Wrap Up Sarcoidosis

- CXR findings of hilar lymphadenopathy and reticular opacities
- Chest CT findings of hilar lymphadenopathy and nodules
- Nodules in bronchovascular bundle, fissures, interlobular septa, sub-pleural surfaces

References

1. King TE. Clinical manifestations and diagnosis of pulmonary sarcoidosis. *UpToDate*.
2. Silva M, Nunes H, Valeryre D, Sverzellati N. Imaging of Sarcoidosis. (2015). *Clinical Reviews in Allergy & Immunology, 49 (1).* pp49-53. Retrieved June 12, 2018
3. Smith-Bindman R, Lipson J, Marcus R, et al. Radiation dose associated with common computed tomography examination and the associated lifetime attributable risk of cancer. (2009). *Arch Intern Med.* 169(22). Pp2078-2086. Retrieved June 12, 2018
4. Chest CT scan cost and procedure information. *New Choice Health.* Retrieved June 13, 2018
5. Webb WR, Higgins CB. (2017) *Thoracic Imaging: pulmonary and cardiovascular radiology*. Philadelphia, PA: Wolters Kluwer
6. Gargani L, Picano E. The risk of cumulative radiation exposure in chest imaging and the advantage of beside ultrasound. (2015). *Crit Ultrasound Journal.* 7(4). Retrieved Jun 13, 2018
7. Smithuis R, VanDelden O, Schaefer-Prokop C, Lung-HRCT Common Diseases. Radiology Assistant. Retrieved June 14, 2018.
8. Russo JJ, Nery PB, Ha AC, Healey J, et al. Sensitivity and specificity of chest imaging for screening of sarcoidosis in patients with cardiac presentations (2016). *Canadian Journal of Cardiology*, 32(10). Pp S103-S104