RADY 401 Case Presentation

Maili Lim, MS4

June 2018

Ed. John Lilly, MD

UNC SCHOOL OF MEDICINE Radiology

An 86-year-old woman presenting with 2 weeks of intermittent abdominal pain

Patient history and workup

OC is an 86 year old Hispanic female who presents to UNC as an outside facility transfer following imaging that revealed a >12cm abdominal aortic aneurysm (AAA). Patient had initially presented to OSH for 2 weeks of intermittent LLQ pain, which began after she was started on aspirin and Pepto-Bismol by a provider in Mexico.

What imaging studies should be ordered?

List of imaging studies

- CT of the abdomen and pelvis with contrast (OSH)
- CT angiography of the chest, abdomen, and pelvis

Revised 2017

American College of Radiology
ACR Appropriateness Criteria®
Abdominal Aortic Aneurysm: Interventional Planning and Follow-up

Variant 1: **Planning for pre-endovascular repair (EVAR) or open repair of AAA.**

Procedure	Appropriateness Category	Relative Radiation Level
CTA abdomen and pelvis with IV contrast	Usually Appropriate	☢☢☢☢☢
MRA abdomen and pelvis without and with IV contrast	Usually Appropriate	O
MRA abdomen and pelvis without IV contrast	May Be Appropriate	O
CT abdomen and pelvis with IV contrast	May Be Appropriate	☢☢☢☢
CT abdomen and pelvis without IV contrast	May Be Appropriate	☢☢☢☢
Aortography abdomen	May Be Appropriate	☢☢☢
CT abdomen and pelvis without and with IV contrast	May Be Appropriate	☢☢☢☢
US aorta abdomen with duplex Doppler	Usually Not Appropriate	O
X-ray abdomen and pelvis	Usually Not Appropriate	☢☢☢
CT abdomen and pelvis without IV contrast and US aorta abdomen with duplex Doppler	Usually Not Appropriate	☢☢☢☢

Variant 2: **Follow-up for postendovascular repair (EVAR) or open repair of AAA.**

Procedure	Appropriateness Category	Relative Radiation Level
CTA abdomen and pelvis with IV contrast	Usually Appropriate	☢☢☢☢☢
MRA abdomen and pelvis without and with IV contrast	Usually Appropriate	O
Aortography abdomen	May Be Appropriate	☢☢☢
CT abdomen and pelvis without and with IV contrast	May Be Appropriate	☢☢☢☢
CT abdomen and pelvis without IV contrast and US aorta abdomen with duplex Doppler	May Be Appropriate	☢☢☢☢
MRA abdomen and pelvis without IV contrast	May Be Appropriate	O
US aorta abdomen with duplex Doppler	May Be Appropriate	O
CT abdomen and pelvis without IV contrast	May Be Appropriate	☢☢☢☢
CT abdomen and pelvis with IV contrast	May Be Appropriate (Disagreement)	☢☢☢☢
X-ray abdomen and pelvis	May Be Appropriate	☢☢☢

CT of the abdomen and pelvis with contrast

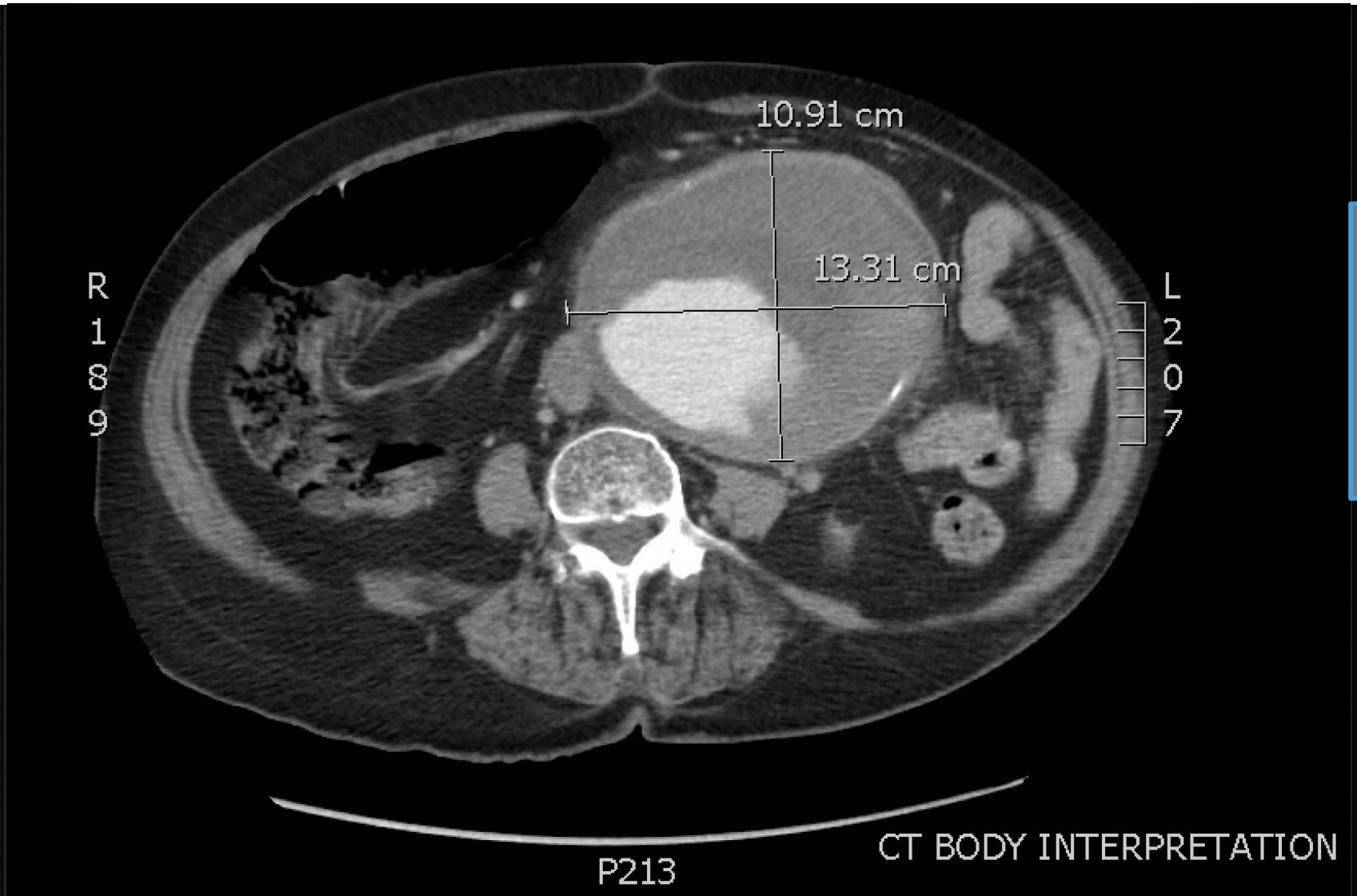

CT A/P with contrast showed a large infrarenal abdominal aortic aneurysm measuring up to 13.3 cm in the greatest transverse dimension. No retroperitoneal hemorrhage was identified.

UNC SCHOOL OF MEDICINE Radiology

Coronal view of CT A/P

CT A/P with contrast showed a large infrarenal abdominal aortic aneurysm measuring up to 13.3 cm in the greatest transverse dimension. No retroperitoneal hemorrhage was identified.

Aortic calcifications present

Intraluminal thrombus denoted by region of hypodensity

CT angiography of the chest, abdomen, and pelvis

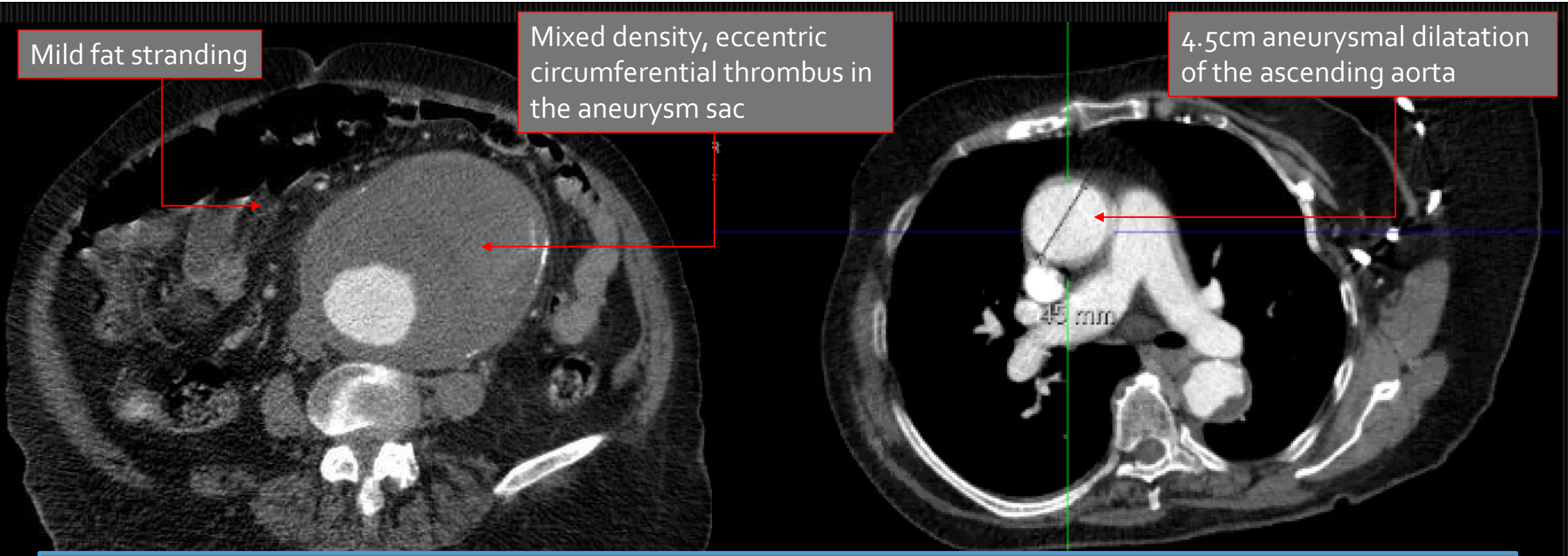

Aneurysmal dilatation of the ascending aorta measuring up to 4.5 cm. The patient has a Crawford Type III thoracoabdominal aortic aneurysm (TAAA) extending to the iliac bifurcation, with the largest infrarenal portion measuring up to 12.4 x 10.7 cm in greatest orthogonal dimensions. No evidence of active extravasation or aortic dissection.

Other views - sagittal, coronal, 3D

UNC SCHOOL OF MEDICINE Radiology

Patient outcome

Patient remained hemodynamically stable, but developed worsening abdominal pain. Discussion of possible options (endovascular repair, open repair, or comfort measures) were delayed to allow family members to arrive. She was found pulseless and unresponsive a few days later. Code blue was called and after multiple unsuccessful rounds of CPR the family requested to stop the code.

Discussion: Classic Findings on Imaging

CT angiography is the gold standard![1,2,5,7]

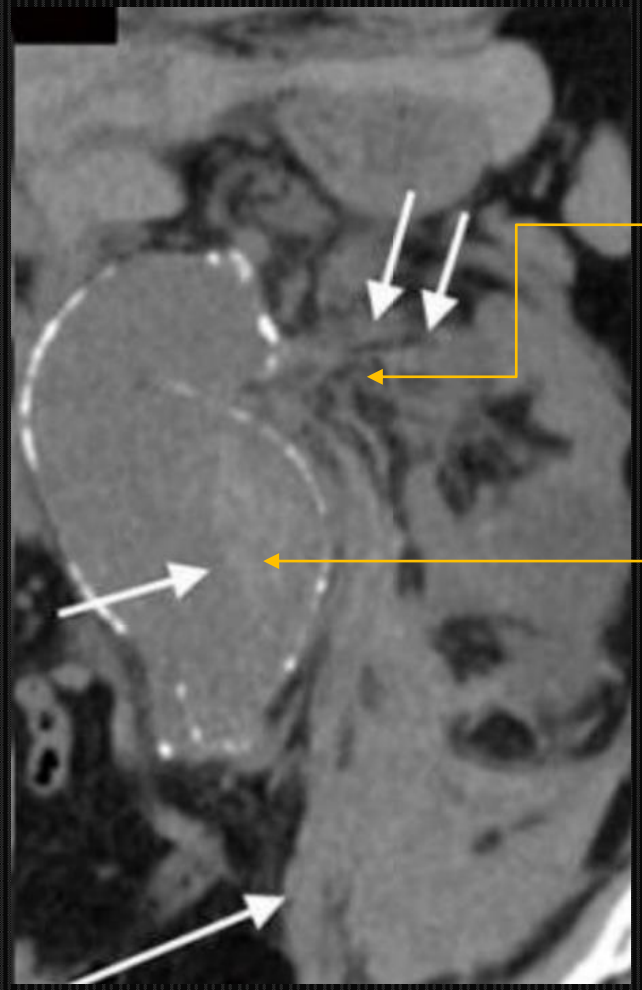

Peri-aortic fat stranding is thought to be the earliest sign before rupture.[1]

High-attenuation crescent sign associated with rupture. This is thought to be due to hemorrhage in the mural thrombus or in the aneurysmal wall.[1]

The presence of high-attenuation contrast in the **retroperitoneal hematoma** is suggestive of active bleeding in a ruptured AAA.[10]

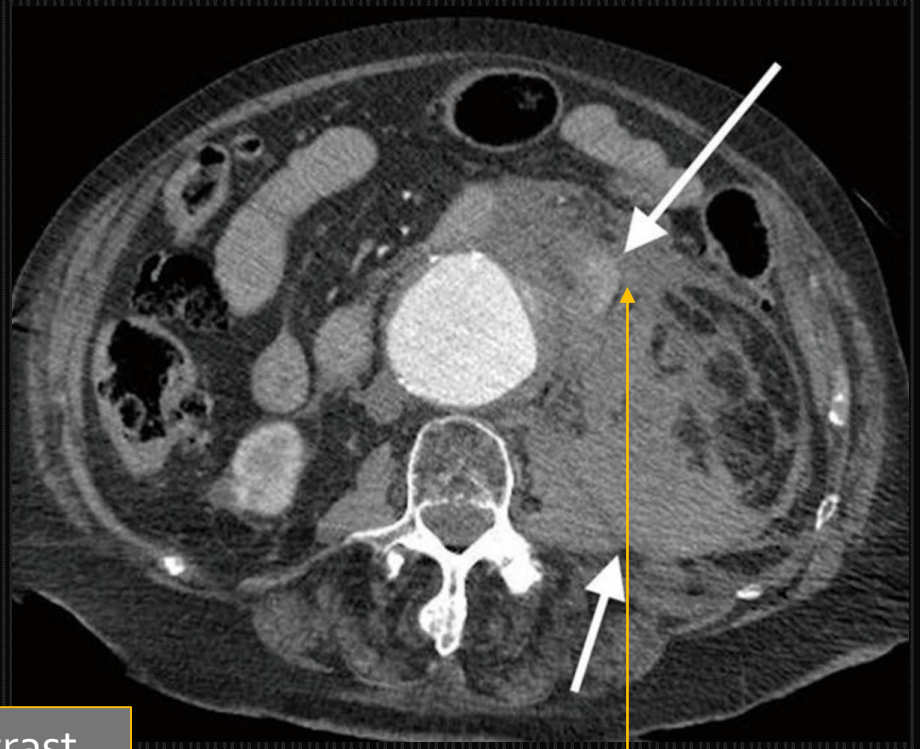

Discussion: Imaging Algorithm for AAA

- How do we select an imaging modality?
  - Clinical presentation
- Ultrasound[2,3]
  - Asymptomatic
  - Hemodynamically unstable with suspected but not confirmed ruptured AAA
- Abdominal CT with contrast[2,3]
  - Hemodynamically stable with suspected AAA
- CT angiography with 3D reconstruction[2,3]
  - Suspected ruptured AAA in anticipation of potential endovascular repair

Discussion: Ultrasound vs CT

	Advantages	Disadvantages
Ultrasound[2]	• Non-invasive • No ionizing radiation (0 mSv) • Less expensive (~$400) • High sensitivity (95%) and specificity (99%) for unruptured AAA	• Technician and equipment-dependent • Imprecise for procedural planning or anatomic evaluation
CT[2] (chest, abdomen, pelvis)	• Better at differentiating ruptured vs. unruptured aneurysm • Better at evaluating suprarenal aneurysms • Capable of defining extent of aneurysm (as defined by SVS) • Sensitivity 83%, Specificity 99%	• More expensive (~$1000) • Can overestimate aortic diameter • Radiation risk (~20 mSv)

Discussion: Risk of Rupture with AAAs

- Rupture risk increases markedly with diameter >5.5 cm[2]
  - Estimated rupture risk over a 12-month period:
    - 10–20% for those between 6-7 cm
    - 20–40% for those 7-8 cm
    - **30–50% for those >8cm**

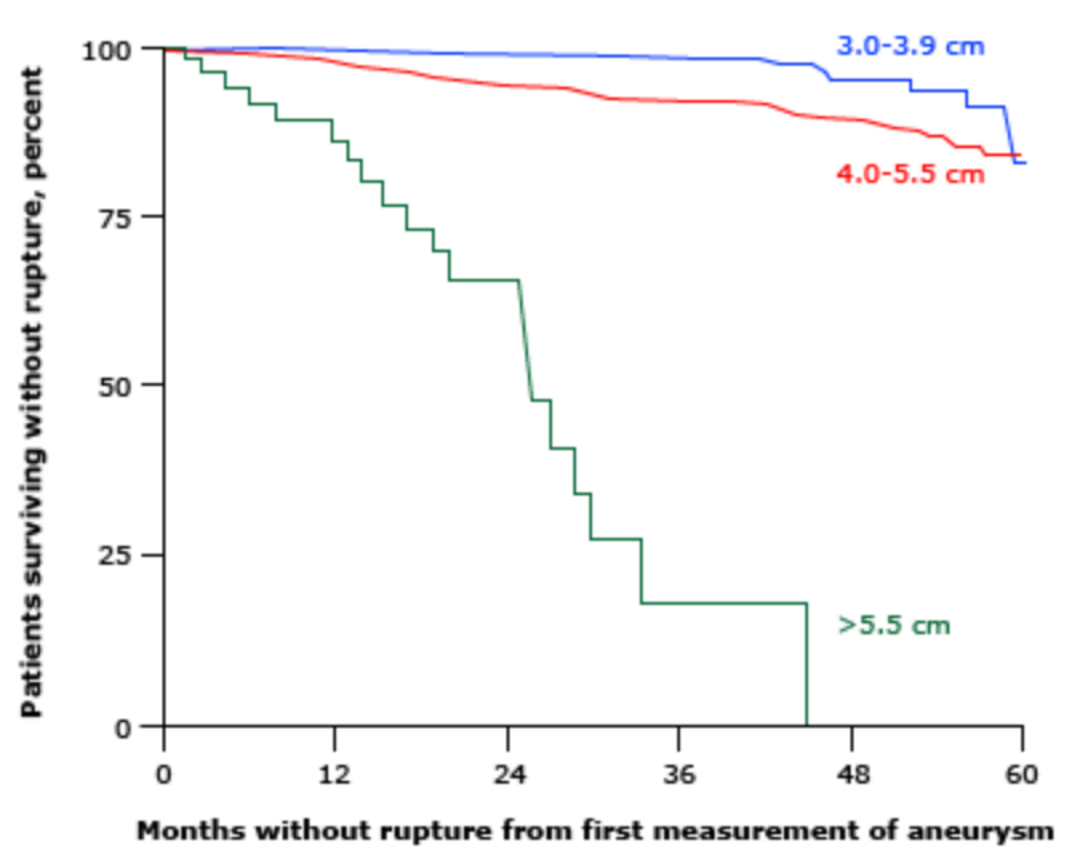

Discussion: Management of AAAs

- Methods of Repair
  - Open
  - EVAR (endovascular aneurysm repair)
- Recommended for **asymptomatic** patients with diameter >5.5cm
  - Other risk factors include age and sex of patient, rate of expansion, coexistent PAD, aneurysm morphology
- Repair is not typically warranted for asymptomatic aneurysms <5.5 cm in diameter
  - No difference in mortality or aneurysm-related death in those with asymptomatic AAAs with diameters between 40-5.4 cm
- Society for Vascular Surgery Guidelines 2018
  - 3.0 - 3.9 cm → imaging at 3-year intervals
  - 4.0 - 4.9 cm → imaging at 12-month intervals
  - 5.0 - 5.4 cm → imaging at 6-month intervals[2,3,6]

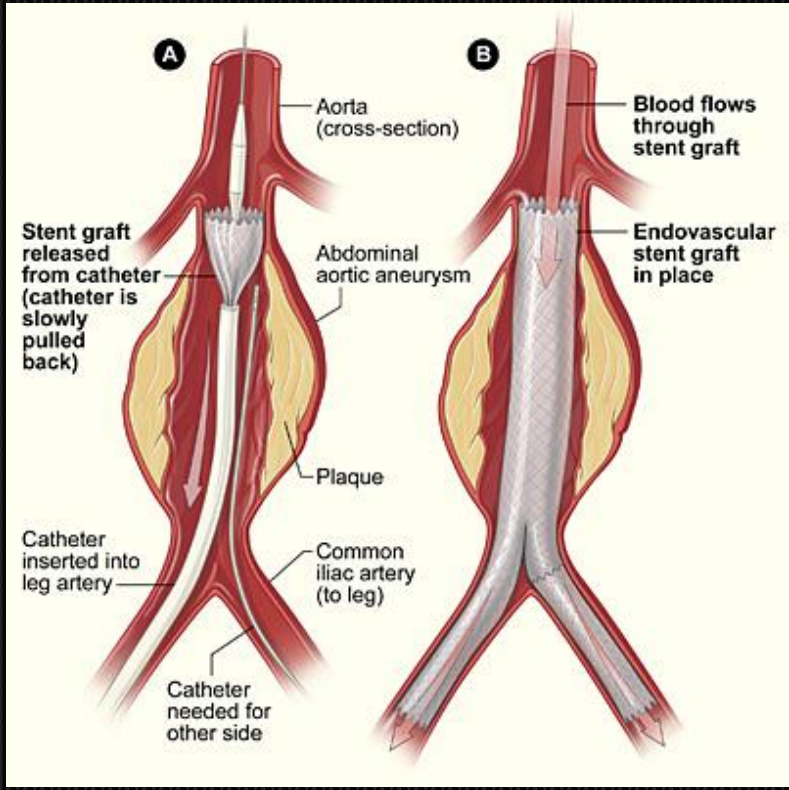

Discussion: Crawford TAAA Classification

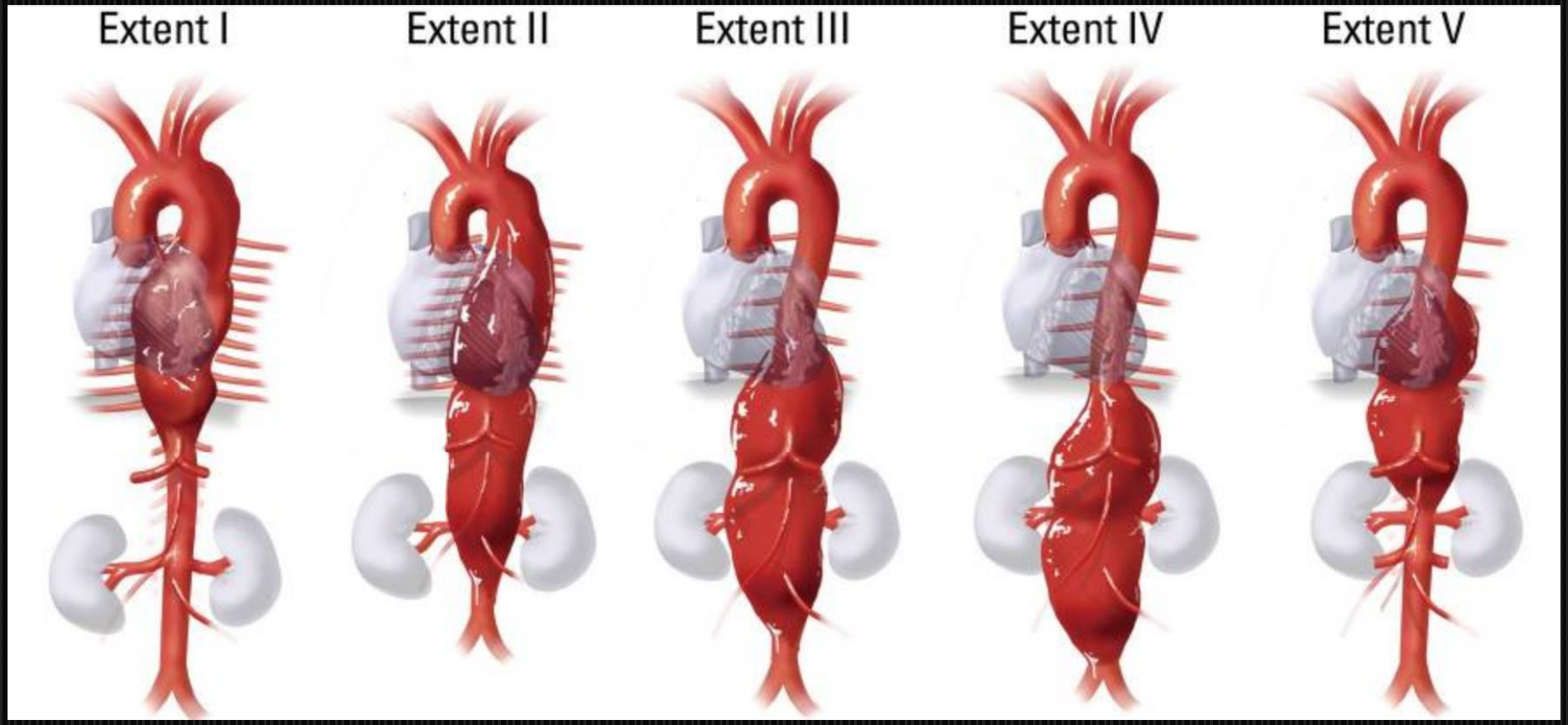

In 1986, Crawford described the first TAAA classification scheme based on the anatomic extent of the aneurysm. Safi modified the scheme by adding Type V.[2]

Discussion: Crawford TAAA Classification, continued

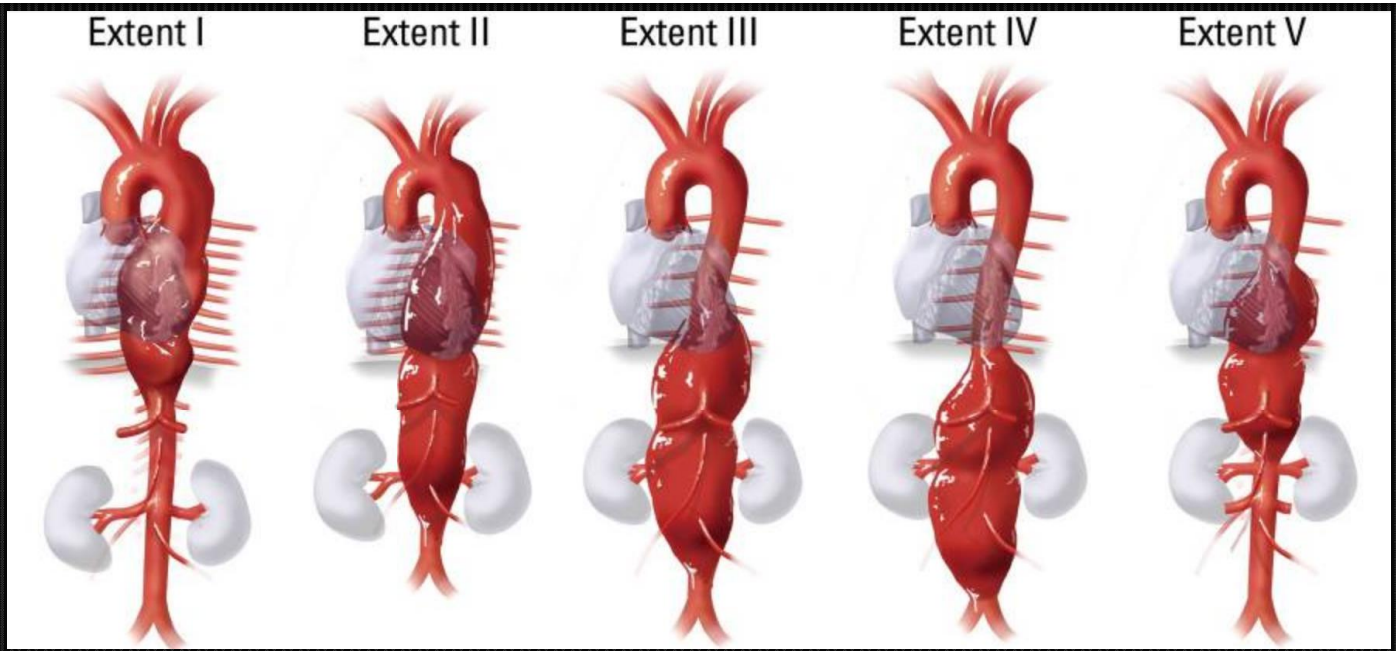

- **Type I:** Most of the descending thoracic aorta from the origin of the L subclavian to the suprarenal abdominal aorta
- **Type II:** Extends from the subclavian to the aortoiliac bifurcation
- **Type III:** Distal thoracic aorta to the aortoiliac bifurcation
- **Type IV:** Abdominal aorta below the diaphragm
- **Type V:** Distal thoracic aorta (includes the celiac and superior mesenteric origins but not the renal arteries)[2]

Take-Home Points

- Rupture risk increases most in AAAs with diameters of 5.5 cm and greater
- **Ultrasound** is the best modality for asymptomatic AAA
- **Ultrasound** is preferred modality for surveillance and screening
- **CT** offers more anatomic precision but is not the most cost-effective option

References

1. Arita, T., Matsunaga, N., Takano, K., Nagaoka, S., Nakamura, H., Katayama, S., ... & Esato, K. (1997). Abdominal aortic aneurysm: rupture associated with the high-attenuating crescent sign. *Radiology*, *204*(3), 765-768.
2. Chaikof, E. L., Dalman, R. L., Eskandari, M. K., Jackson, B. M., Lee, W. A., Mansour, M. A., ... & Oderich, G. S. (2018). The Society for Vascular Surgery practice guidelines on the care of patients with an abdominal aortic aneurysm. *Journal of vascular surgery*, *67*(1), 2-77.
3. Dalman, R.L., Mell, M. Management of asymptomatic abdominal aortic aneurysm. In: UpToDate, Post, TW (Ed), UpToDate. Accessed June 12 2018.
4. Frederick, J. R., & Woo, Y. J. (2012). Thoracoabdominal aortic aneurysm. *Annals of cardiothoracic surgery*, *1*(3), 277.
5. Iino, M., Kuribayashi, S., Imakita, S., Takamiya, M., Matsuo, H., Ookita, Y., ... & Ueda, H. (2002). Sensitivity and specificity of CT in the diagnosis of inflammatory abdominal aortic aneurysms. *Journal of computer assisted tomography*, *26*(6), 1006-1012.
6. Jim, J., and Thompson, R.W. Clinical features and diagnosis of abdominal aortic aneurysm. In: UpToDate, Collins, KA (Ed). UpToDate. Accessed June 15 2018.
7. Kumar, Y., Hooda, K., Li, S., Goyal, P., Gupta, N., & Adeb, M. (2017). Abdominal aortic aneurysm: pictorial review of common appearances and complications. *Annals of translational medicine*, *5*(12).
8. Manssor, E., Abuderman, A., Osman, S., Alenezi, S. B., Almehemeid, S., Babikir, E., ... & Sulieman, A. (2015). Radiation doses in chest, abdomen and pelvis CT procedures. *Radiation protection dosimetry*, *165*(1-4), 194-198.
9. Powell, J. T., & Greenhalgh, R. M. (2003). Small abdominal aortic aneurysms. *New England Journal of Medicine*, *348*(19), 1895-1901.
10. Vu, K. N., Kaitoukov, Y., Morin-Roy, F., Kauffmann, C., Giroux, M. F., Thérasse, É., ... & Tang, A. (2014). Rupture signs on computed tomography, treatment, and outcome of abdominal aortic aneurysms. *Insights into imaging*, *5*(3), 281-293.
11. Acsearch.acr.org. (2018). *Appropriateness Criteria*. [online] Available at: https://acsearch.acr.org/list [Accessed 24 Jun. 2018].