RADY 401 Case Presentation

Keith Anderson, MS4

June 2018

Ed. John Lilly, MD

UNC SCHOOL OF MEDICINE Radiology

Focused patient history and workup

- Previously healthy 11 year old female (premenarchal)
- Presented to outside facility after 3 weeks of worsening RLQ abdominal pain, diagnosed with constipation via KUB
- Pain persisted after stool softeners
- Associated with low grade fevers, N/V, decreased appetite, weight loss
- Elevated WBC on initial labs, pt otherwise stable

Differential?

Abdominal Pain Differential Diagnosis (Non Child-Bearing Age Female)

- Constipation
- Appendicitis
- Ovarian Torsion
- Ruptured Ovarian Cyst
- UTI
- Nephrolithiasis
- Gastroenteritis
- DKA
- Cholecystitis
- Malignancy/Mass

Imaging studies?

List of imaging studies

- CT Abdomen & Pelvis
- Abdominal Ultrasound
- MRI Abdomen

American College of Radiology
ACR Appropriateness Criteria®
Acute Nonlocalized Abdominal Pain

Variant 1: Acute nonlocalized abdominal pain and fever. No recent surgery. Initial imaging.

Procedure	Appropriateness Category	Relative Radiation Level
CT abdomen and pelvis with IV contrast	Usually Appropriate	☢☢☢☢
MRI abdomen and pelvis without and with IV contrast	May Be Appropriate	O
US abdomen	May Be Appropriate	O
CT abdomen and pelvis without IV contrast	May Be Appropriate	☢☢☢☢
MRI abdomen and pelvis without IV contrast	May Be Appropriate	O
CT abdomen and pelvis without and with IV contrast	May Be Appropriate	☢☢☢☢
X-ray abdomen	May Be Appropriate	☢☢
FDG-PET/CT skull base to mid-thigh	Usually Not Appropriate	☢☢☢☢
In-111 WBC scan abdomen and pelvis	Usually Not Appropriate	☢☢☢☢
Tc-99m cholescintigraphy	Usually Not Appropriate	☢☢
Tc-99m WBC scan abdomen and pelvis	Usually Not Appropriate	☢☢☢☢
X-ray contrast enema	Usually Not Appropriate	☢☢☢
X-ray upper GI series with small bowel follow-through	Usually Not Appropriate	☢☢☢

Abdominopelvic CT

Imaging demonstrates a large R pelvic mass. The structure is heterogeneous with multiple densities. Pelvic free fluid can also be appreciated.

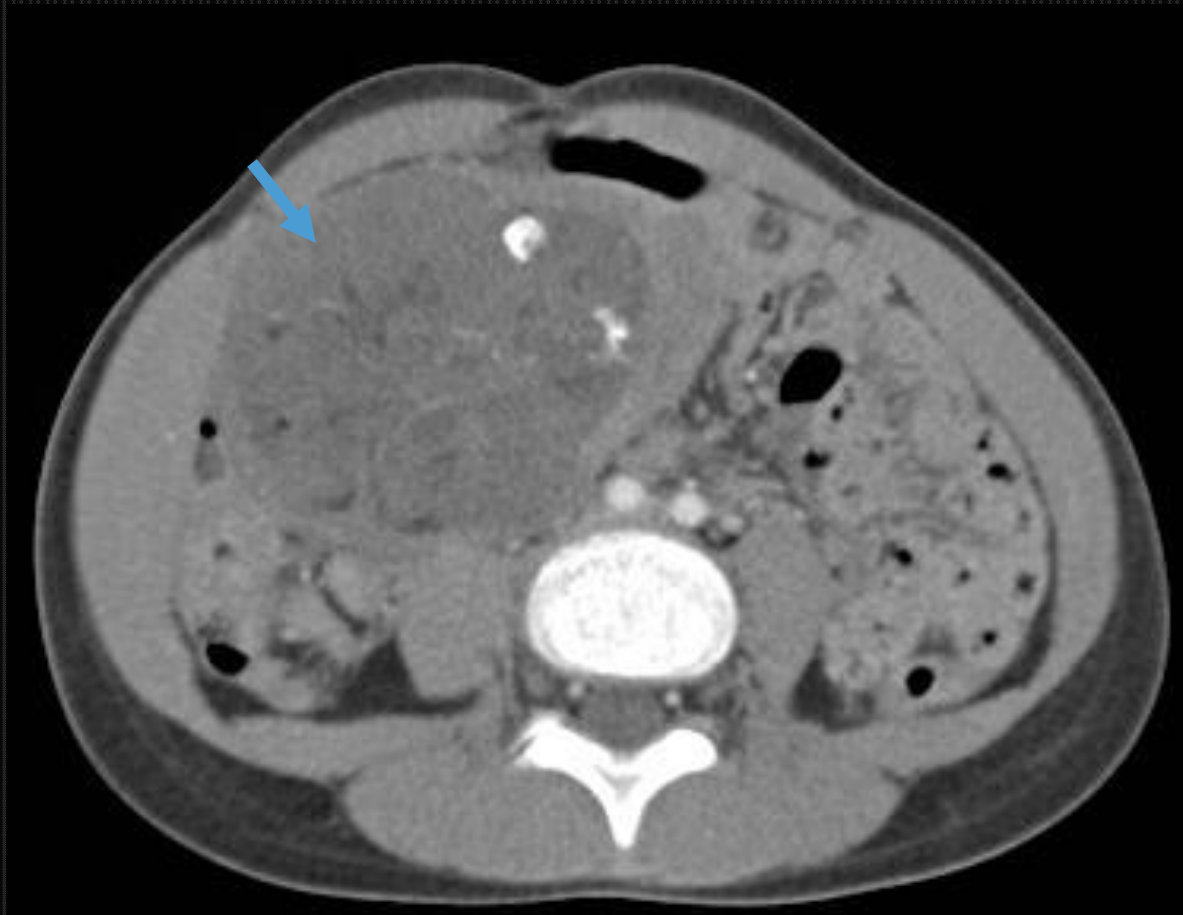

Imaging: Ultrasound 1 with Doppler (R Adnexa)

Poor vascular flow to ovary and mass

Likely diagnosis?

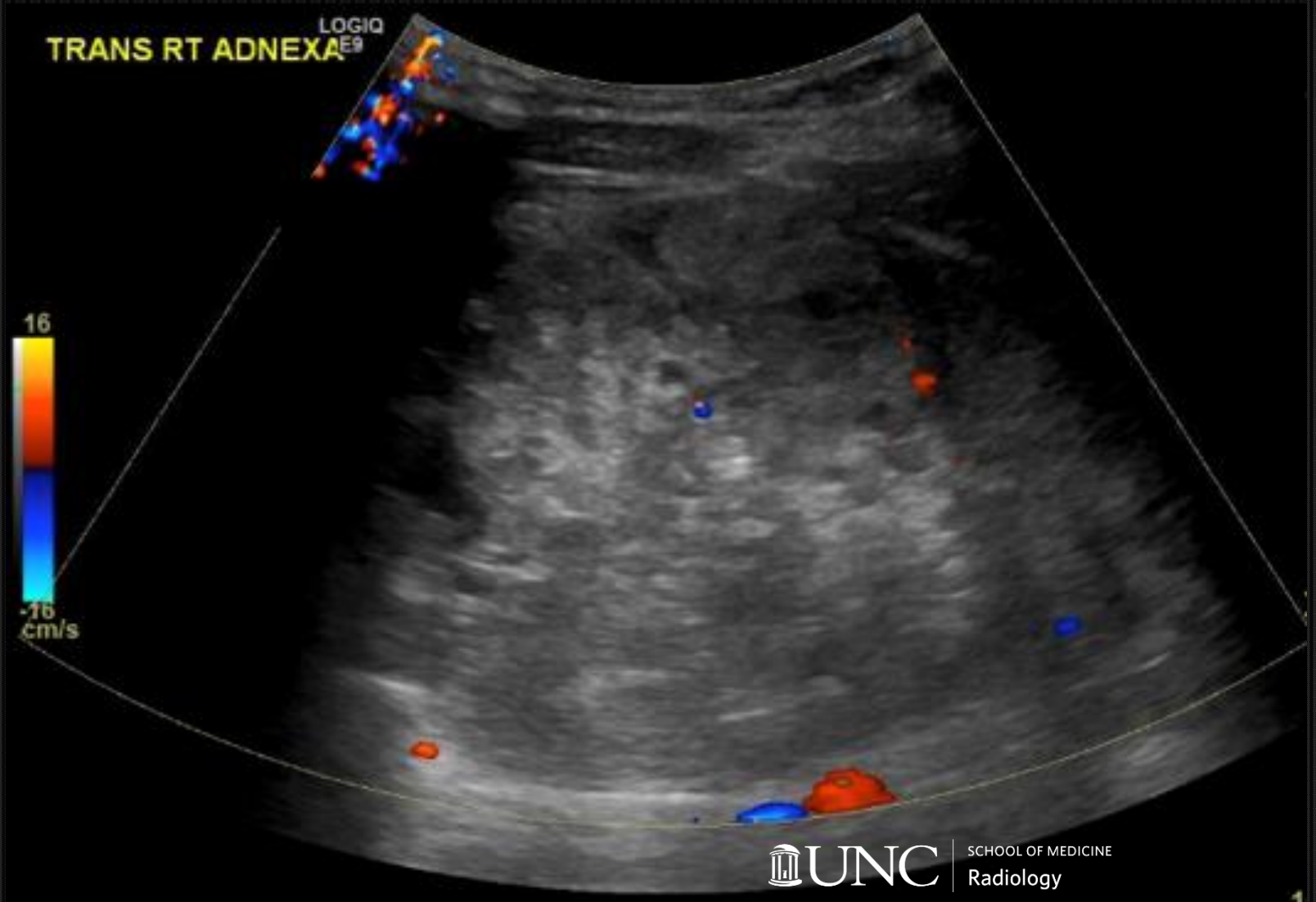

Treatment & Hospital Course

- The patient was taken to the OR emergently given the high clinical suspicion for ***OVARIAN TORSION*** and concerning US findings
- Diagnostic laparoscopy revealed a L ovarian torsion and patient underwent detorsion without complication
- She improved clinically and was discharged POD2

Imaging: Ultrasound 1 with Doppler (R Adnexa)

Improved vascular ovarian flow s/p surgical repair

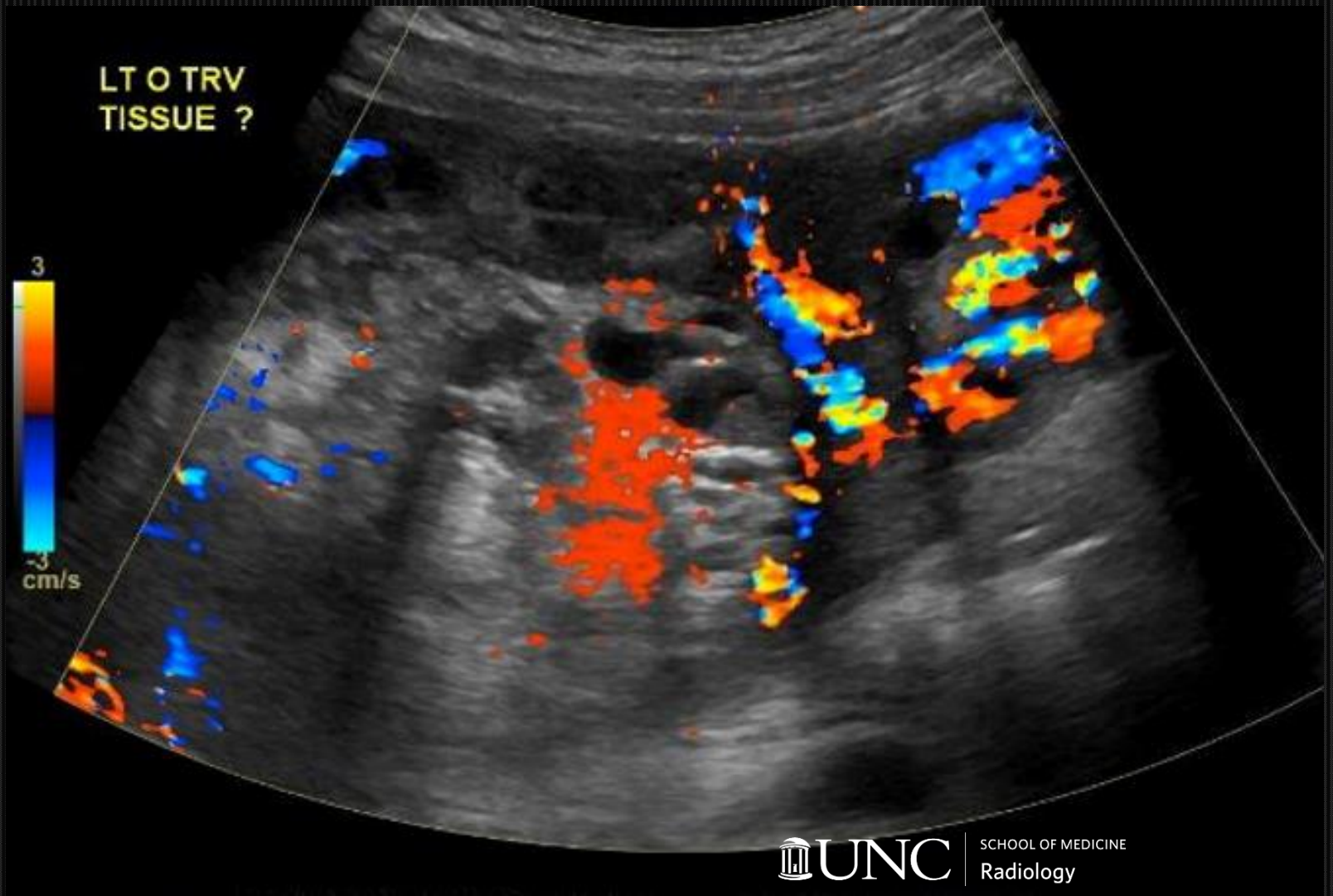

Discussion: Ovarian Torsion Overview[1,2,7]

- Patient: Female, any age affected although more common in reproductive age
- Pathogenesis: The ovary typically rotates around both the infundibulopelvic ligament and the utero-ovarian ligament → compression of ovarian vessels (arteries, veins, lymphatics)[1]
- Risk factors: Ovarian cysts or neoplasms (>5cm), tubal ligation, increased fallopian tube mobility
- Treatment: Surgical detorsion
- Complications: Organ necrosis, hemorrhage, peritonitis, adhesions

Discussion: Ovarian Torsion Pathogenesis

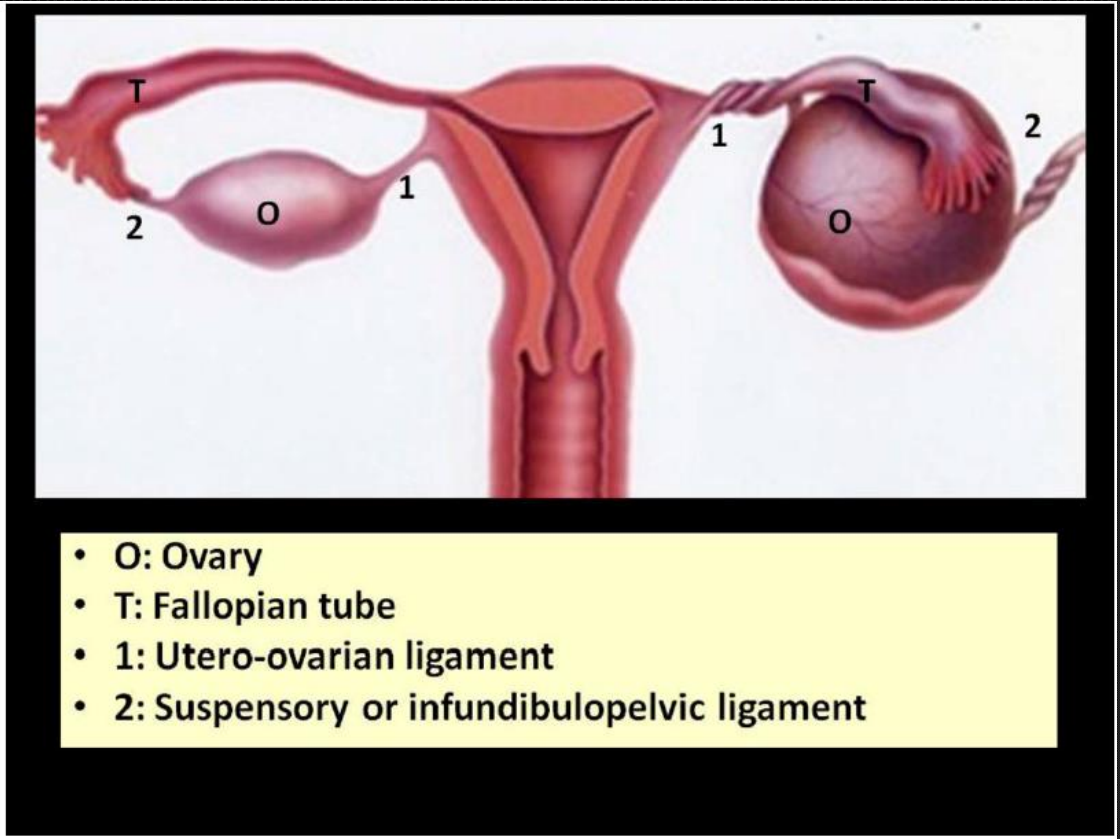

Fig. 1: Schematic diagram of the most common type of adnexal torsion, involving the ovary and fallopian tube.
References: Modified from ukgynaecolgist.com

Discussion: Ovarian Torsion Evaluation[6]

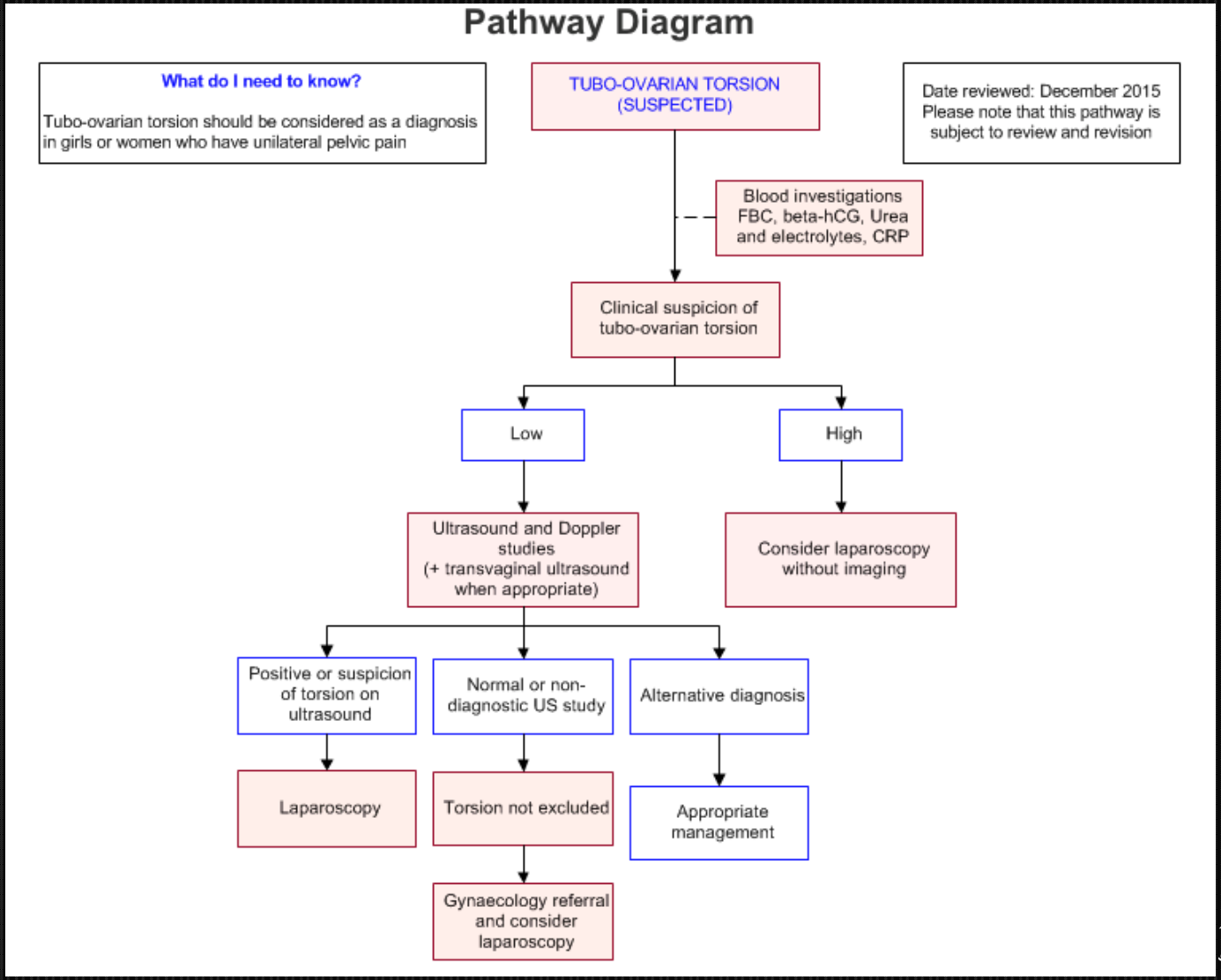

UNC SCHOOL OF MEDICINE Radiology

Discussion: Ovarian Torsion (cont.)[2]

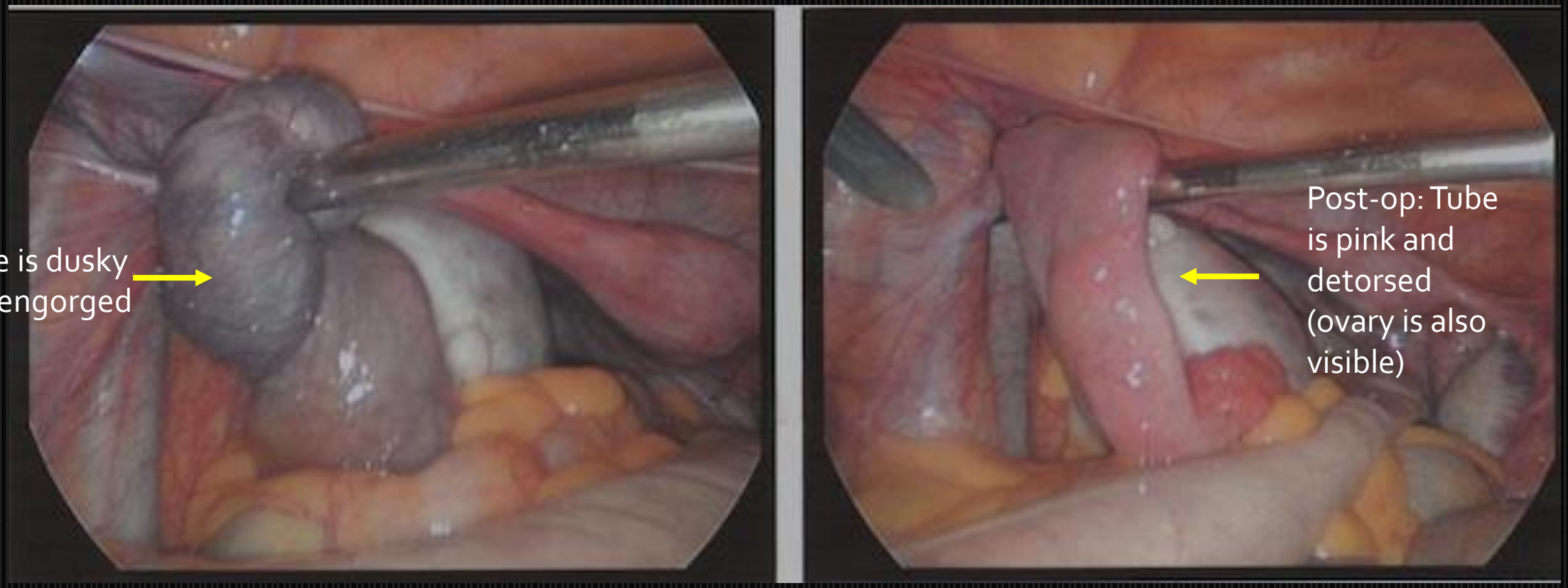

Discussion: Imaging for Ovarian Torsion

American College of Radiology
ACR Appropriateness Criteria®
Acute Nonlocalized Abdominal Pain

Variant 1: **Acute nonlocalized abdominal pain and fever. No recent surgery. Initial imaging.**

Procedure	Appropriateness Category	Relative Radiation Level
CT abdomen and pelvis with IV contrast	Usually Appropriate	☢☢☢☢
MRI abdomen and pelvis without and with IV contrast	May Be Appropriate	O
US abdomen	May Be Appropriate	O
CT abdomen and pelvis without IV contrast	May Be Appropriate	☢☢☢☢
MRI abdomen and pelvis without IV contrast	May Be Appropriate	O
CT abdomen and pelvis without and with IV contrast	May Be Appropriate	☢☢☢☢
X-ray abdomen	May Be Appropriate	☢☢
FDG-PET/CT skull base to mid-thigh	Usually Not Appropriate	☢☢☢☢
In-111 WBC scan abdomen and pelvis	Usually Not Appropriate	☢☢☢☢
Tc-99m cholescintigraphy	Usually Not Appropriate	☢☢
Tc-99m WBC scan abdomen and pelvis	Usually Not Appropriate	☢☢☢☢
X-ray contrast enema	Usually Not Appropriate	☢☢☢
X-ray upper GI series with small bowel follow-through	Usually Not Appropriate	☢☢☢

Discussion: Imaging for Ovarian Torsion

Abdominal CT

- Sens = 90-100%, Spec = 85-90% [3]
- Radiation: 8 mSv (FDA 2017)
- Cost = $620-$5,157+[4]
- Can help rule out appendicitis
- Good at visualizing pelvic anatomy and comparing contralateral ovary
- Findings: twisted ovarian pedicle, pelvic free fluid, abnormal mass[5]

Transabdominal US

- Sens = 80%, Spec = 85-95%[3]
- No radiation
- Cost = $436-$1404[4]
- Live images with available Doppler flow
- Findings: Enlarged hyper- or hypoechoic ovary, peripherally displaced follicles, pelvic free fluid, absent vascular flow[5]

Imaging: MRI Abdomen

-Clearer resolution of heterogeneous pelvic mass of multiple intensities
-Shifted toward L abdomen when compared with initial CT imaging

T1-Weighted Image, Axial Plane

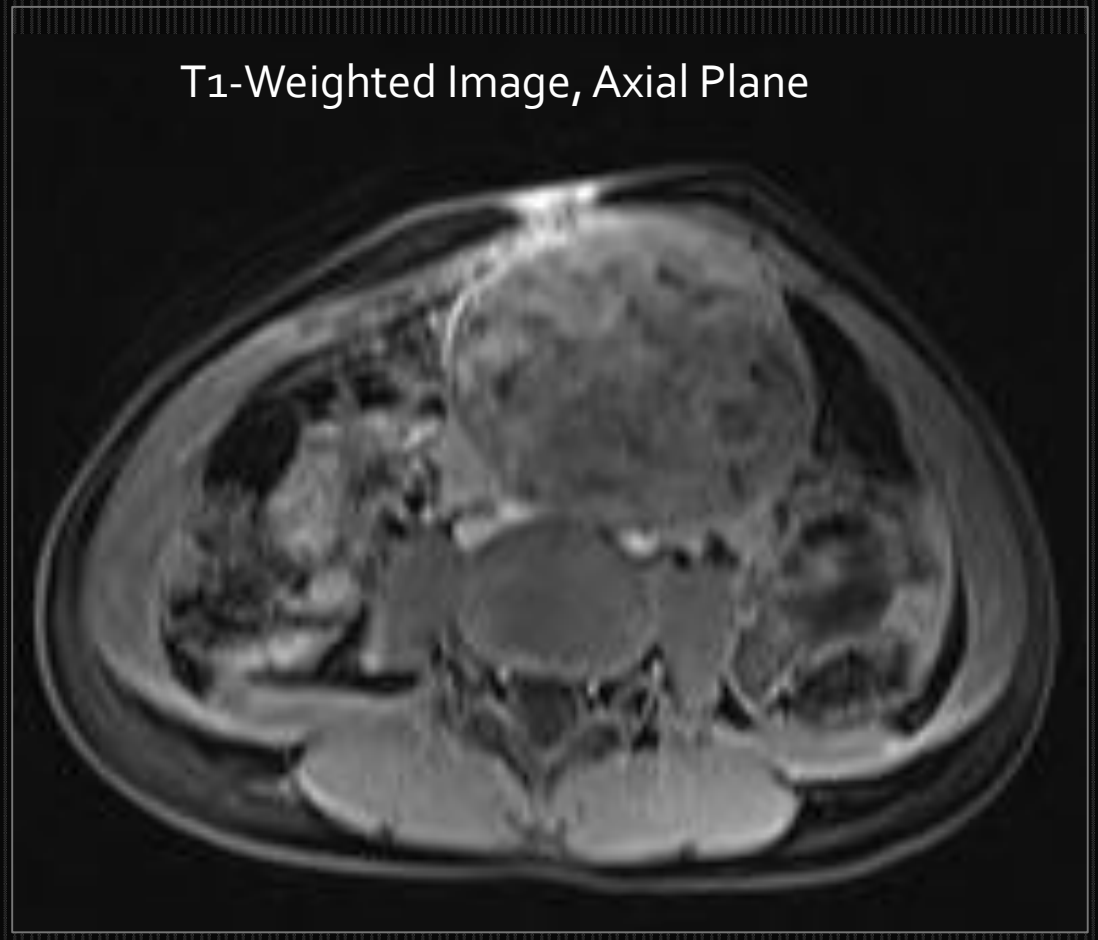

T2-Weighted Image Coronal Plane

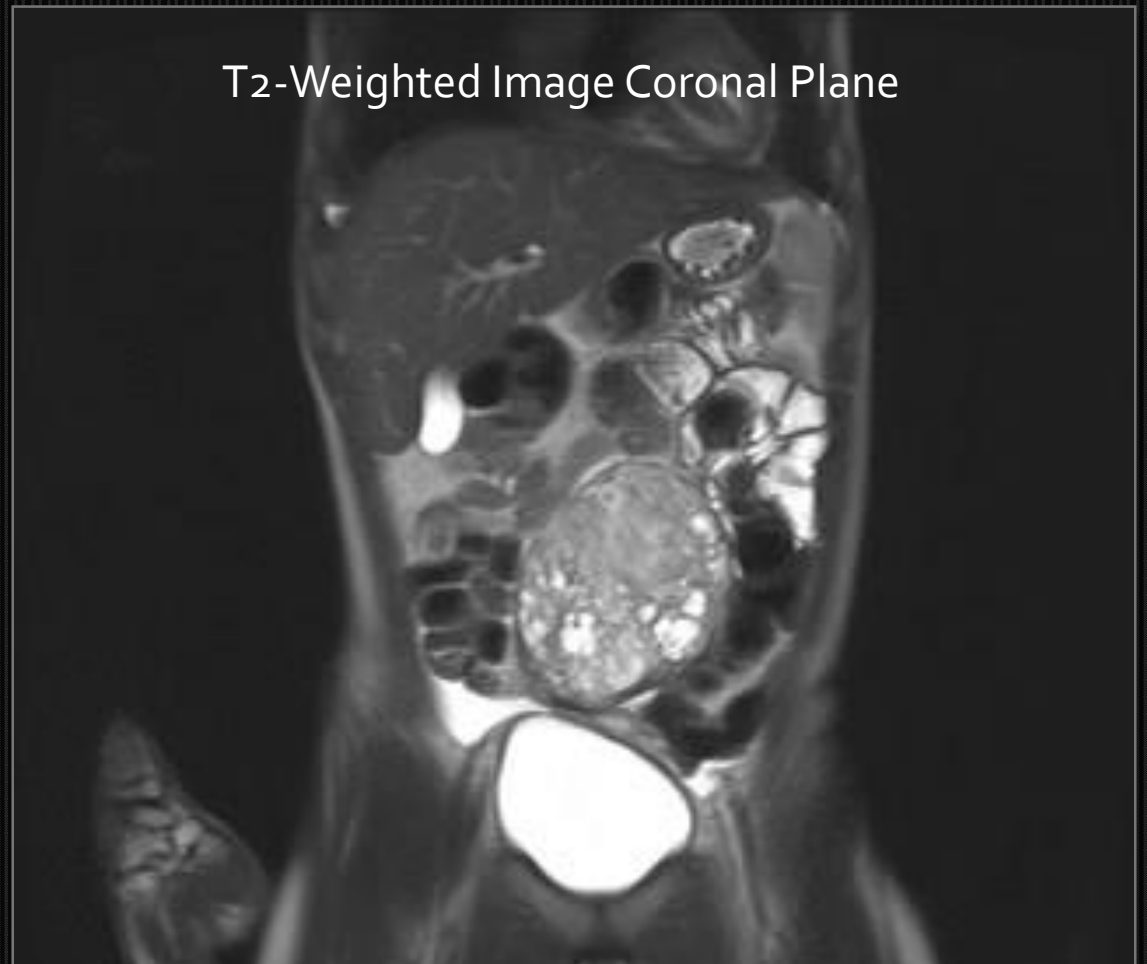

Hospital Course & Treatment (Part 2)

- Labs concerning for germ cell tumor: bHCG nl, ↑AFP, ↑LDH
- Oopherectomy performed and lesion resected by surgery and sent for path, revealing Grade I immature teratoma (90%) and yolk sac tumor (10%)
- Chest CT for staging, Stage 1A
- Patient started on scheduled chemotherapy

Discussion: Immature Teratomas[7]

- Most common malignant ovarian germ cell tumor (~35.6%)
- Pt: Females, typically during first 2 decades of life
- Presentation: Abdominal mass, ovarian torsion, rupture, precocious puberty, vaginal bleeding
- Histopath: all 3 germ layers, immature embryonal and mature adult tissue
- Treatment: Resection + chemotherapy

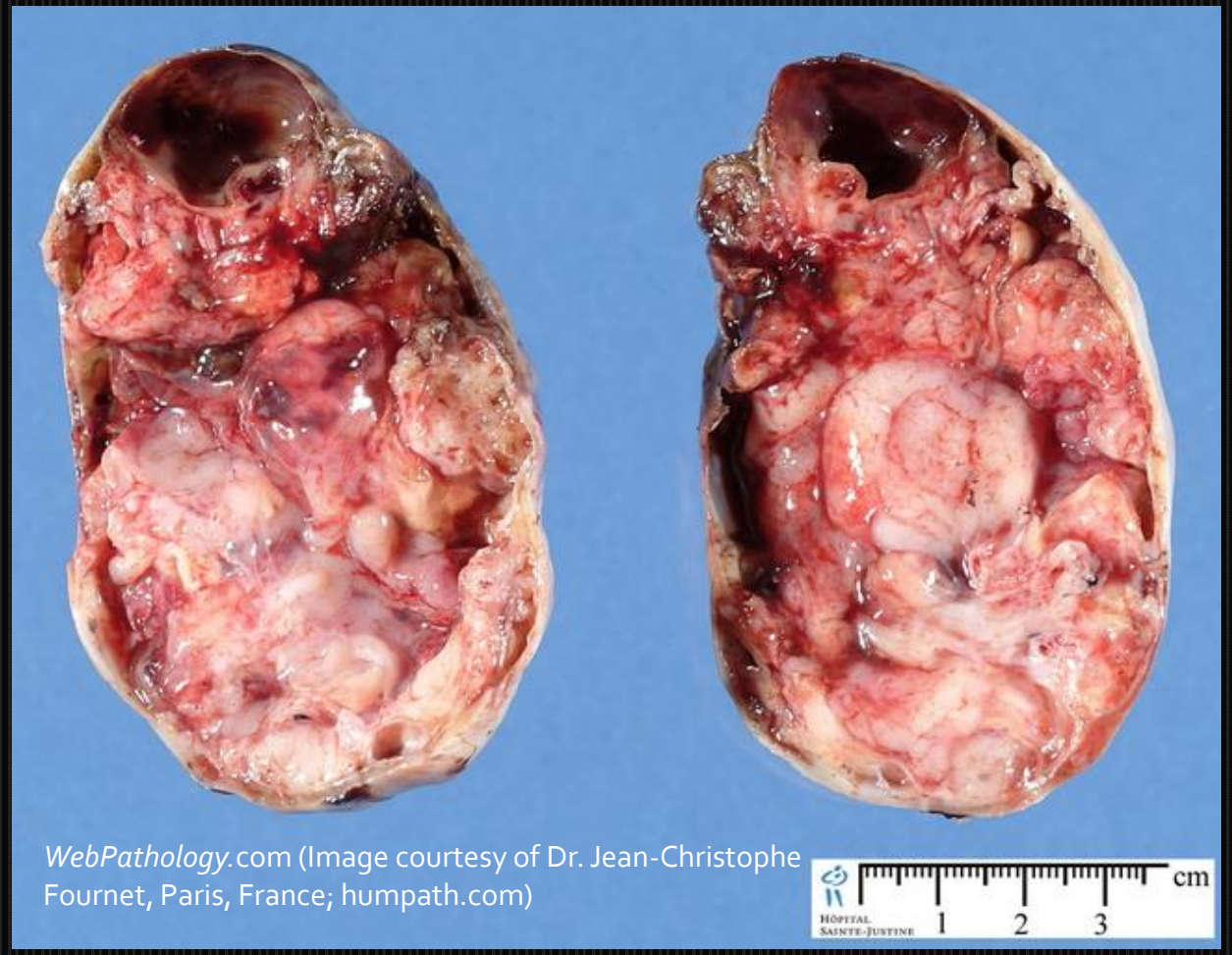

WebPathology.com (Image courtesy of Dr. Jean-Christophe Fournet, Paris, France; humpath.com)

Wrap-Up

- Ovarian torsion is a gynecologic emergency that can accurately be diagnosed via ultrasound (but be suspicious for other abdominal pain!)
- Surgery is the curative treatment
- Further workup of concerning masses on imaging should be pursued once patient is stable
- Immature teratomas are <u>malignant</u> (ie "bad")!

References

1. Laufer, Marc. "Ovarian and Fallopian Tube Torsion." *UpToDate*, sso.uptodate.com/contents/ovarian-and-fallopian-tube-torsion?search=Ovarian%2Btorsion&source=search_result&selectedTitle=1~70&usage_type=default&display_rank=1#H849034.
2. Yancey, Lynne. "Ovarian Torsion." Edited by Luan Lawson, *CDEM Curriculum*, 12 Dec. 2016, cdemcurriculum.com/ovarian-torsion/.
3. Swenson, DW, et al. "Ovarian torsion: Case-control study comparing the sensitivity and specificity of ultrasonography and computed tomography for diagnosis in the emergency department." *European Journal of Radiology (2014)* April 83(4):733-8
4. "Find Your Fair Price." Healthcare Bluebook, CAREOperative, www.healthcarebluebook.com/page_SearchResults.aspx?CatID=42.
5. Dixon, Andrew. "Ovarian Torsion." *Radiopaedia*. radiopaedia.org/articles/ovarian-torsion.
6. "Tubo-Ovarian Torsion (Suspected)." Diagnostic Imaging Pathways, Department of Health Western Australia, 16 Aug. 2017, www.imagingpathways.health.wa.gov.au/index.php?id=411&tab=blood#pathway
7. Gershenson, David. "Ovarian Germ Cell Tumors: Pathology, Clinical Manifestations, and Diagnosis." UpToDate, 30 Nov. 2017, www.uptodate.com/contents/ovarian-germ-cell-tumors-pathology-clinical-manifestations-and-diagnosis?topicRef=3197&source=see_link#H19.
8. Acsearch.acr.org. (2018). *Appropriateness Criteria*. [online] Available at: https://acsearch.acr.org/list [Accessed 24 Jun. 2018].