RADY 401 Case Presentation

Nate Koutlas MS4
April 2018

UNC SCHOOL OF MEDICINE
Radiology

Focused patient history and workup

- 22 year old female
- 4 week history of right hip and thigh pain
- No known injury
- Patient is an avid runner and her pain is worse with weight bearing activities
- Normal range of motion of the right hip with intact strength, sensation, and reflexes.
- Workup started with pelvis and right hip 2 view radiographs

List of imaging studies

- AP radiograph of the pelvis
- AP radiograph of the right hip
- Frog leg lateral radiograph of the right hip
- Right hip and pelvis MRI without contrast

AP pelvis radiograph

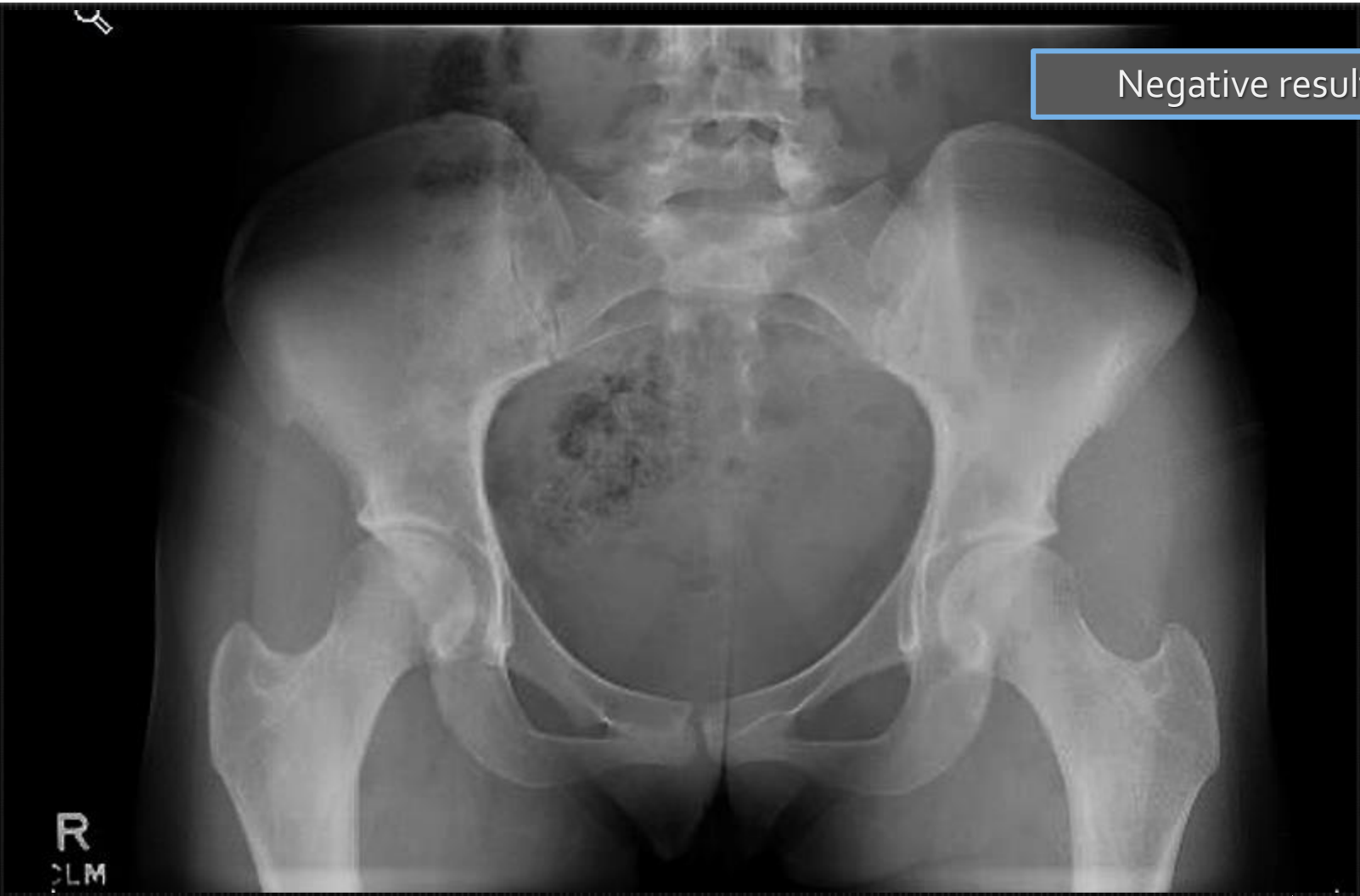

Negative result

AP and frog leg lateral radiographs

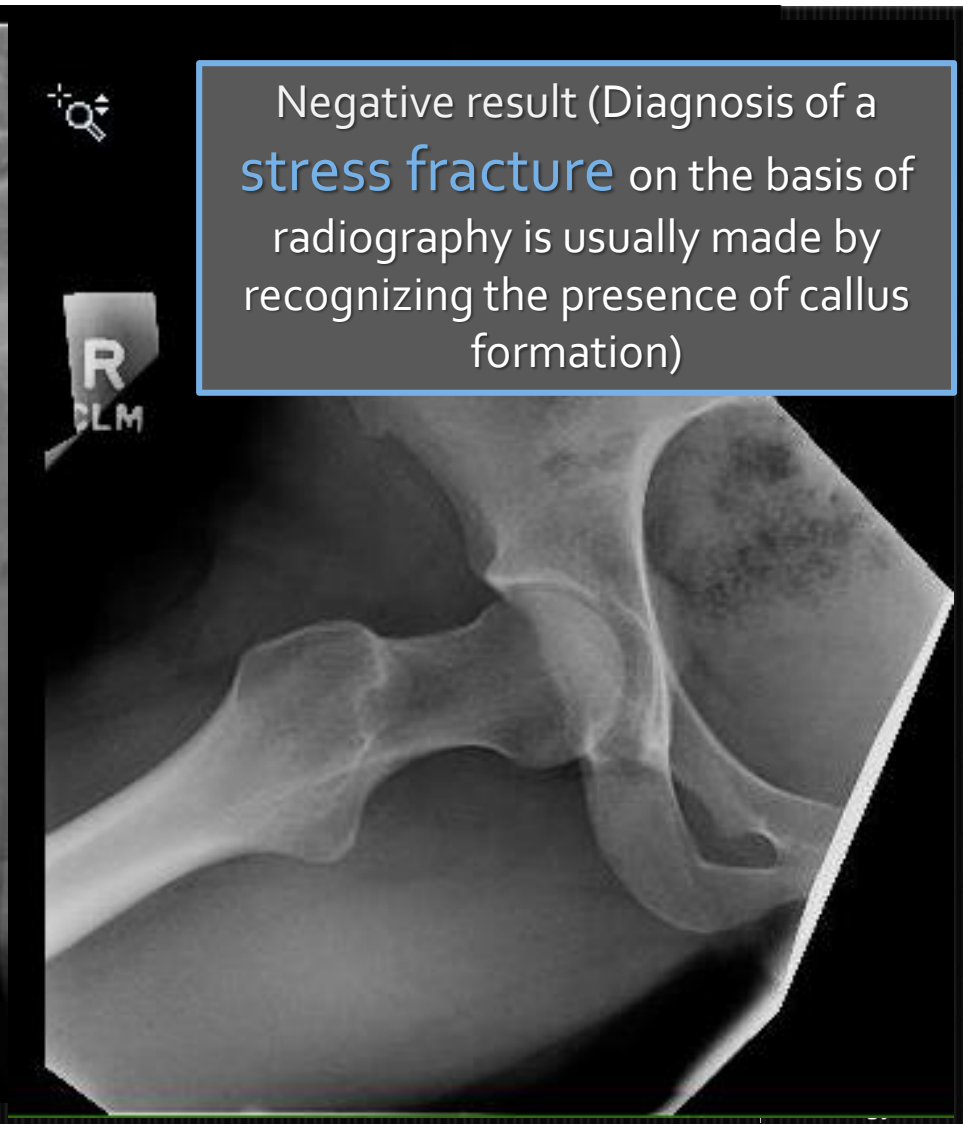

Negative result (Diagnosis of a stress fracture on the basis of radiography is usually made by recognizing the presence of callus formation)

MRI pelvis without contrast- T2 coronal

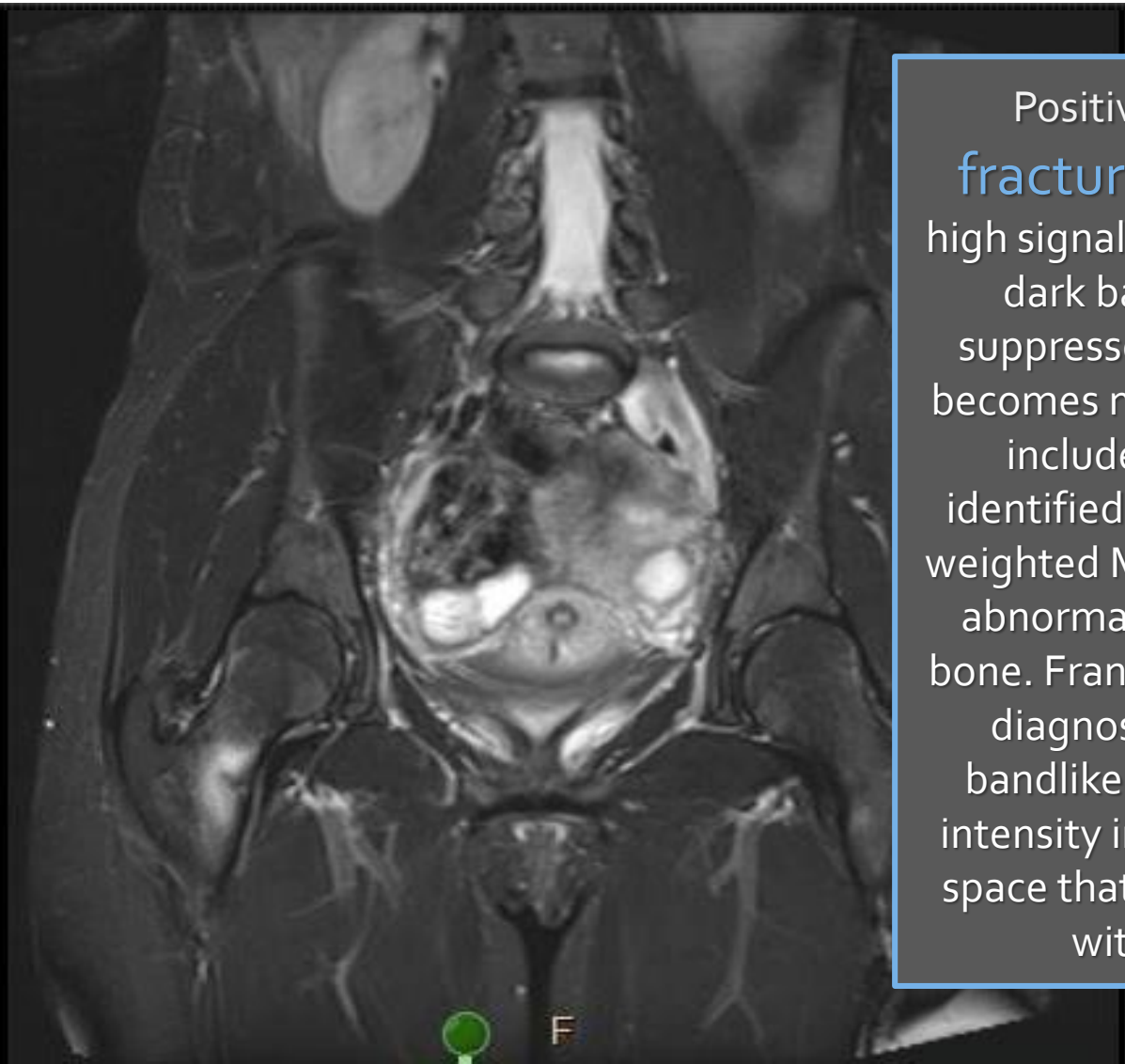

Positive result stress fracture: Edema results in high signal intensity against the dark background of the suppressed fat. As the injury becomes more severe, findings include marrow edema identified on both T1- and T2-weighted MR images and signal abnormalities in the cortical bone. Frank stress fractures are diagnosed by identifying bandlike areas of low signal intensity in the intramedullary space that may be continuous with the cortex[6]

MRI Rt hip without contrast- T2 coronal

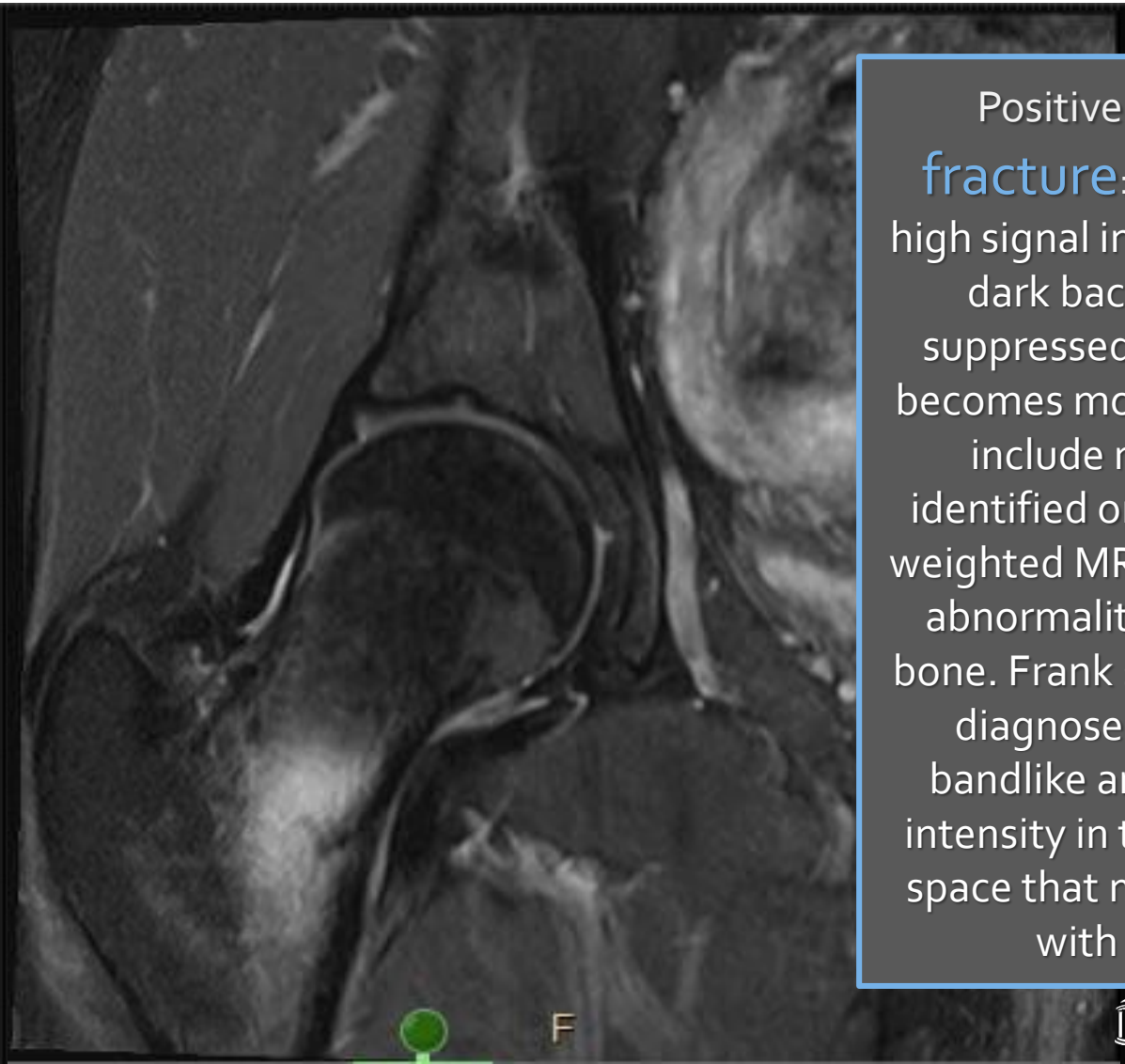

Positive result stress fracture: Edema results in high signal intensity against the dark background of the suppressed fat. As the injury becomes more severe, findings include marrow edema identified on both T1- and T2-weighted MR images and signal abnormalities in the cortical bone. Frank stress fractures are diagnosed by identifying bandlike areas of low signal intensity in the intramedullary space that may be continuous with the cortex[6]

MRI Rt hip without contrast- T2 transverse

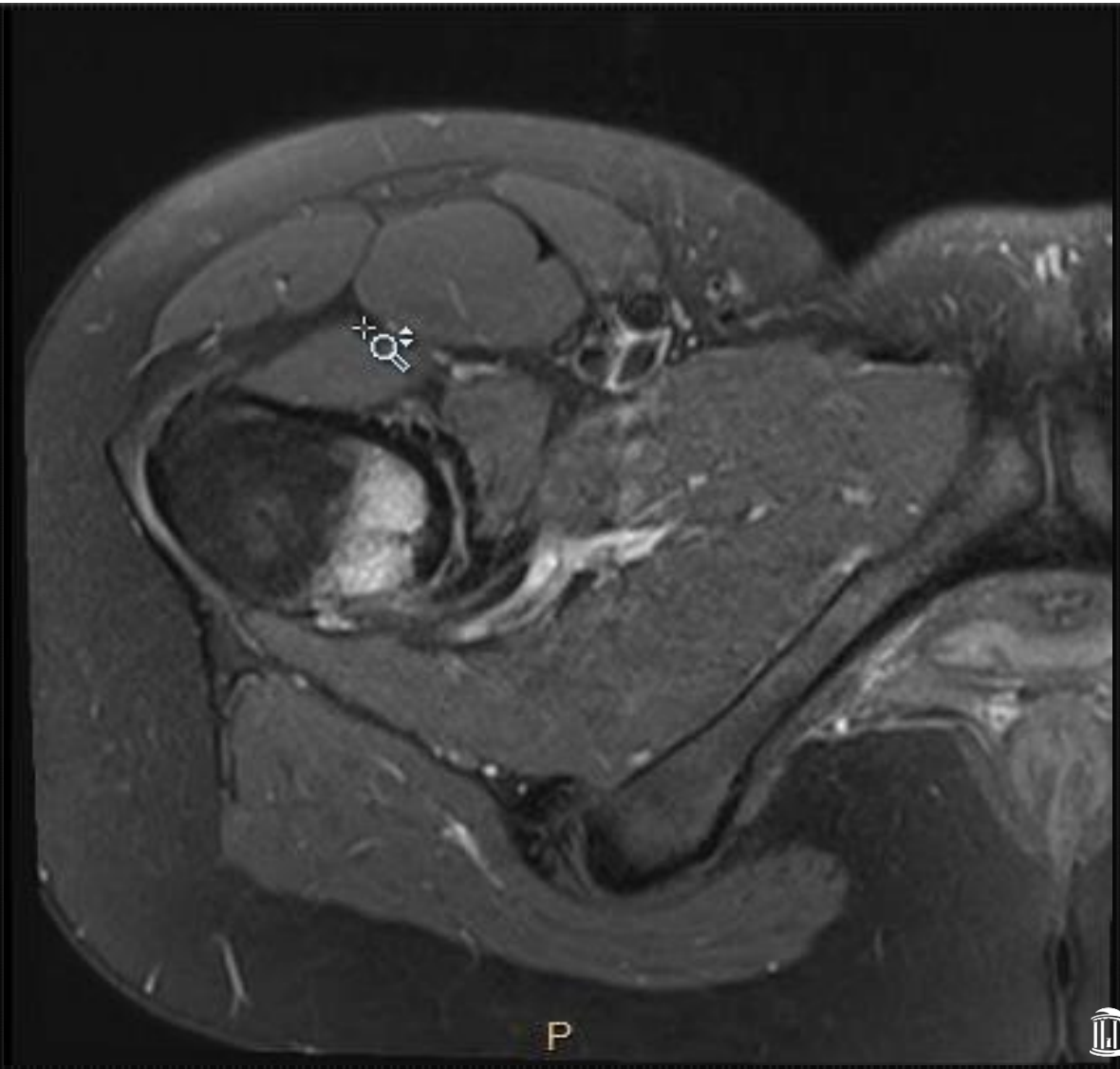

MRI Rt hip without contrast- T2 sagittal

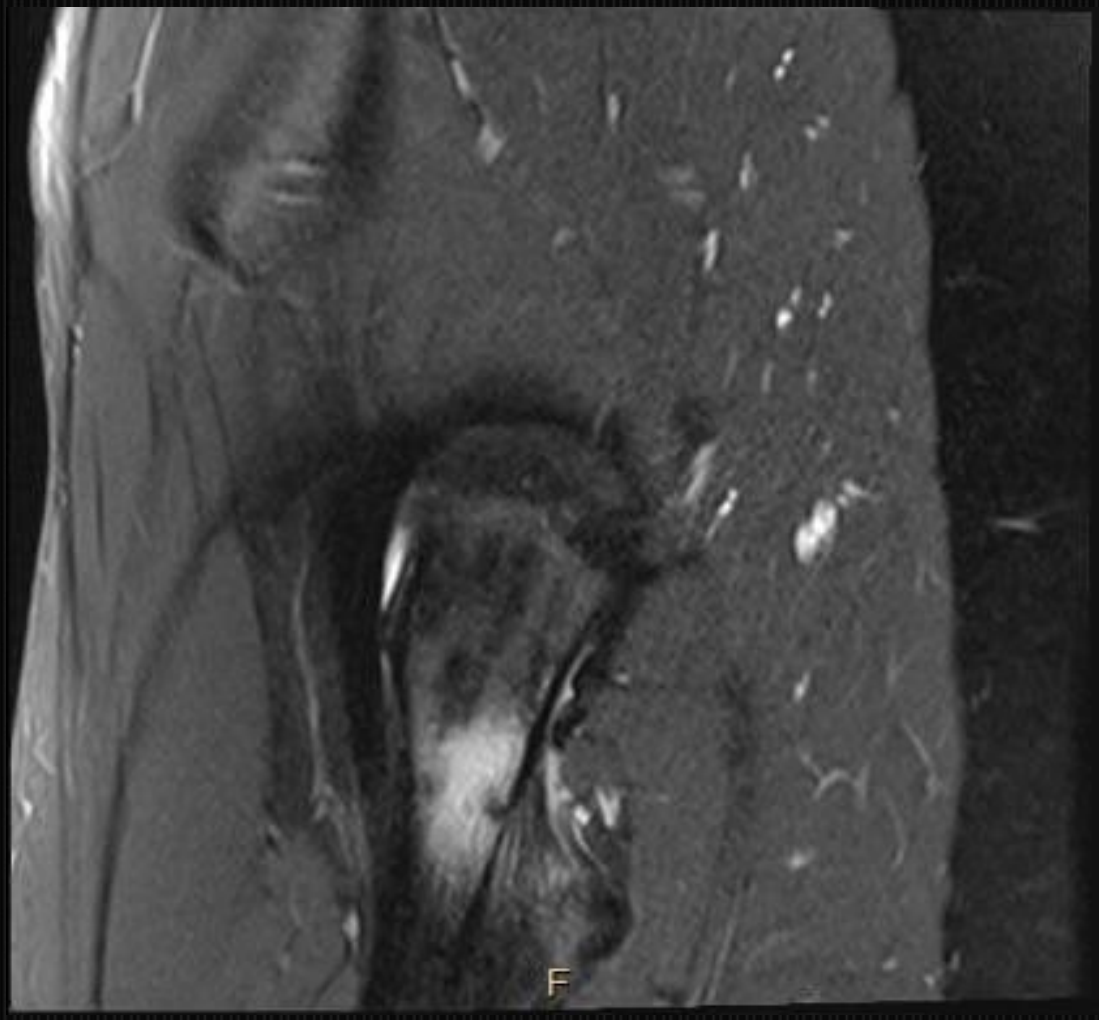

MRI Rt hip without contrast- T1 coronal

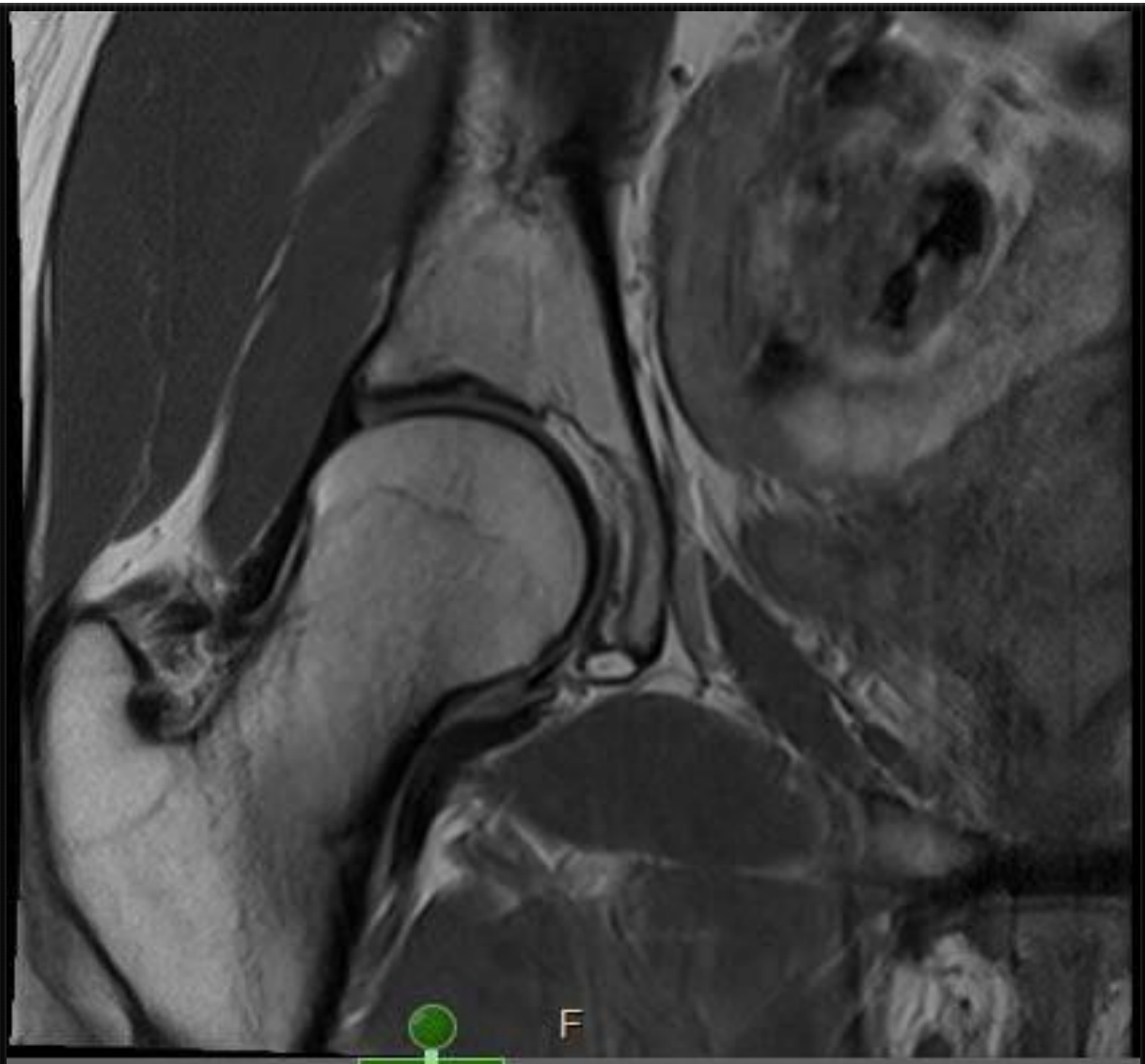

UNC SCHOOL OF MEDICINE Radiology

Typical patient treatment or outcome[1]

- Stress fracture Rx: Strict non-weight bearing of leg with use of crutches for at least 2 weeks
- Gradually resume weight bearing on affected leg as tolerated over the next month
- Obtain weekly follow-up radiographs to ensure proper bone healing and look for complications

Femoral stress fracture work up - radiography

- Initial test of choice in patients with suitable clinical history
- Usually consists of AP pelvis and 2 views of affected hip (ex. AP and frog leg lateral)
- Pros
  - Cost - $38 – $600+[2]
  - Radiation dose: 0.83 mSv[3]
  - Short exam time
- Cons
  - Limited sensitivity (12% - 56%) and specificity (88% - 96%)[4]
  - May take weeks of symptoms before radiographic changes are apparent

Classic radiographic findings[1]

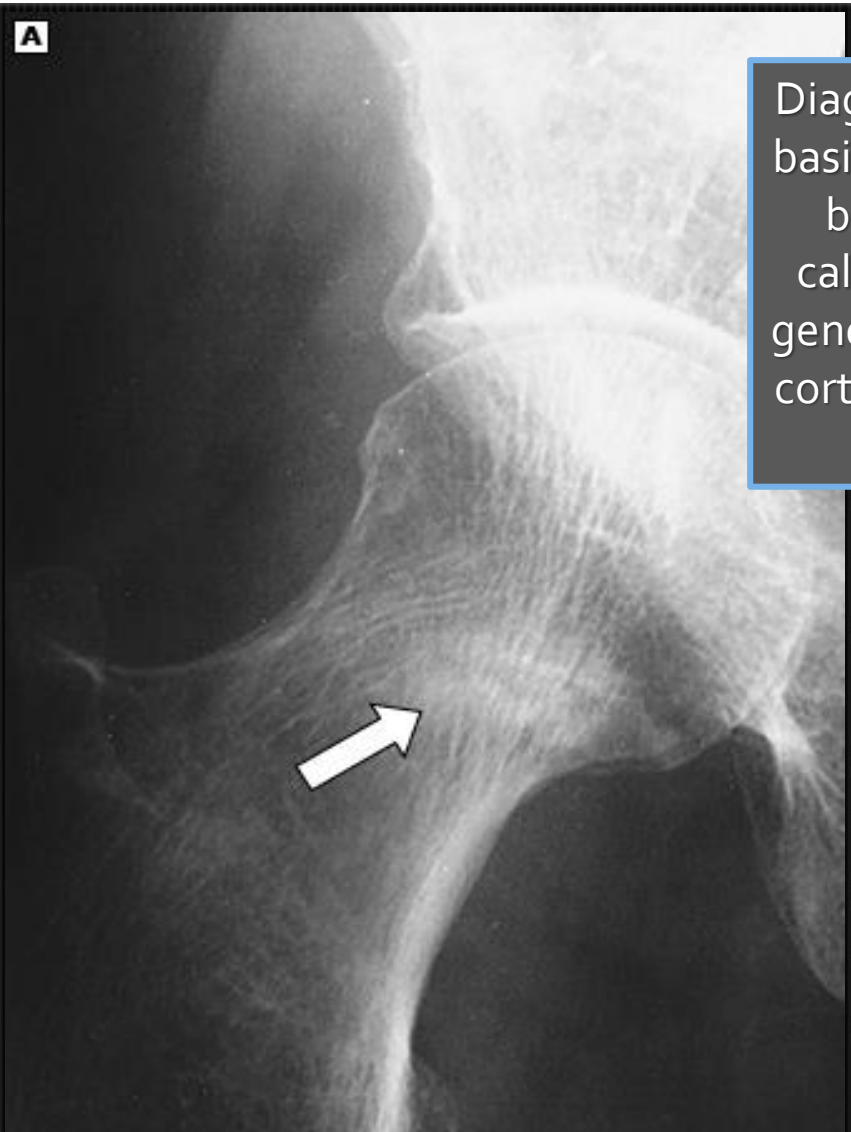

Diagnosis of a stress fracture on the basis of radiography is usually made by recognizing the presence of callus formation. Reactive bone is generally confined to a small area of cortex and usually involves only one of the cortical surfaces[6]

Femoral stress fracture work up - MRI

- Used when initial radiography is negative and a high index of suspicion for stress fracture remains
- Pros
  - More sensitive (68% - 99%) and specific (4% - 97%)[4]
  - No radiation exposure
- Cons
  - Expensive ($634 - $2,935)[5]
  - Long exam time

Classic MRI findings[6]

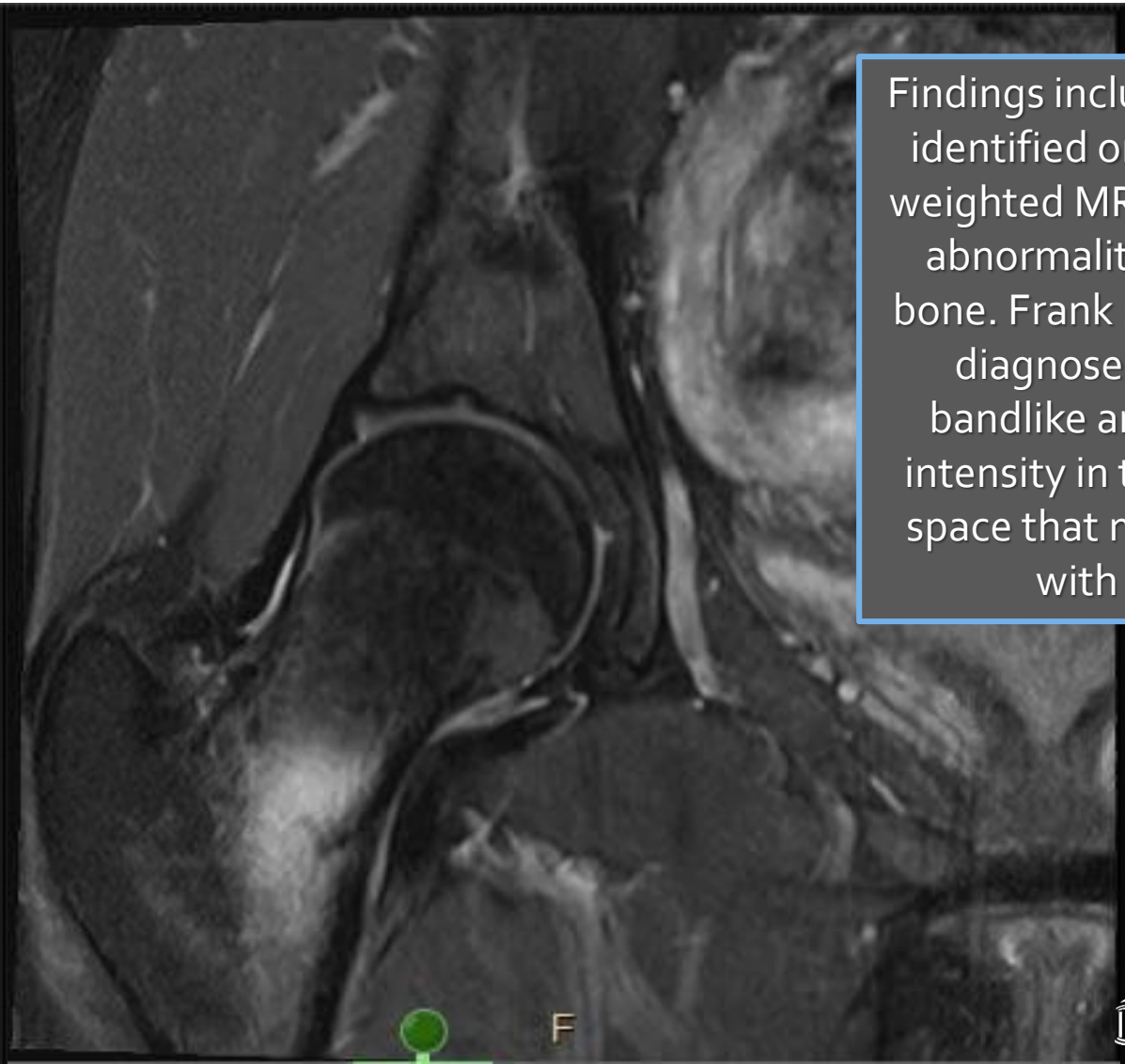

Findings include marrow edema identified on both T1- and T2-weighted MR images and signal abnormalities in the cortical bone. Frank stress fractures are diagnosed by identifying bandlike areas of low signal intensity in the intramedullary space that may be continuous with the cortex[6]

WrapUp

- First line imaging modality for suspected femoral stress fracture is a radiograph
- Must get at least 2 views and ideally image the other hip for comparison
- MRI used in cases with high index of suspicion after a normal radiograph

References

1. Jackson, J. Femoral stress fractures in adults. UpToDate, Waltham, MA 2018. Retrieved from www.uptodate.com.
2. Healthcare Bluebook. (n.d.). Retrieved April 19, 2018, from https://www.healthcarebluebook.com/page_ProcedureDetails.aspx?cftId=152&g=Hip X-Ray
3. Wall BF, Hart D. Revised radiation doses for typical x-ray examinations. The British Journal of Radiology 70:437-439; 1997.
4. Wright, A. A., Hegedus, E. J., Lenchik, L., Kuhn, K. J., Santiago, L., & Smoliga, J. M. (2015). Diagnostic Accuracy of Various Imaging Modalities for Suspected Lower Extremity Stress Fractures. *The American Journal of Sports Medicine*, *44*(1), 255-263. doi:10.1177/0363546515574066
5. Healthcare Bluebook. (n.d.). Retrieved April 19, 2018, from https://www.healthcarebluebook.com/page_ProcedureDetails.aspx?cftId=155&g=Hip MRI (no contrast)
6. Mo Ahn and El-Khoury. *Musculoskeletal Imaging.* Chapter 40, 590-601.e13.